

# Clavicle Fractures

*Gudrun Mirick Mueller, MD*

*Orthopaedic Traumatologist*

*Hennepin Healthcare, Minneapolis MN*

*Assistant Professor, University of Minnesota*

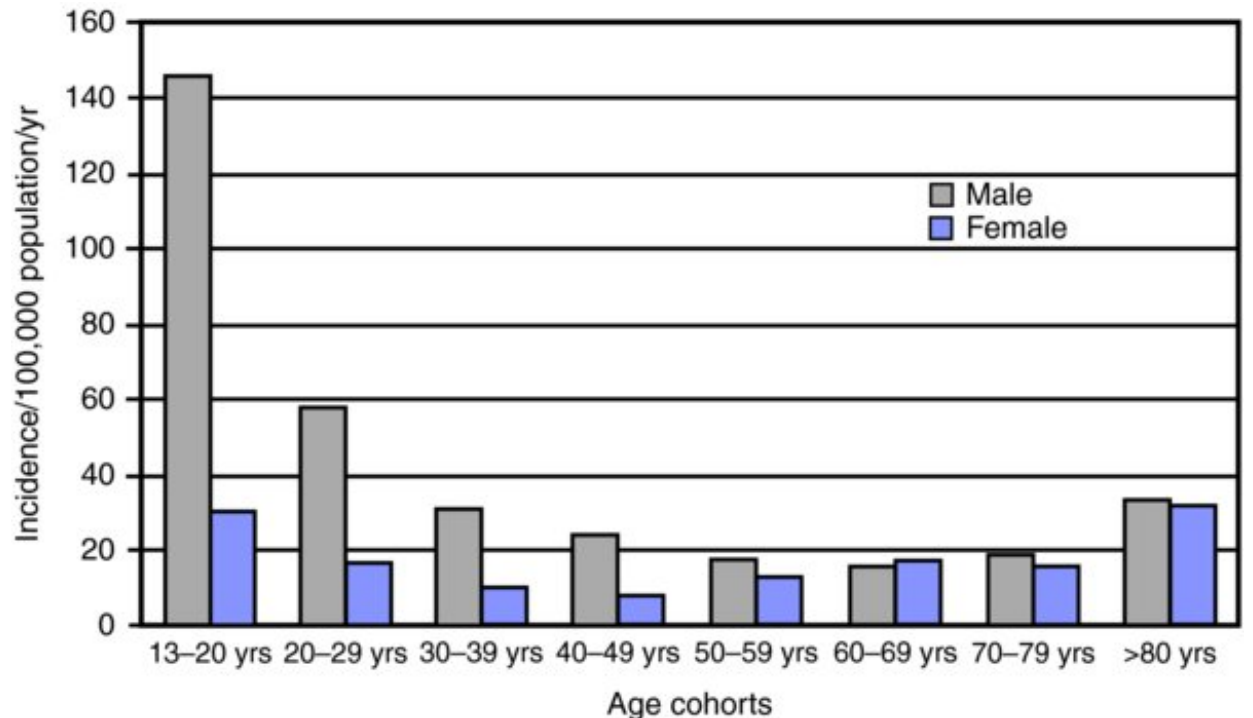


# Objectives

- Understand the deforming forces affecting clavicle fractures
- Discuss factors affecting the decision to treat fractures operatively vs non-operatively
- Evaluate different operative techniques available

# Epidemiology

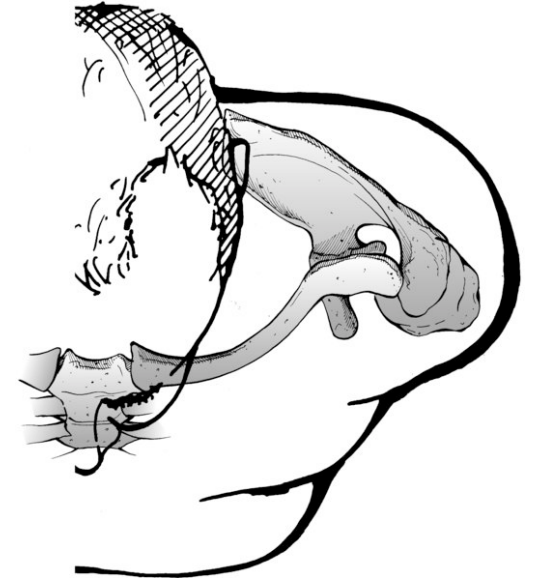
- 2.6% of all fractures
- Higher energy
  - MVC
  - Collision sports
    - Football
    - Hockey
  - Cycling
- Demographic skews younger
  - Second peak later in life from osteoporotic patients with falls



*\*From: Rockwood & Green's Fractures in Adults, 9<sup>th</sup> Ed. Robinson CM. Fractures of the clavicle in the adult: epidemiology and classification. J Bone Joint Surg Br. 1998;80(3):476-484*

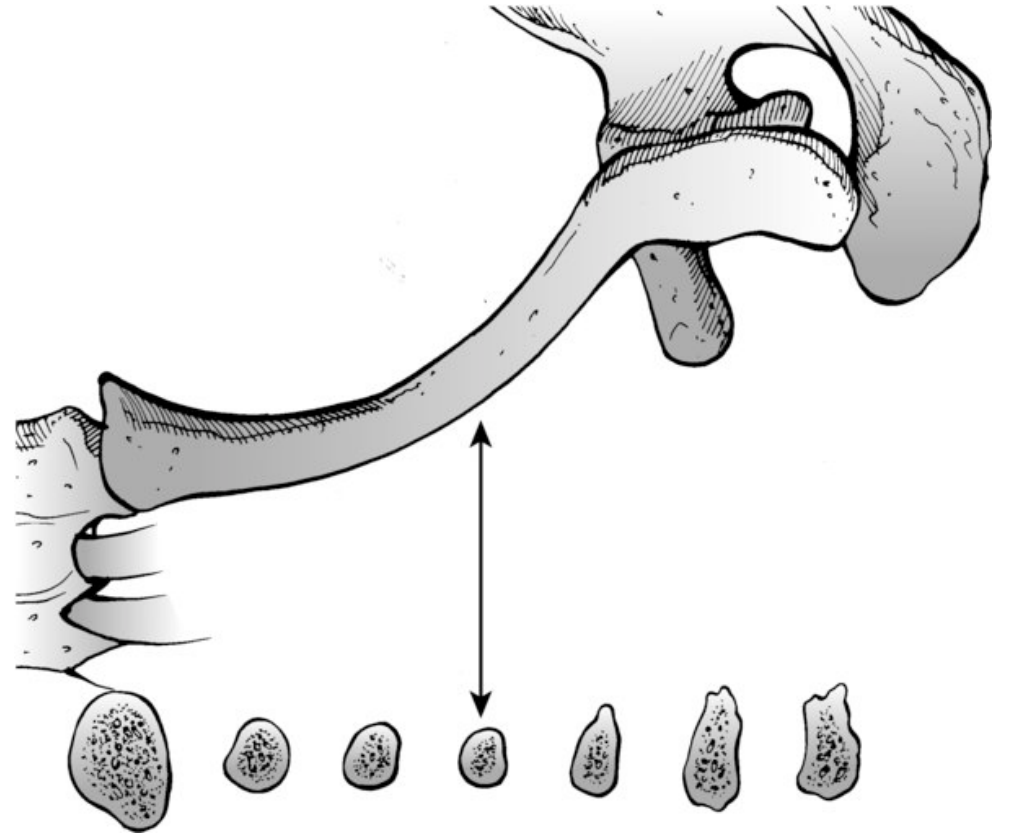
# Function

- “A strut for muscles to attach to”
- Not a weight bearing bone (for most people)
- Only connection between axial skeleton and the upper extremity



# Anatomy

- Shape
  - Flat lateral medially and laterally
    - Cancellous screws have better purchase
  - Tubular in central section
    - Cortical screws
  - Flat superior surface
  - S-shaped when viewed from above
- Articulations
  - Sternoclavicular joint
  - Acromioclavicular joint



# Anatomy/Deforming Forces

- Muscular

- Sternocleidomastoid

- Covers medial 60% of superior surface
    - Pulls medial segment proximally

- Deltoid

- Covers lateral 40% of superior surface
    - Holds distal fragment stable

- Trapezius

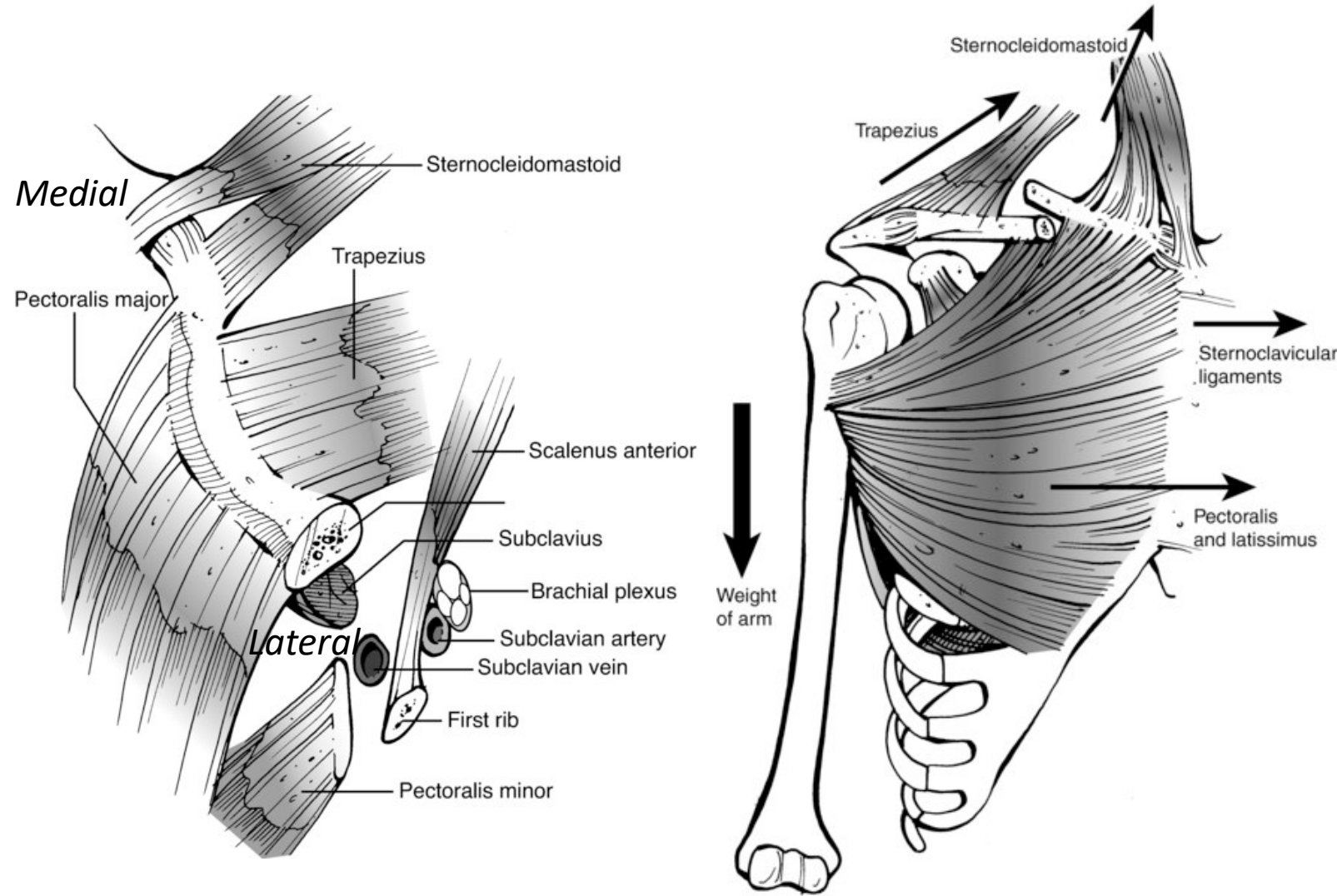
- Posterosuperior coverage

- Pectoralis

- Originates from anteroinferior surface
    - Pulls medially causing shortening

- Subclavius

- Undersurface muscle
    - Protects NV structures

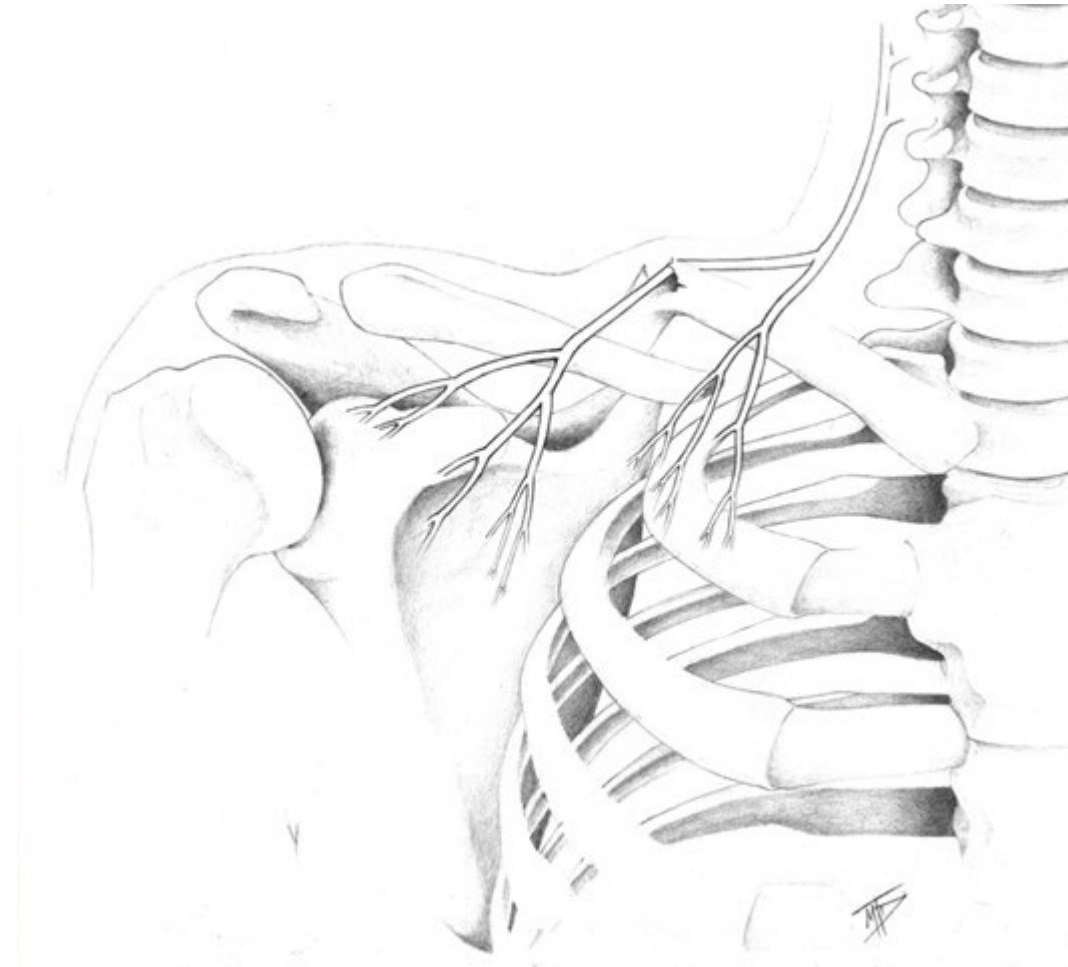


\*Rockwood & Green's Fractures in Adults, 9<sup>th</sup> Ed.

Core Curriculum V5

# Anatomy

- Neurovascular
  - Superficial
    - Supraclavicular nerves (C3-4)
      - Skin sensation running vertically
      - Frequently cut on approach to midshaft clavicle
      - Sensation generally improves with time
  - Deep
    - Subclavian vein
    - Subclavian artery
    - Brachial plexus



\*Supraclavicular nerve entrapment and clavicle fracture. O'Neill, K; Stutz, C; Duvernay, M; *J Ortho Trauma*. 26(6):e63-e65, June 2012.



# Anatomy: Deep

- Subclavian Vein

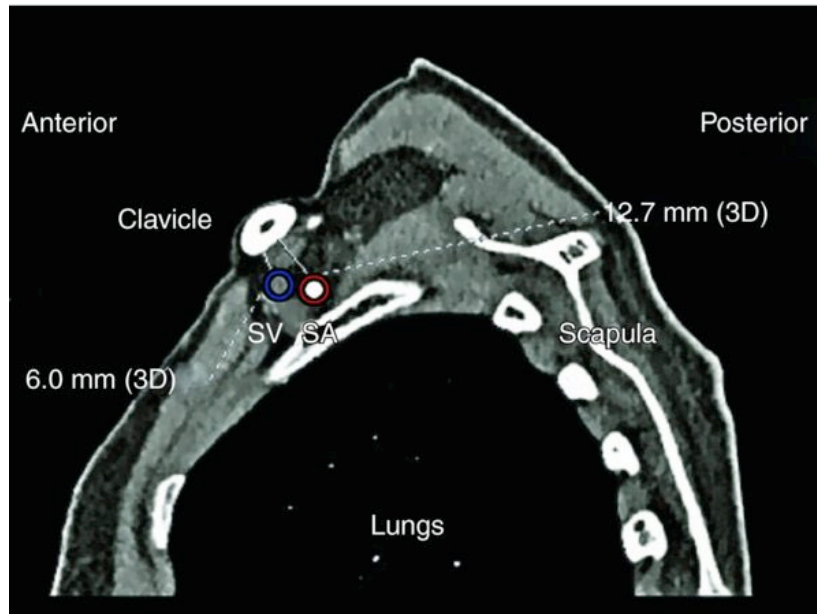
- Directly underneath clavicle separated only by subclavius mm
- Closest to bone medially
- Used for central lines

- Subclavian Artery

- More posterior than vein
- Protected by the scalenus mm

- Brachial Plexus

- Also posterior to bone
- Closest to bone in mid-portion of bone

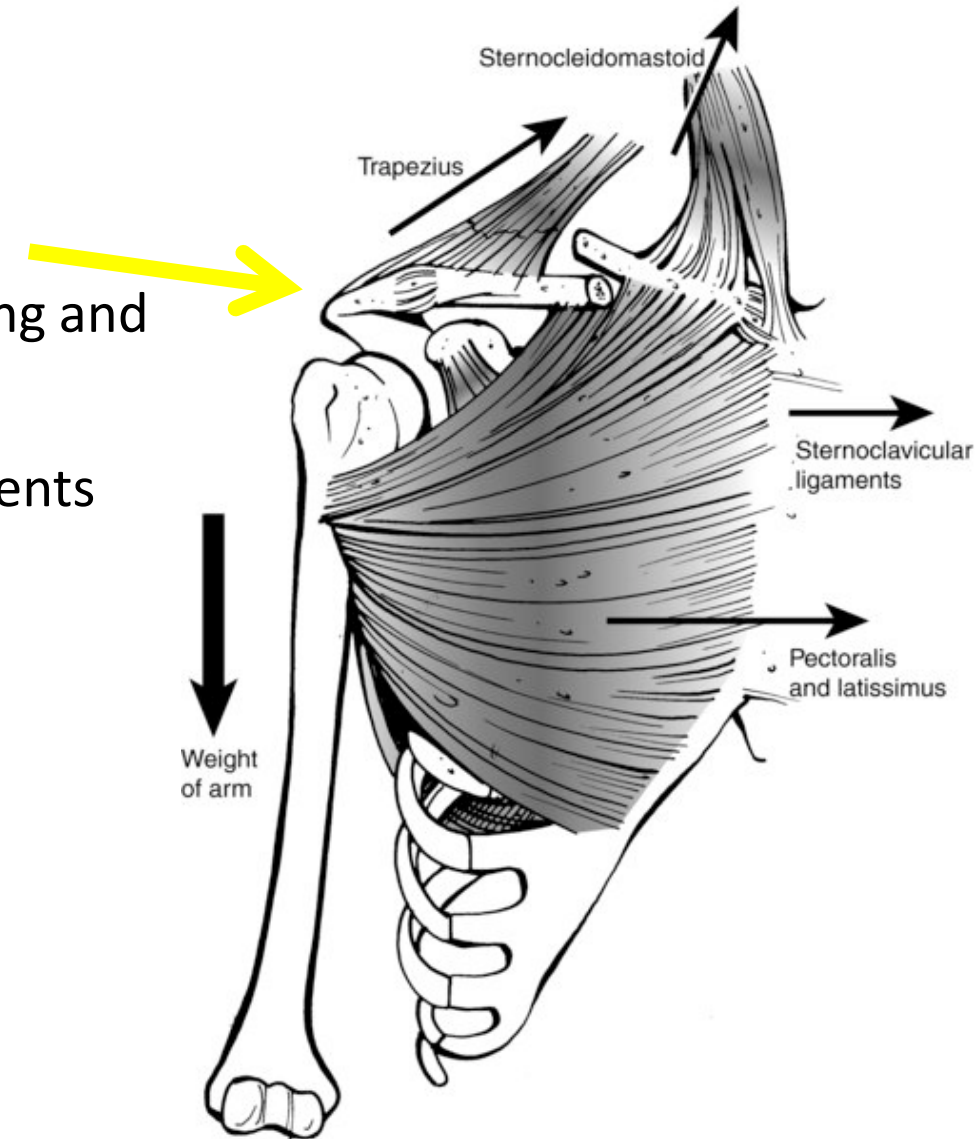


\*Rockwood & Green's Fractures in Adults, 9<sup>th</sup> Ed. From Sinha A, Edwin J, Sreeharsha B, et al. A radiological study to define safe zones for drilling during plating of clavicle fractures. *J Bone Joint Surg Br.* 2011;93B:1247–1252.



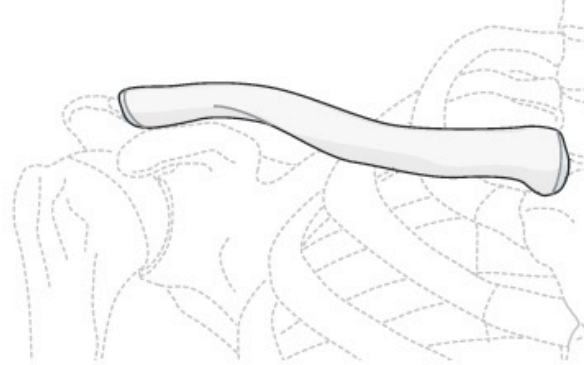
# Mechanism of Injury

- Midshaft:
  - Most common: lateral compression results in bending and axial load
  - Less common: direct blow
  - Thinnest portion of bone, fewer soft tissue attachments and therefore more likely to break
- Distal:
  - Lateral compression injuries
  - Older patients, lower energy
- Medial:
  - Rare, usually high energy direct blow



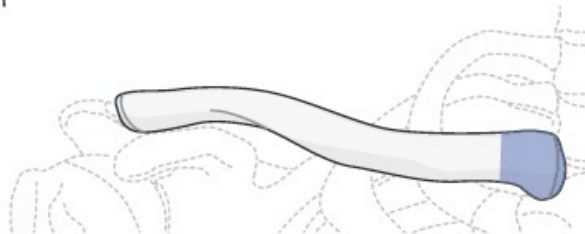# Classification: OTA vs Robinson – nearly the same

**Bone: Clavicle** 15



**Locations:** *Robinson 3*

Clavicle, **proximal (medial) end segment**  
15.1

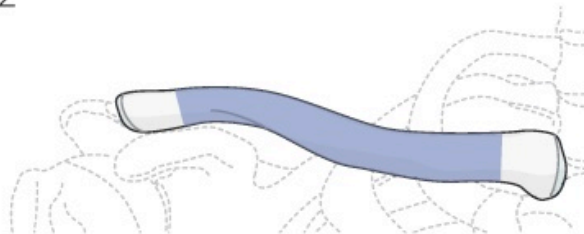


Location is determined by a square with sides the length of the widest portion of the medial end of the clavicle.

~5% of fractures

*Robinson 2*

Clavicle, **diaphyseal segment**  
15.2

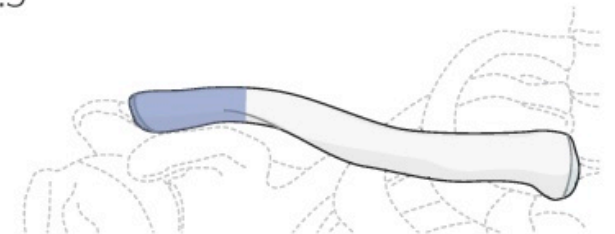


The portion between the two end segments.

~80% of fractures

*Robinson 1*

Clavicle, **distal (lateral) end segment**  
15.3

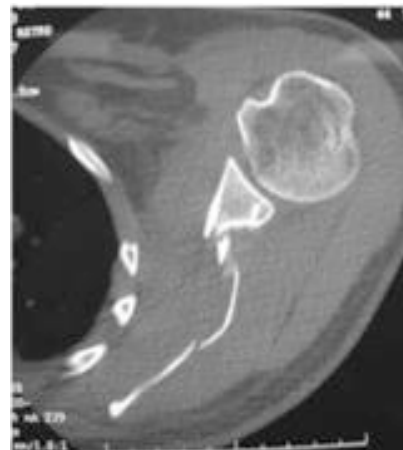
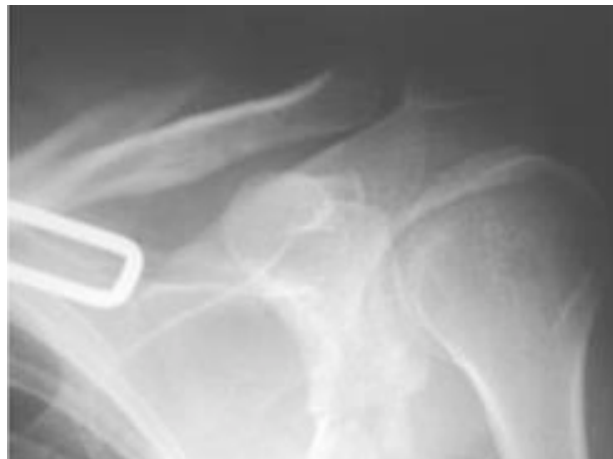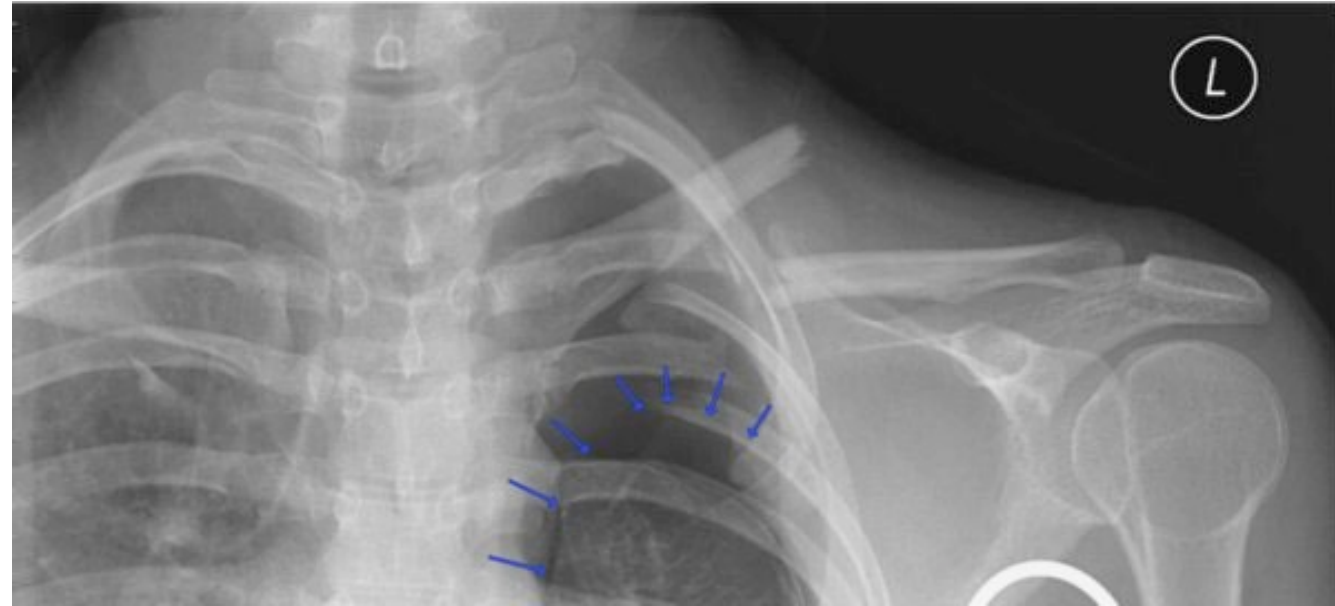


Begins at line perpendicular to the medial edge of the coracoid process. The coracoclavicular ligaments are part of this lateral end segment.

~15% of fractures

# Associated Injuries

- Rib fractures
- Proximal humerus fractures
- Pneumothorax
- Scapular fractures
  - “Floating shoulder”



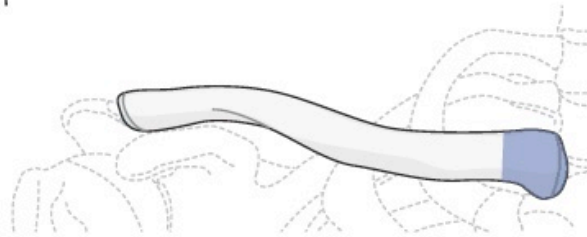
# MIDSHAFT FRACTURES

# Classification: OTA

**Bone: Clavicle** 15

## **Locations:**

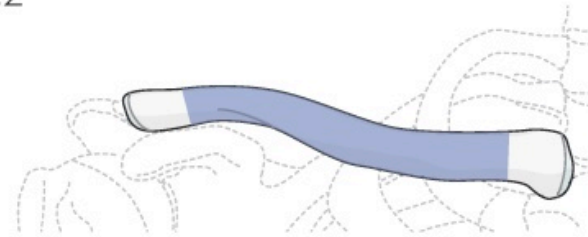
Clavicle, **proximal (medial) end segment**  
15.1



Location is determined by a square with side length equal to the length of the widest portion of the medial end of the clavicle.

~5% of fractures

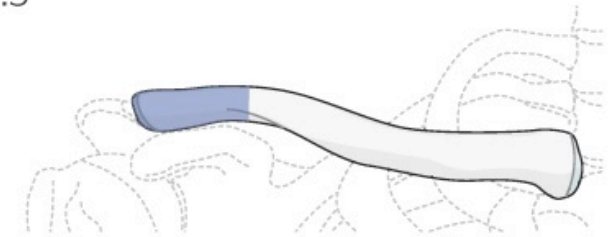
Clavicle, **diaphyseal segment**  
15.2



The portion between the two end segments.

~80% of fractures

Clavicle, **distal (lateral) end segment**  
15.3



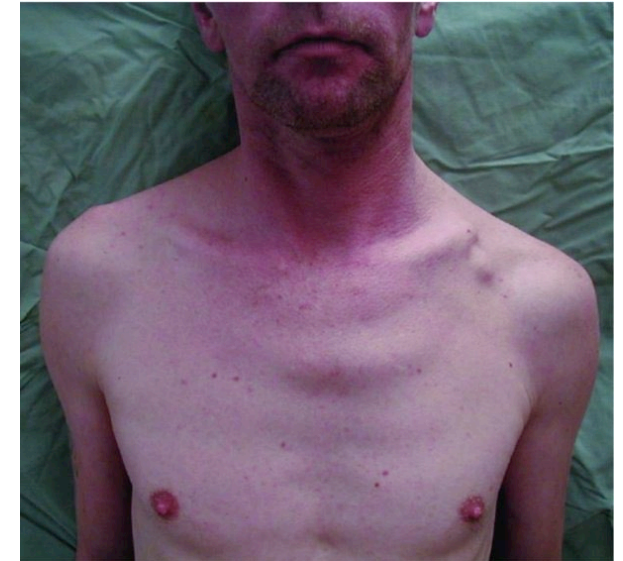Begins at line perpendicular to the medial edge of the coracoid process. The coracoclavicular ligaments are part of this lateral end segment.

~15% of fractures



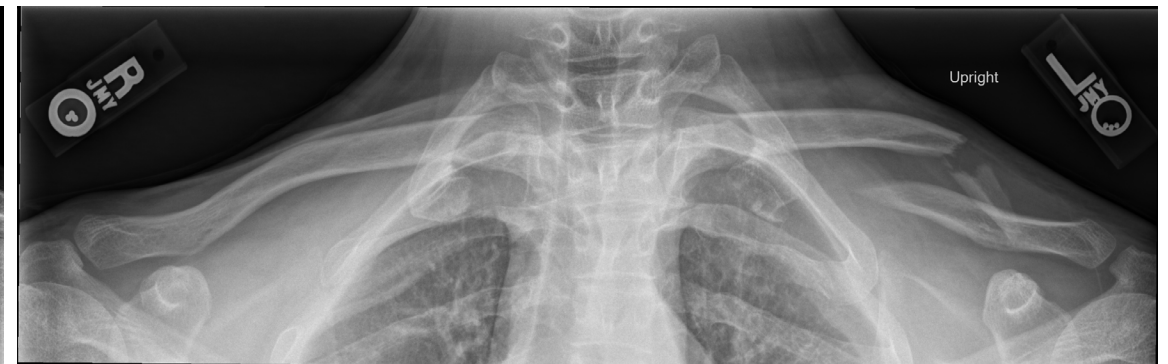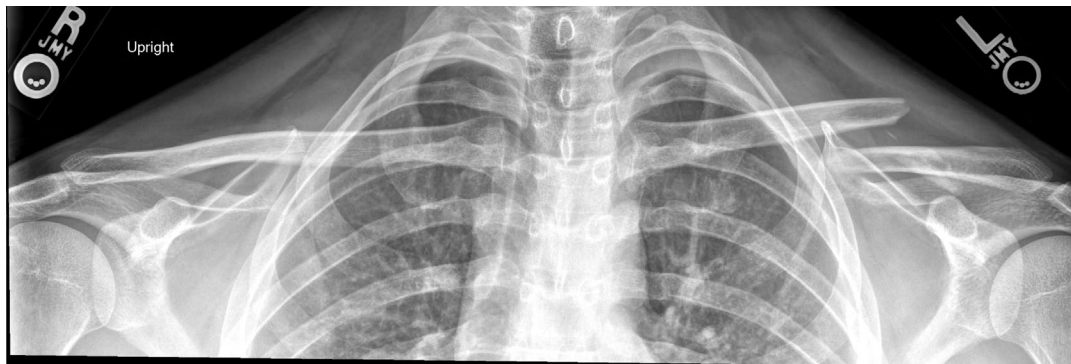
# Workup

- Physical Exam
  - Skin integrity
    - Overlying abrasions
    - Medial fragment can “button hole” through the platysma
  - NV status



*\*Rockwood & Green's Fractures in Adults, 9<sup>th</sup> Ed.*

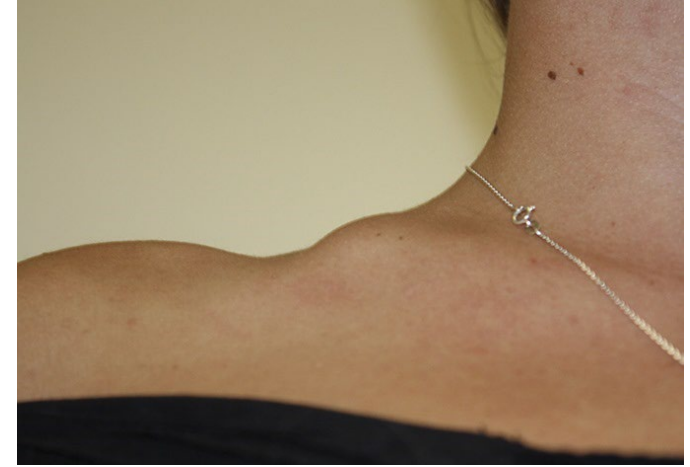- Radiographs: AP + cephalic/Zanca view
  - Prefer **upright** bilateral clavicles on same cassette – allows comparison to normal



*\*XR courtesy of author*

# Operative vs Non-operative: deciding factors

- Cosmesis: “bump or a scar”
  - Simple sling vs clavicle strap/”figure-of-8” brace: no benefit of strap
    - Sling for comfort only
  - Droopy shoulder?
- Shoulder function
- Nonunion: fracture and patient-specific characteristics
- Associated Injuries
- Polytrauma



\*The Community Orthopaedic Surgeon Taking Trauma Call: Pediatric Midshaft Clavicle Fracture Pearls and Pitfalls. Vargas-Vila, M; Mehlman, C; Pennock, A. *J Ortho Trauma*: August 2019 - Volume 33 - Issue - p S1-S5.



# Shoulder Function with Non-operative Care

- McKee MD, Pedersen EM, Jones C, et al. Deficits following nonoperative treatment of displaced midshaft clavicular fractures. *J Bone Joint Surg Am.* 2006;88(1):35–40.
  - Motion preserved
  - Significantly reduced strength in max/endurance flexion, max/endurance abduction, max/endurance external rotation, max/endurance internal rotation.
  - Mean Constant score 71 points & mean DASH score 24.6 points = residual disability
  - However.... The amount of shortening not quantified

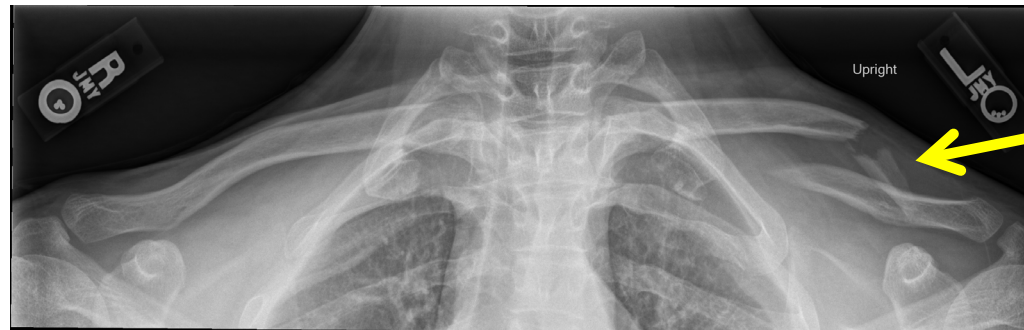VS...

- Hillen RJ, Schraa ER, van Essen T, Burger BJ, Veeger DH. Long-term follow-up of conservatively treated midshaft clavicular fractures on functional outcome. *J Orthop.* 2019 Sep 11;18:80-85.
  - 13 year f/u, ~1 cm shortening; 18 adult patients
  - No significant long term deficits in strength

**Minimal shortening = minimal deficit? Literature unclear!**

# Nonunion Risk

- Liu W, Xiao J, Ji F, Xie Y, Hao Y. Intrinsic and extrinsic risk factors for nonunion after nonoperative treatment of midshaft clavicle fractures. *Orthopaedics & Traumatology: Surgery & Research*, 2015, Vol.101 (2), p.197-200.
  - **Amount of displacement:** more displacement = less likely to heal
    - 2 cm displacement is frequently used in literature as a cutoff
    - *Currently, specific number found to be less clear*
  - **Smoking**
  - **Fracture comminution:** Z fragment



# Calculating Nonunion Risk: patient education

“Ready Reckoner” Score: Murray et al, Edinburgh 2013

Overall Displacement (mm)	Non-comminuted Fx Non-smoker	Comminuted Fx Non-smoker	Non-comminuted Fx Smoker	Comminuted Fx Smoker
10	2	3	6	10
15	3	6	12	19
20	7	12	23	34
25	14	23	39	52
30	26	39	57	70
40	62	74	86	92

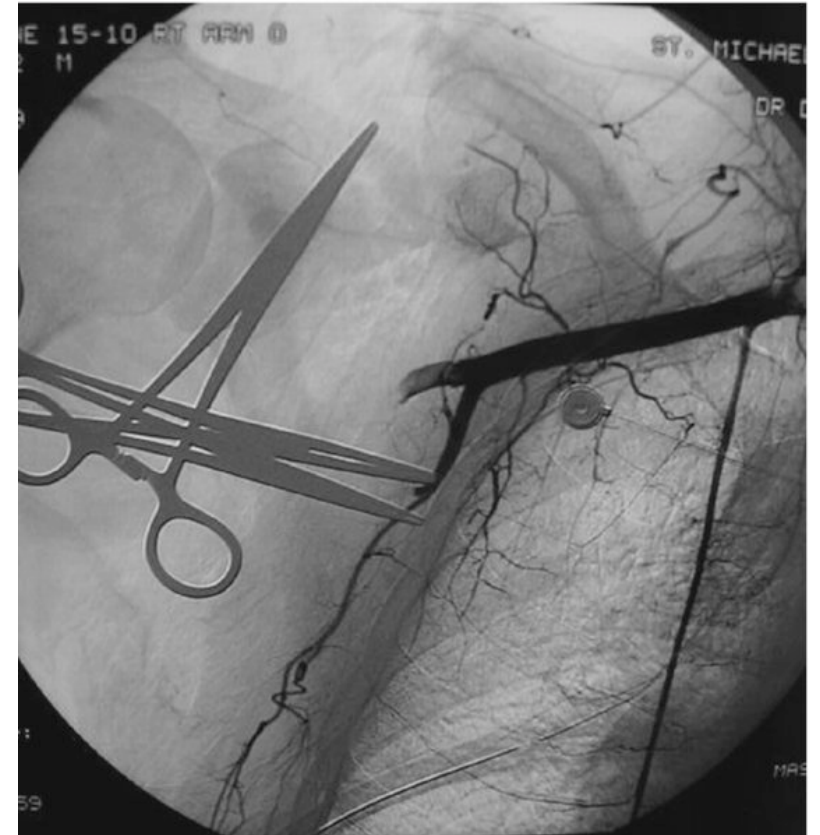
*Smoking and comminution each automatically increases risk ~3+x*



\*Data from JBJS Am. 2013;95:1153-8.

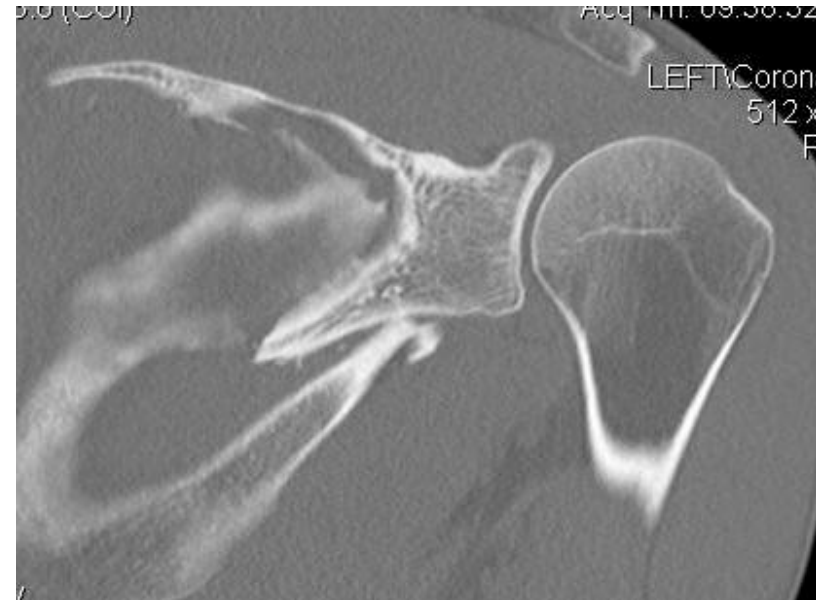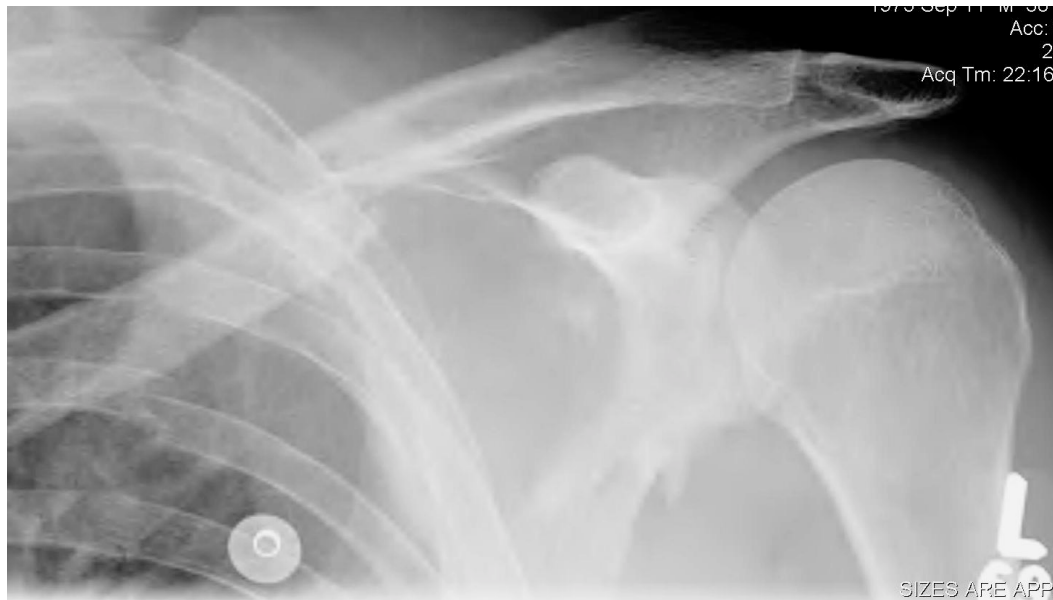# Associated Injuries: operative management

- Severe chest wall trauma
  - Vascular injury requiring repair
  - Progressive neurologic deficit/plexus palsy
    - ORIF clavicle stabilizes the vascular or neuro repair!
  - *Ipsilateral upper extremity injuries/fractures?*
  - *Multiple ipsilateral upper rib fractures?*
- Scapulothoracic dissociation
  - Traction injury
  - Widened space between scapula and spine
  - **Distracted** clavicle fracture
  - Beware of vascular & brachial plexus injuries!



# Associated Injuries: operative management

- “Floating shoulder”
  - Associated displaced glenoid neck fracture
  - Frequently can only fix the clavicle and the glenoid will reduce into acceptable alignment



# Polytrauma

- Fixation can help advance WB in a patient with B UE injuries

**“Give them back an arm to use”**

- Facilitate physical therapy/mobilization
  - Shorten hospital stay
  - Minimize pain medication needs

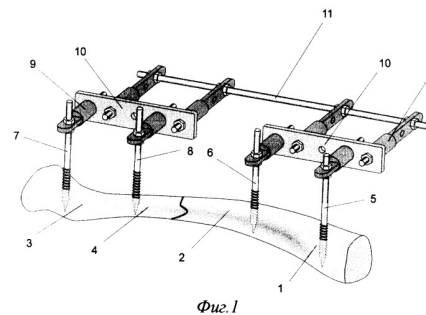
# Returning to Work as a Deciding Factor

- Manual laborers?
- Pro athletes?
  - NFL players returned to sport faster  
*Harris et al, Orthopaedics 2017*
    - 44% returned the same season
    - 96% returned to sport at 1 year
    - However, QB's and RB's did worse compared to other positions
  - Dr Peter Millett @ Steadman Clinic: “For example, in certain instances where there was an important event, I have had some athletes back to competition in as little as 2 weeks.”



# Operative: Options

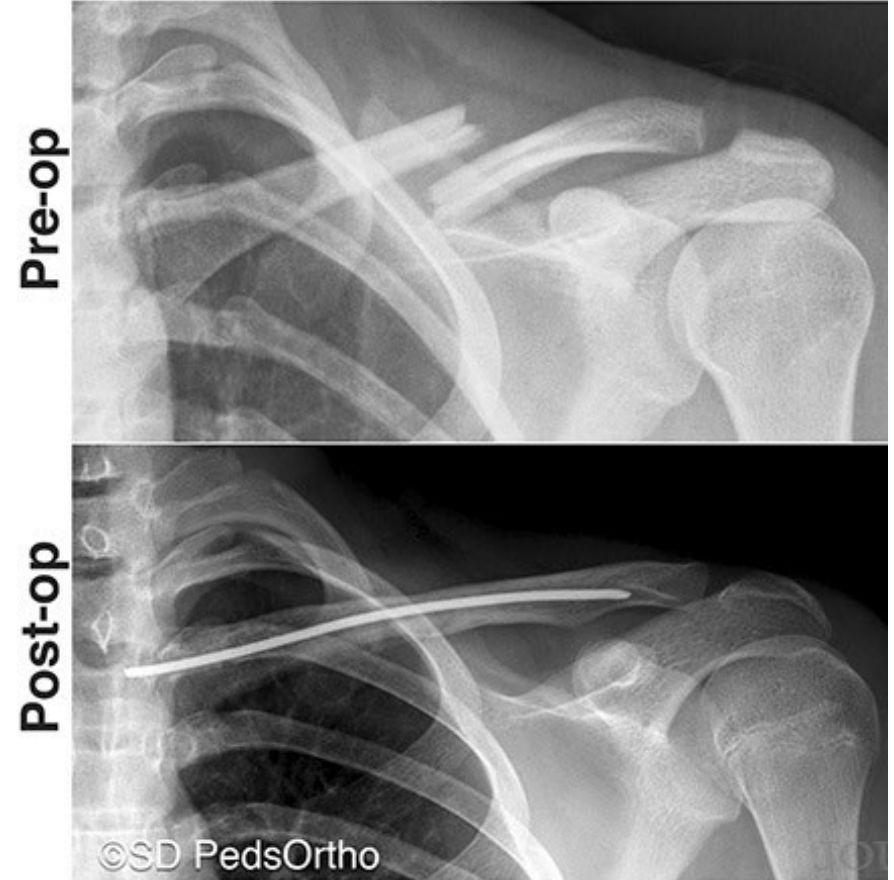- ORIF: plating
  - Superior vs anterior
- Intramedullary fixation
- External fixation?
  - Not popular in the US
  - Ilizarov-type constructs



# Intramedullary Implants

- Takes advantage of IM canal in central 1/3
- Advantage
  - Soft tissue friendly
  - Best for simple fracture patterns
- Disadvantage:
  - Can't lock rotation with most devices
  - Rate of reduction loss is high
  - High rate of ROH with unlocked implants
  - Fear: pin migration with unlocked/non-threaded!
- Options
  - Commercially available products
  - Pediatric titanium elastic nails
  - Generic Steinmann pins
  - Cannulated screws

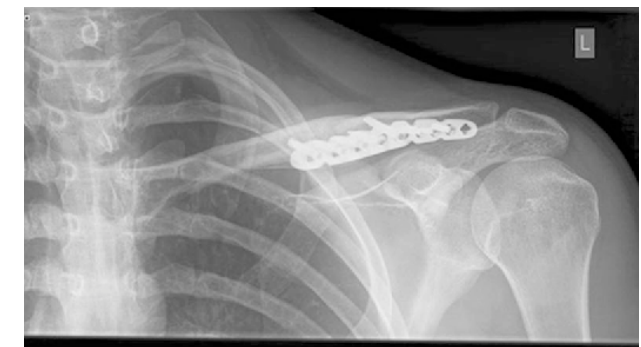
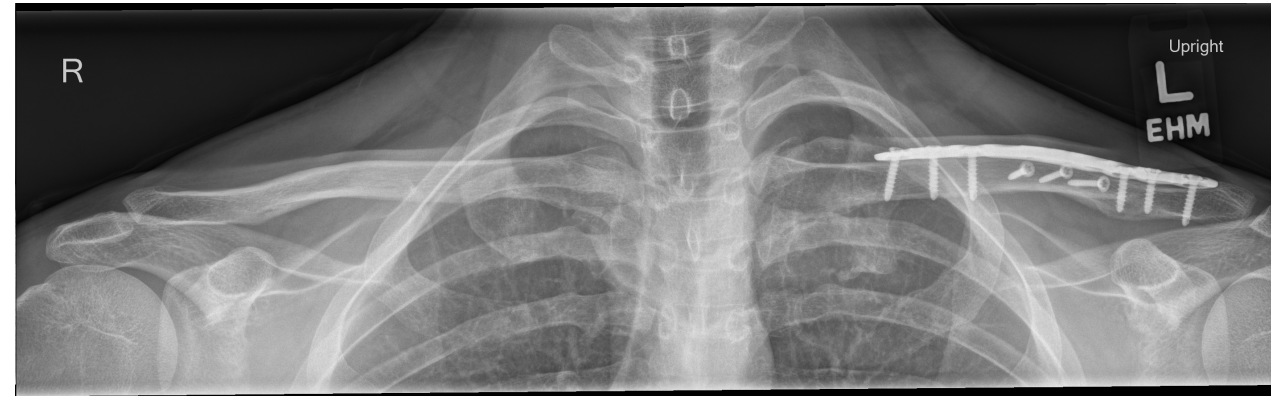
## Intramedullary fixation



\*The Community Orthopaedic Surgeon Taking Trauma Call: Pediatric Midshaft Clavicle Fracture Pearls and Pitfalls. Vargas-Vila, M; Mehlman, C; Pennock, A. *J Ortho Trauma*: August 2019 - V33, p S1-S5.

# Fixation: Techniques

- ORIF: mainstay in US
  - Obtain anatomic reduction
    - Lag screw + neutralization plating
    - Compression mode plating
  - Stabilize with rigid implants
- Plate placement options
  - Superior = prominent, resists vertical translation, more extensile to both ends of bone
  - Anterior = less prominent, longer screws?, less extensile
    - \*No RCT comparing different plate locations\**
  - Dual mini-frag plates?
    - More soft tissue stripping but less (3.7%) removal of symptomatic hardware?
    - Czajka CM, Kay A, Gary JL, et al. Symptomatic implant removal following dual mini-fragment plating for clavicular shaft fractures. *J Orthop Trauma*. 2017;31:236–240



# ORIF Technique

- Radiolucent OR table
- Position: semi-supine vs beach chair, usually with central bump under spine to hyper-extend chest
- XR views coming in from the head: AP + 30 deg cephalic tilt
- Arm can be prepped in or out

# Technique Videos

- ORIF midshaft clavicle: NYU/Dr Egol
  - <https://otaonline.org/video-library/45036/procedures-and-techniques/multimedia/16731455/displaced-comminuted-right-clavicle-fracture>
- IMN clavicle: Steadman Clinic/Dr Millett
  - <https://otaonline.org/video-library/45036/procedures-and-techniques/multimedia/16731453/intramedullary-fixation-of-midshaft-clavicle>

# Rehab Protocols

- Immediate post-op
  - Dry dressing over wound
  - Simple sling for comfort
  - Start pendulum exercises ASAP, OK for motion for hygiene as needed
- My philosophy: **“motion first, then lifting”**
  - Start gentle lifting once can obtain ~120 degrees elevation
  - No “real” lifting until 6 weeks
  - Avoid aggravating activities like heavy lifting, pushups until at least 3 months

# Sequelae

- Supraclavicular nerve iatrogenic laceration
  - Patients report a numb patch centered on the incision
  - Usually improves with time (months/years)
  - Can be irritating to women who can't feel their bra strap and backpack wearers
- Hardware Irritation/Removal of hardware: ~15-30%
  - Prefer > 1 year post-op to ensure complete healing
  - Backpackers, military personnel common to be irritated



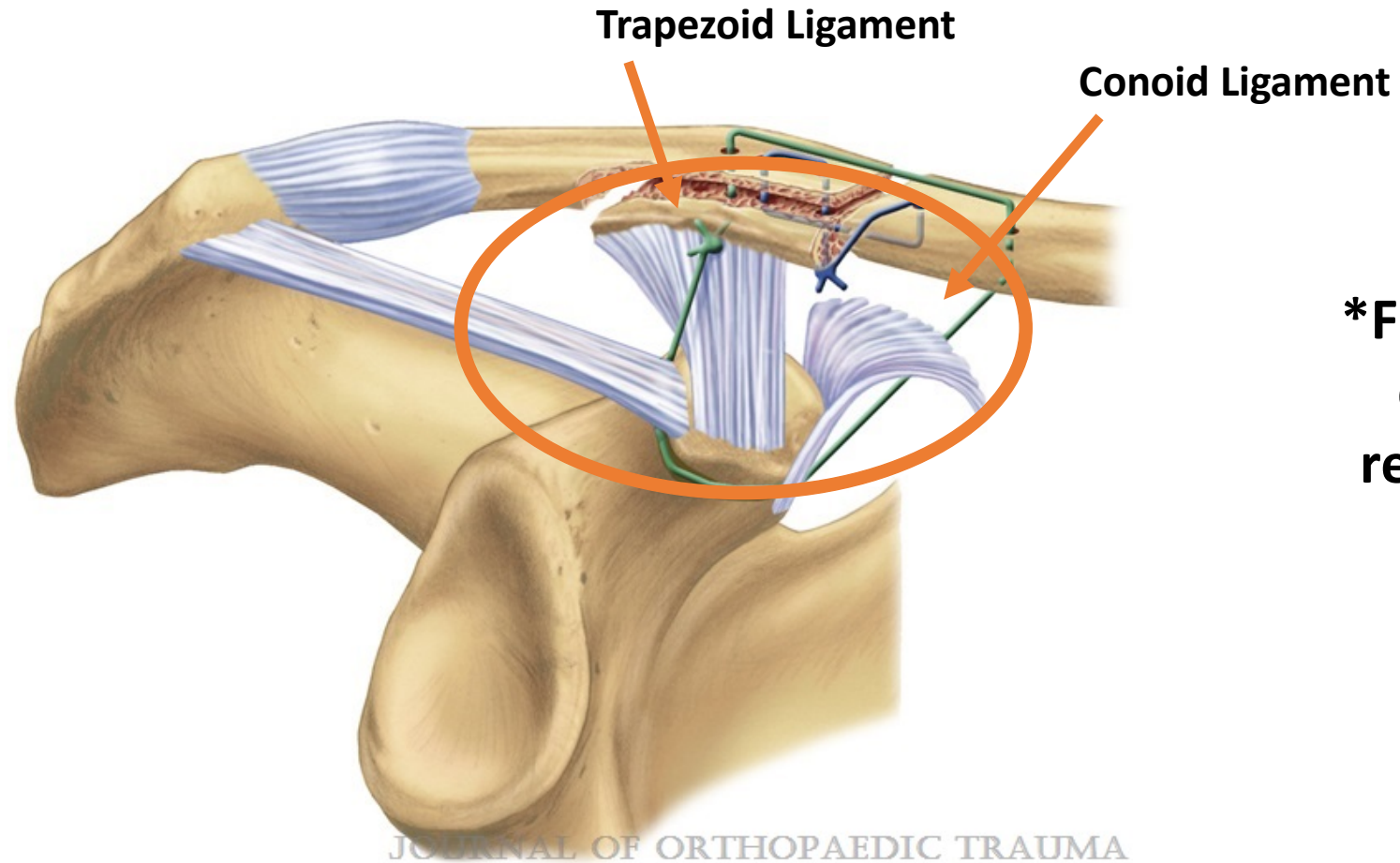
# Outcomes

- Union
  - >95% union with ORIF
- Clinical vs Radiographic Union
  - Asymptomatic nonunion does not necessarily need to be treated!
- Shoulder function excellent
- Generally plateau by a year post-op regardless of treatment chosen

**Recent Data: 94-100% union rates!**

# DISTAL FRACTURES

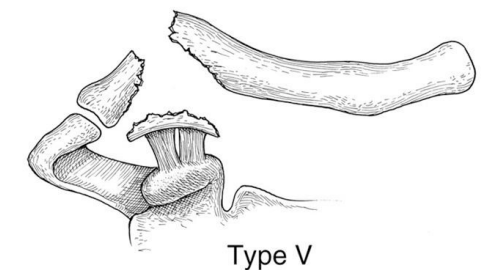
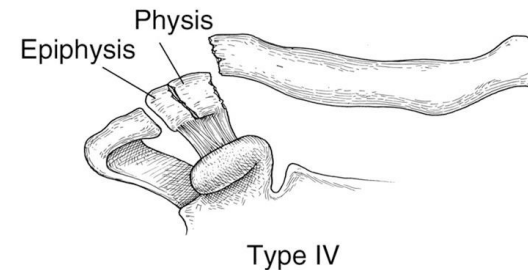
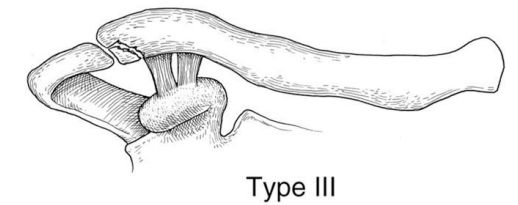
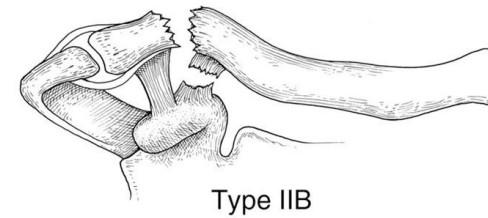
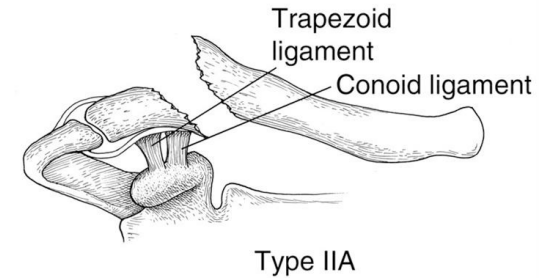
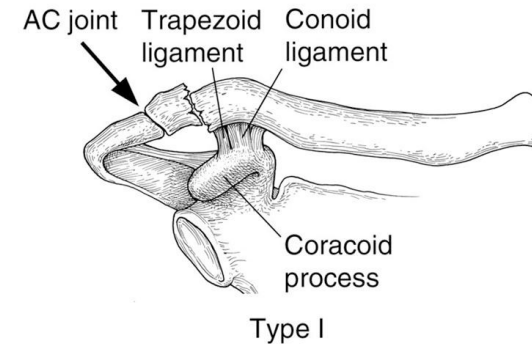
# Distal: Anatomy



**\*Fragment stability determined by relationship to CC ligaments\***

# Distal: Neer Classification

- Type I: CC ligaments intact
- Type II: CC ligaments detached from the medial fragment, trapezoid attached to the distal fragment
  - IIA (Rockwood mod): Both conoid and trapezoid attached to the distal fragment
  - IIB (Rockwood mod): Conoid detached from the medial fragment
- Type III: Extension into the AC joint.
- Type IV: Pediatric physeal fx
- Type V: Comminuted



# Distal: Op vs Non-op

Why does this classification matter???

## Pattern determines Plan

Type 2's and Type 5 are notorious nonunion generators!

*2A: 56% nonunion with non-op*

*2B: 30 – 45% nonunion with non-op*

# Distal: Fixation Challenges

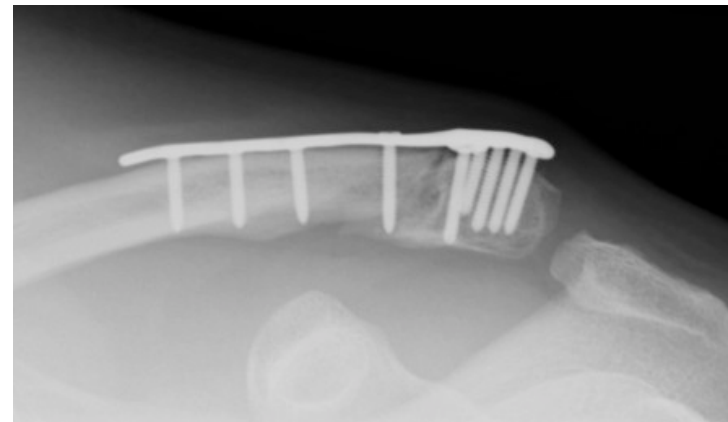
- Bone is largely cancellous laterally
- Templating important: ensure adequate purchase in small lateral fragment

# Distal: Surgical Options

- ORIF with superior plating
- ORIF with hook plating
- Coracoclavicular ligament reconstruction

# Distal: Superior plates

- Lateral versions of anatomic plates
  - Have more screw holes clustered together to obtain maximal fixation
    - Goal: At least 4 screws in the distal segment
- Locking options laterally
- Can be augmented with CC ligament constructs

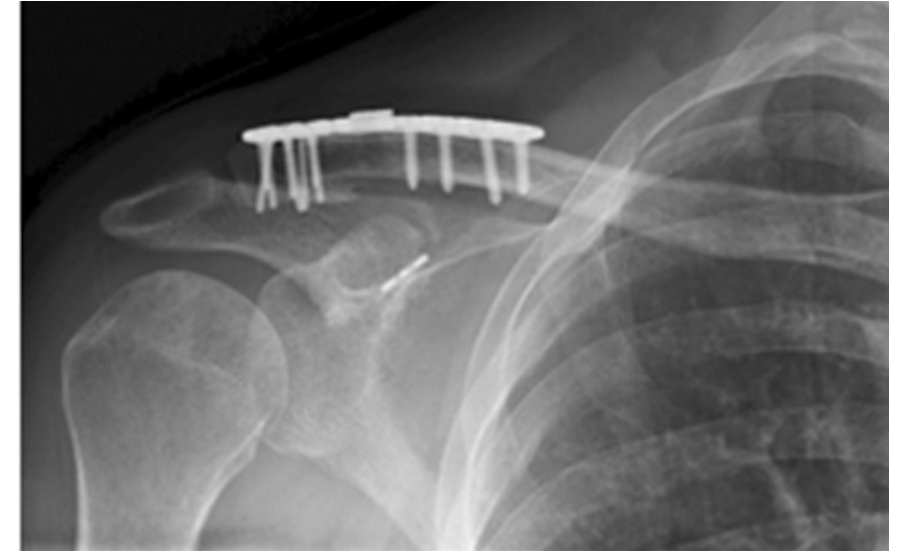
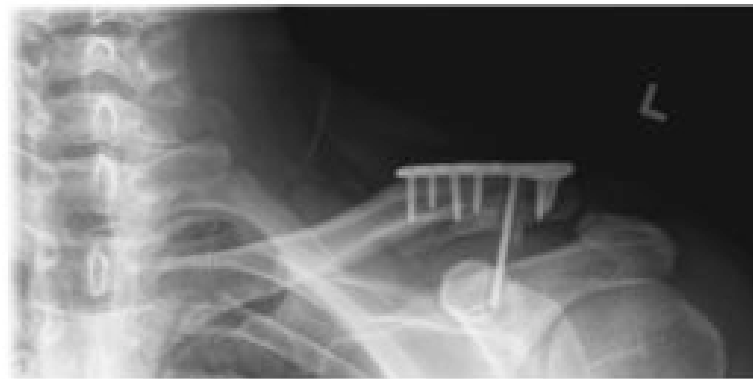
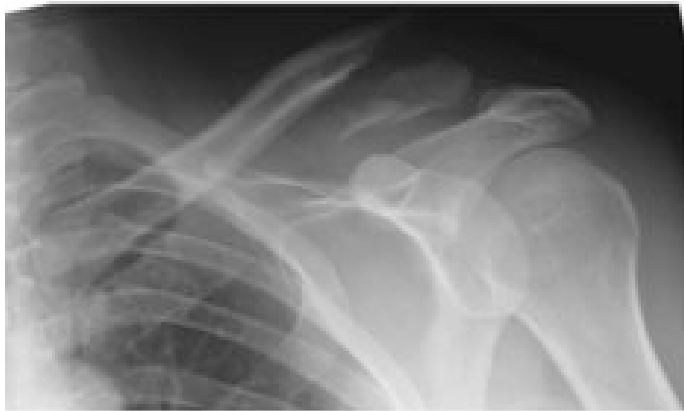
*\*Rockwood & Green's Fractures in Adults, 9<sup>th</sup> Ed.*



# Distal: Superior plates

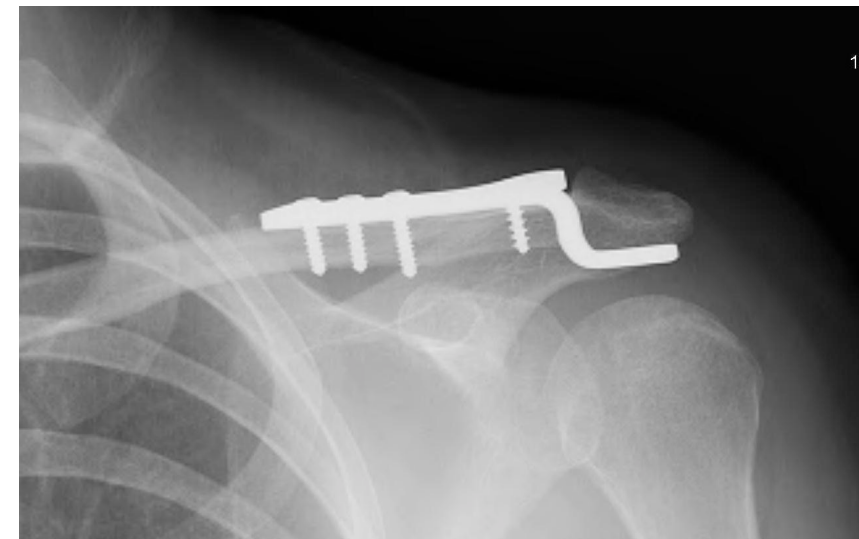- Anatomic lateral plates: augmented fixation via CC ligament constructs
  - CC screw augments
  - Suture/suture button fixation
  - Ligament allografts



*\*Rockwood & Green's Fractures in Adults, 9<sup>th</sup> Ed.*

# Distal: Hook plates

- Design: Superior plate with attached hook that wedges into the posterior subacromial space
- Advantage:
  - Resists superior displacement forces
  - Direct compression on the fracture fragment
  - Allows for slight motion at the AC joint
- Disadvantages:
  - **Has to be removed** due to subacromial irritation
  - Very little fixation directly into the lateral fragment
  - Can over-reduce the lateral segment
    - Measure the depth of the hook desired!



\*XR: Rockwood & Green's Fractures in Adults, 9<sup>th</sup> Ed.

# Technique Videos

- ORIF using a hook plate: Michigan/Dr Hake
  - <https://otaonline.org/video-library/45036/procedures-and-techniques/multimedia/16731459/distal-clavicle-fracture-orif-with-a-hook-plate>
- ORIF using lateral plate + CC suture augment: Dr Millett
  - [https://www.arthrex.com/resources/video/WUcrUwQXLk-InQFSiP8\\_vA/distal-clavicle-fracture-repair-utilizing-a-knotless-coracoid-fixation-device](https://www.arthrex.com/resources/video/WUcrUwQXLk-InQFSiP8_vA/distal-clavicle-fracture-repair-utilizing-a-knotless-coracoid-fixation-device)

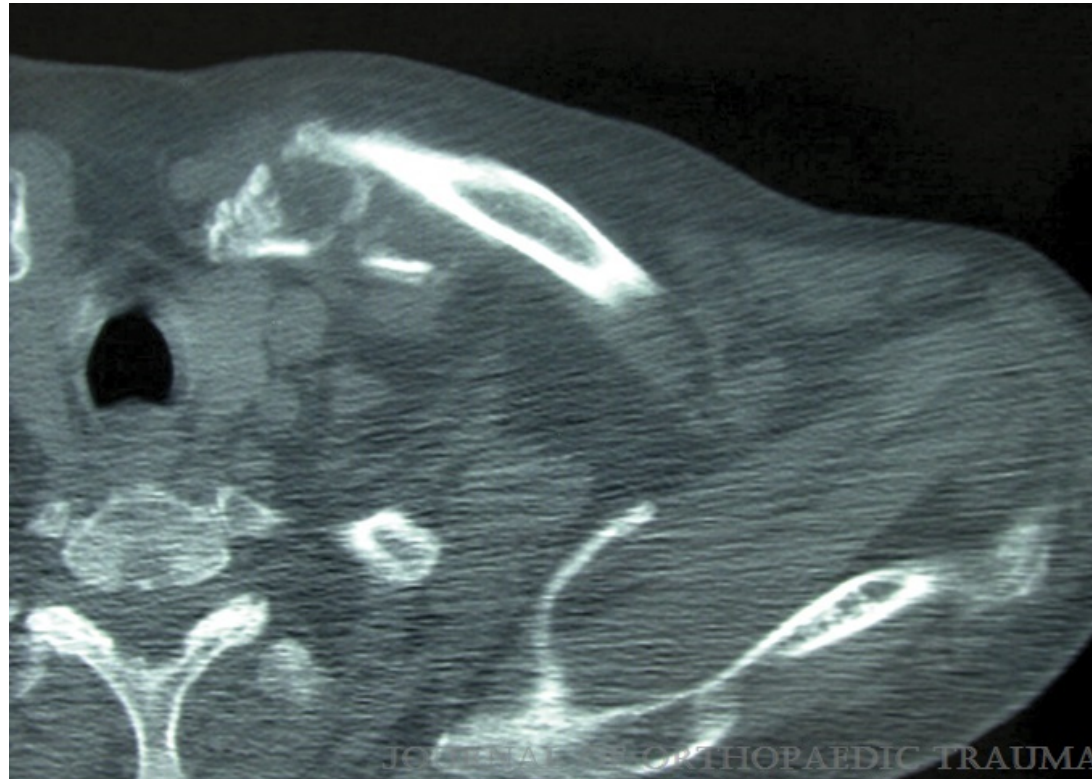
# MEDIAL FRACTURES

# Medial

- **Rare!** ~3% of all clavicle fractures
  - 80% are non-displaced
  - ~50% have associated thoracic/chest wall trauma
- Can be a variation on a sternoclavicular dislocation
  - 50% are intra-articular
- Pediatric physeal fracture possible
  - 80% of growth comes from medial physis
  - Physis may not be closed in 20-22 y/o patients

# Medial

- Nearly all will do well non-operatively, esp if non/minimally displaced



\*Traumatic Floating Clavicle: A Case Report. Serra, JT; Tomas, J; Batalla, L; Pedemonte, J; Pacha, D; Molero, V; Carrera, L. *J Ortho Trauma* 25(10):e98-e99, Oct 2011.

# Medial: Operative choices for displaced fx

- ORIF
  - Frequently challenging due to small working area
  - ROH often needed
  - Good results when can get appropriate fixation
- Other implants: k-wires, sternal wires, tension band constructs
- Soft tissue-only repairs



# Conclusions

- Displaced midshaft clavicle fractures should be considered for fixation primarily if at risk for nonunion, though other criteria may affect decision making:
  - Smokers
  - Highly displaced
  - Comminuted
- Distal fractures of the Neer 2 and 5 groups should be treated surgically due to the high risk of nonunion
- ORIF with pre-contoured plates has a high success rate with few complications
- Medial fractures can be managed non-operatively most of the time with good success

# Additional References

Figures used with permission: McKee M. Clavicle Fractures. In: Tornetta P, Ricci WM, eds. Rockwood and Green's Fractures in Adults, 9e. Philadelphia, PA. Wolters Kluwer Health, Inc; 2019.

- Canadian Orthopaedic Trauma Society. Nonoperative treatment compared with plate fixation of displaced midshaft fractures: a multicenter, randomized clinical trial. *J Bone Joint Surg Am.* 2007;89(1):1–10.
- Clement ND, Goudie EB, Brooksbank AJ, et al. Smoking status and the Disabilities of the Arm Shoulder and Hand score are early predictors of symptomatic nonunion of displaced midshaft fractures of the clavicle. *Bone Joint J.* 2016;98-B:125–130.
- Hillen RJ, Schraa ER, van Essen T, Burger BJ, Veeger DH. Long-term follow-up of conservatively treated midshaft clavicular fractures on functional outcome. *J Orthop.* 2019 Sep 11;18:80-85.
- McKee MD, Pedersen EM, Jones C, et al. Deficits following nonoperative treatment of displaced midshaft clavicular fractures. *J Bone Joint Surg Am.* 2006;88(1):35–40.
- McKee RC, Whelan DB, Schemitsch EH, et al. Operative versus nonoperative care of displaced midshaft clavicular fractures: a meta-analysis of randomized clinical trials. *J Bone Joint Surg Am.* 2012;94(8):675–684.
- Murray IR, Foster CJ, Eros A, Robinson CM. Risk factors for nonunion after non-operative treatment of displaced midshaft fractures of the clavicle. *JBJS Am.* 2013;95:1153-8.
- Sinha A, Edwin J, Sreeharsha B, et al. A radiological study to define safe zones for drilling during plating of clavicle fractures. *J Bone Joint Surg Br.* 2011;93B:1247–1252.
- Vannabouathong-C, Chiu J, Patel R, Sreeraman S, Mohamed E, Bhandari M, Koval K, McKee MD. An evaluation of treatment options for medial, midshaft, and distal clavicle fractures: a systematic review and meta-analysis. *J Shoulder Elbow Surg Intl.* 2020 May 4;4(2):256-271.