

Impending and Pathologic Fractures

Trey Gurich, MD

Faculty, Department of Orthopaedic Surgery

Prisma Health-Upstate

University of South Carolina School of Medicine- Greenville

Greenville, South Carolina

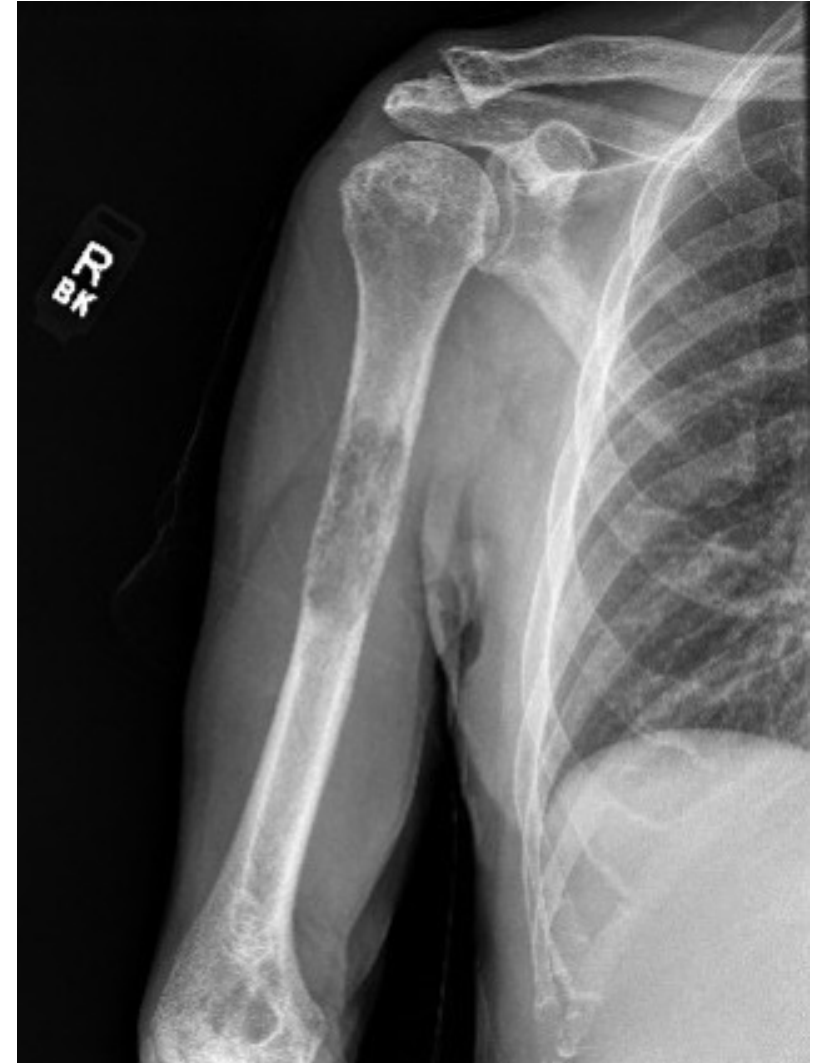


Objectives

- Describe most common entities and epidemiology for osseous metastatic disease
- Diagnosis and work-up of metastatic bony disease
- Evaluation of impending pathologic fractures
- Non-operative modalities/treatment
- Estimation of prognosis/survival in order to plan fixation/reconstruction
- Recognize disease-specific considerations
- Treatment techniques for fixation and reconstruction

Epidemiology

- American Cancer Society predicts ~1.7 million new cases of cancer per year
 - 50% of which will metastasize to the skeleton
- The role of the orthopedic surgeon is to:
 - 1) Aid in diagnosis of bony metastatic disease
 - 2) Aid in decision making regarding non-operative vs. operative modalities
 - 3) Recognize disease specific considerations
 - 4) Perform fixation or reconstruction



Epidemiology

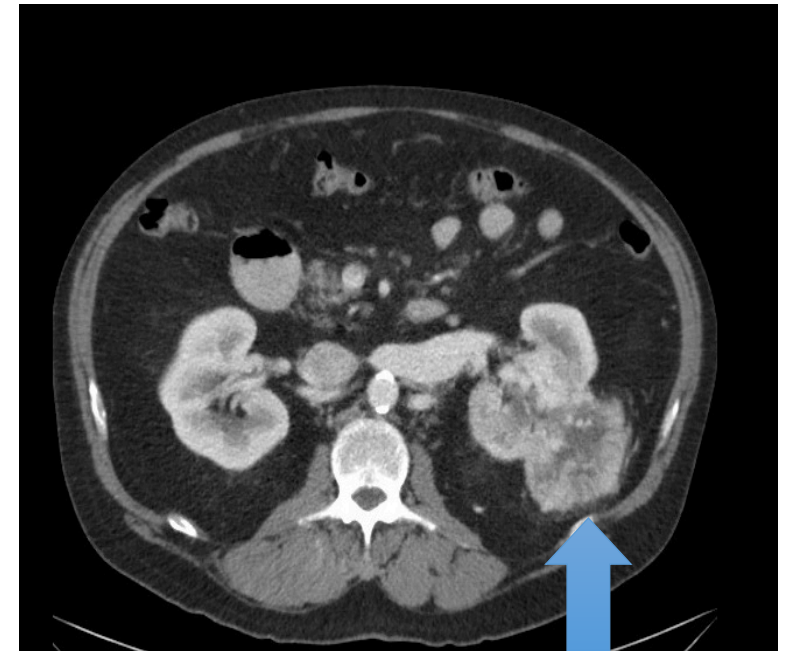
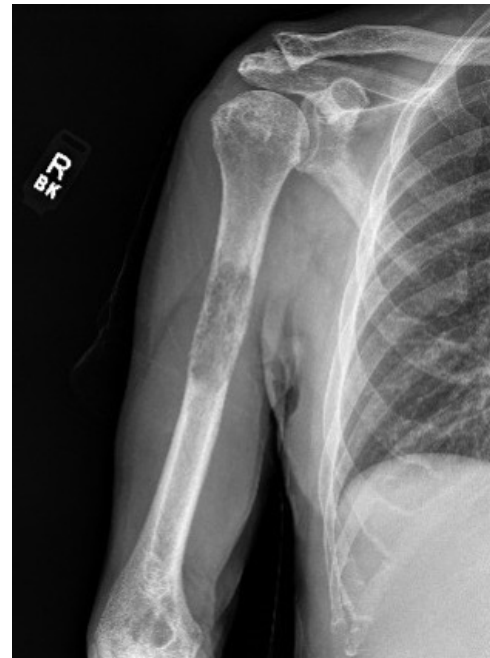
- Recognize the most common primary malignancies that metastasize to or affect the axial or appendicular skeleton (**red = more common**)

- **Carcinomas:**

- Breast
- Thyroid
- Renal
- Lung
- Prostate
- Gastrointestinal (less common)

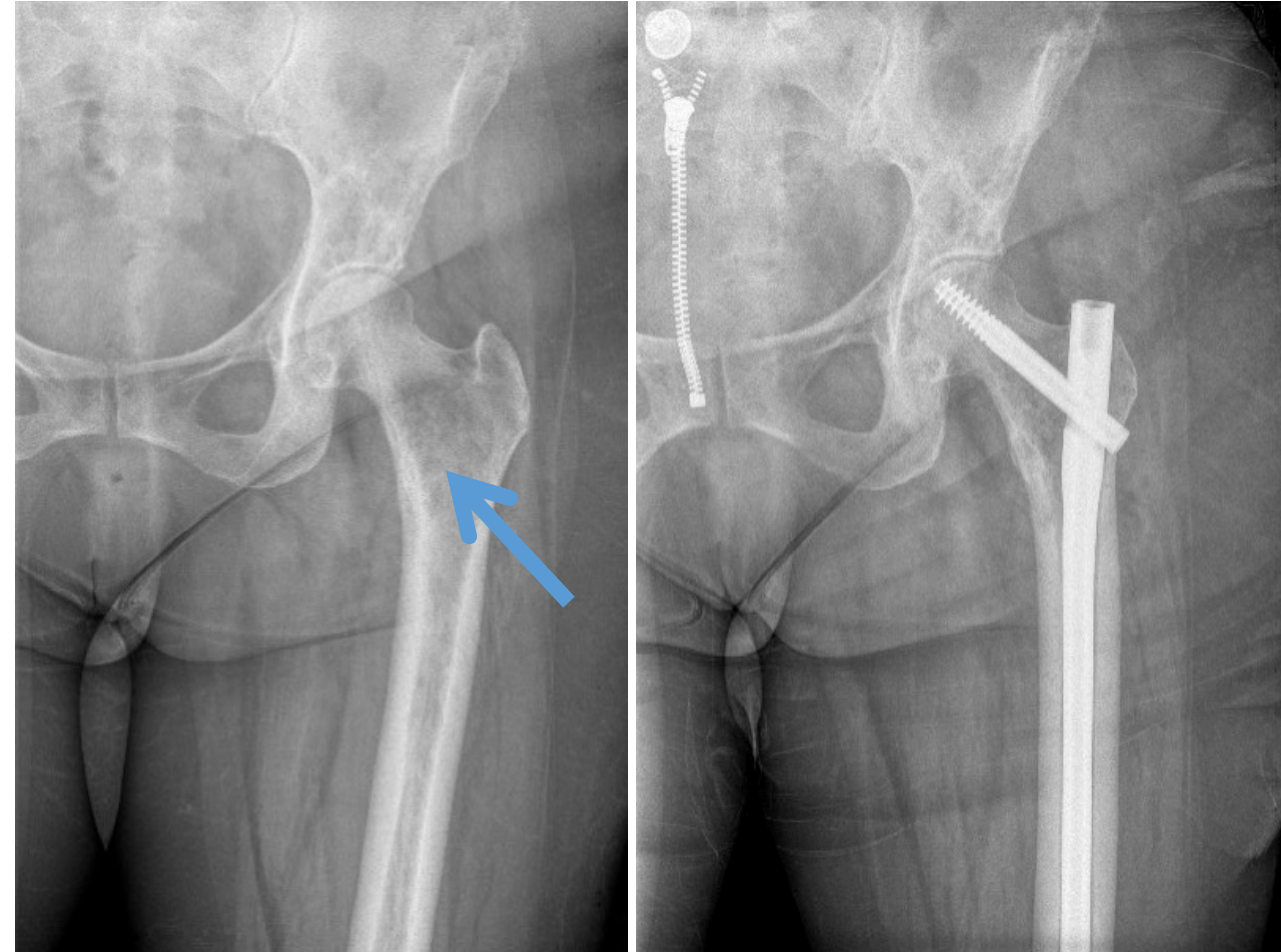
- Other:

- **Lymphoma**
- Leukemia
- **Myeloma**
- Melanoma
- Sarcoma (rare)



Epidemiology – Skeletal Related Events

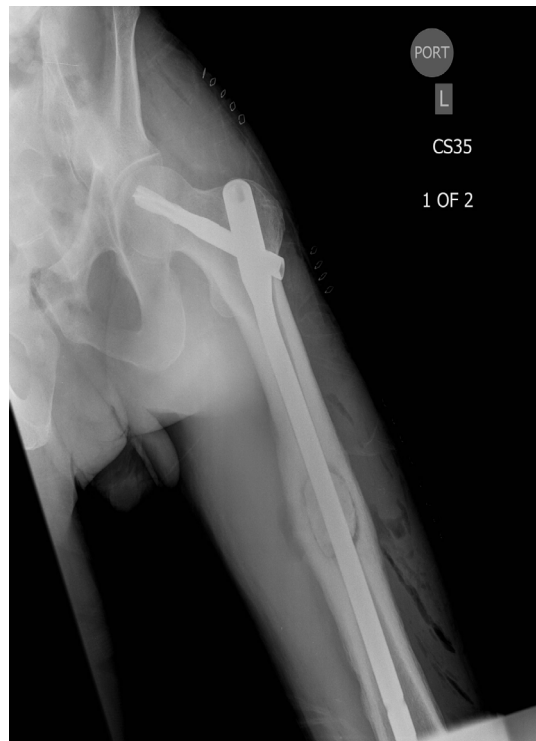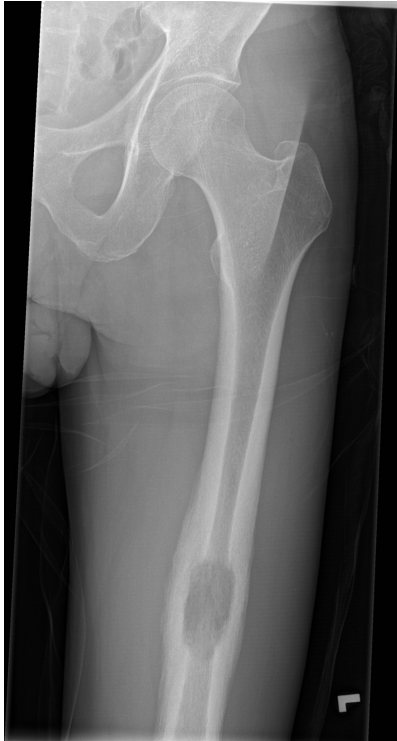- “SREs”
- Incidence varies based on primary cancer
- Defined as a skeletal lesion that requires or involves one of the following:
 - Pathologic fracture
 - Surgery for a bone lesion
 - Radiation of a symptomatic lesion
 - Spinal cord compression due to a lesion
- This is (for the most part) what we treat
- Most medical modalities (immunotherapy, bisphosphonates, etc) are aimed at preventing SREs



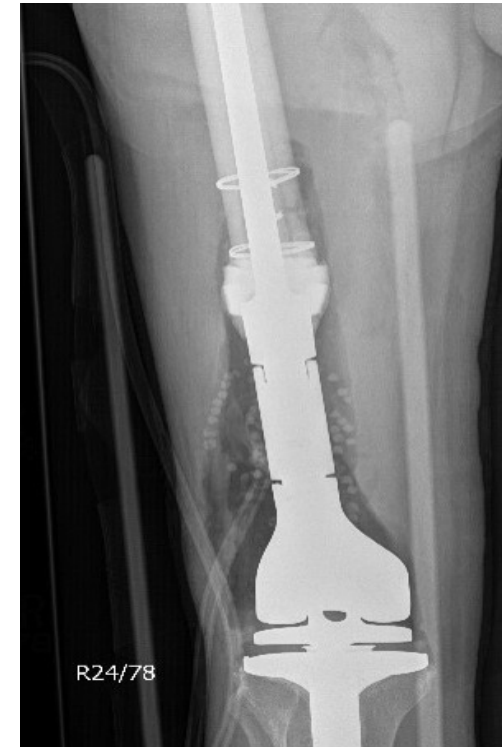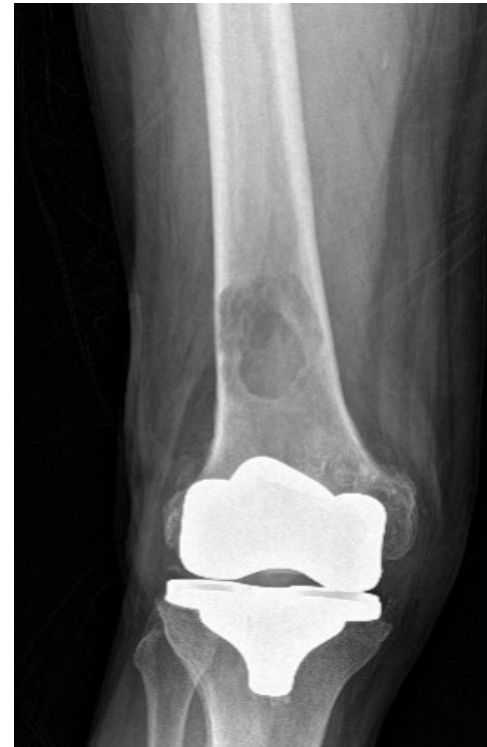How do you work up metastatic disease?

- Symptoms/signs:
 - Pain is most common symptom
 - Some present with completed fracture (often from no traumatic event)
 - Very helpful to take detailed history
- A lytic bone lesion in an adult needs further work-up
 - Most often is metastatic disease (especially age > 50 years) BUT:
 - Must rule out that lesion is **NOT a primary bone sarcoma (treatment paradigm usually necessitates wide resection)**

Metastatic Carcinoma



Sarcoma



Metastatic Bone Disease Work-Up

- Goal is determine primary site of malignancy
- Remember the most common malignancies that metastasize to bone and use diagnostic imaging/labs to target these
- Follow the algorithm- will generally find the primary malignancy in 85% of cases*

*Rougraff BT, Kneisl JS, Simon MA. Skeletal Metastases of Unknown Origin. A prospective study of diagnostic strategy. J Bone Joint Surg Am. 1993;75:1276-1281.

Metastatic Bone Disease Work-Up

1) History and Physical Examination

2) Labs:

- CBC and differential (**lymphoma**), metabolic panel, ESR/CRP (**infection**), Alkaline Phosphatase, SPEP (**myeloma**)

3) Imaging:

- Radiographs of the entire bone
- MRI with/without contrast
 - Not included in Rougraff's original study
 - BUT, helps to define marrow and soft tissue involvement of suspected lesion
- CT of chest/abdomen/pelvis (**lung, kidneys, breast, prostate**)
- Bone scan (sensitive, not specific)

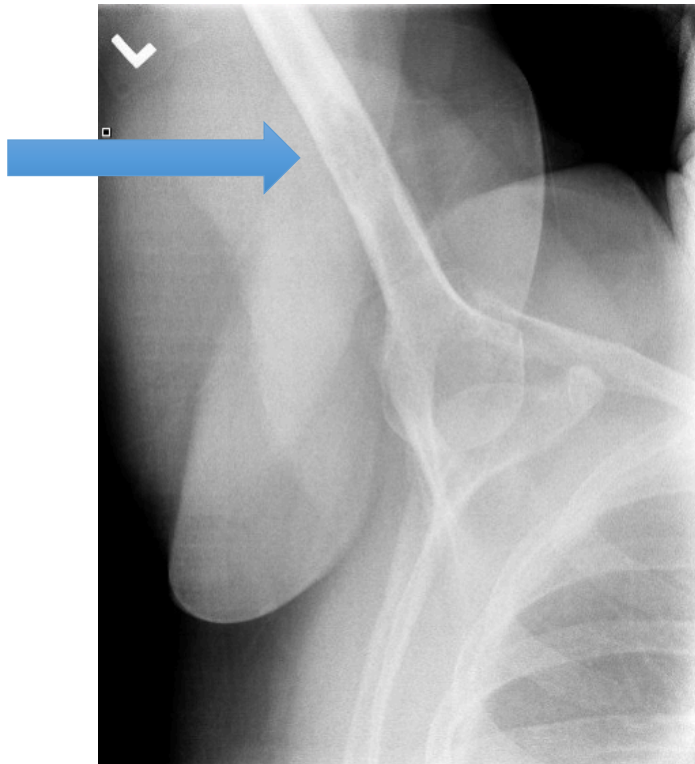
4) Biopsy

Work-Up: Finer Points on Imaging

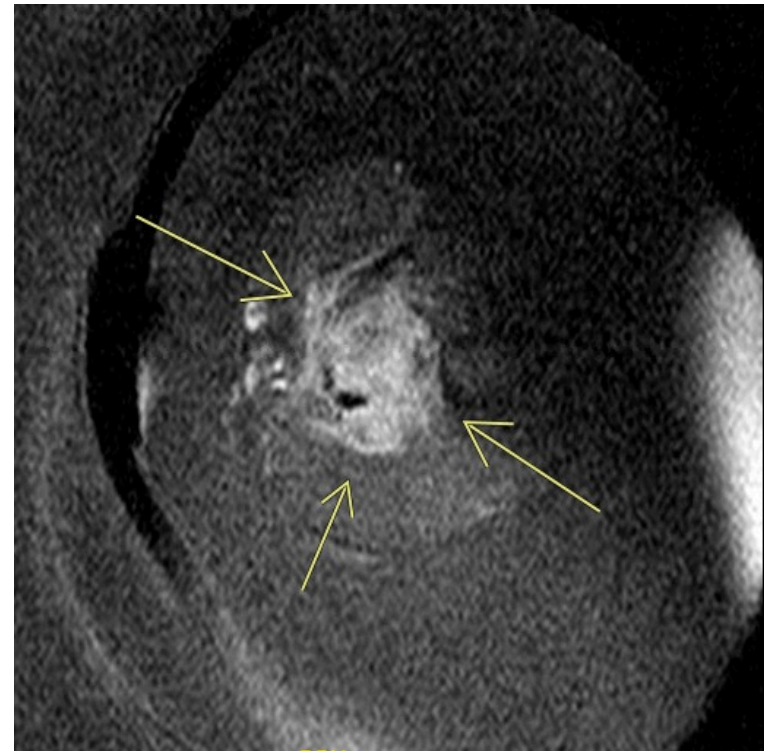
- Radiographs:
 - Examine in fine detail (associated soft tissue mass, cortical disruption, etc.)
 - Include entire bone to exclude presence of other lesions that may affect surgery

Radiographs

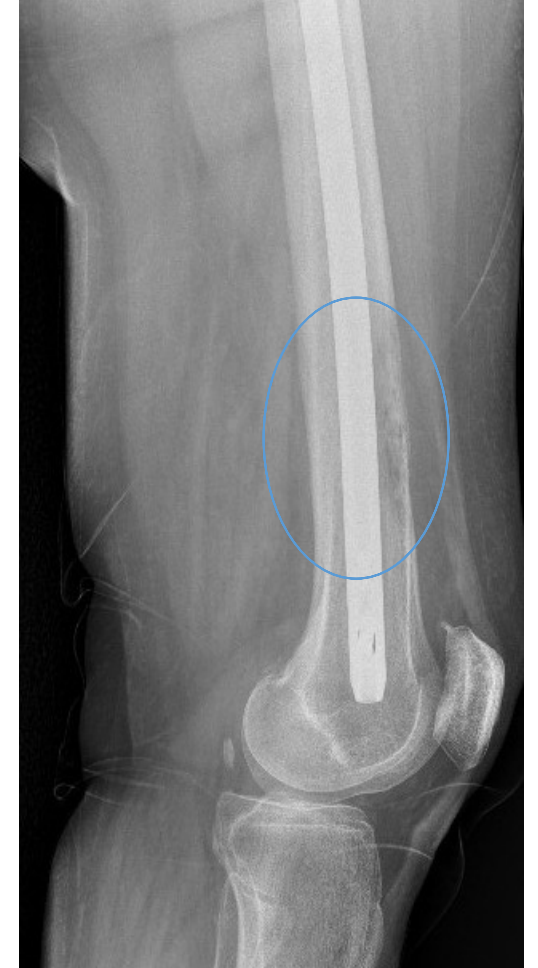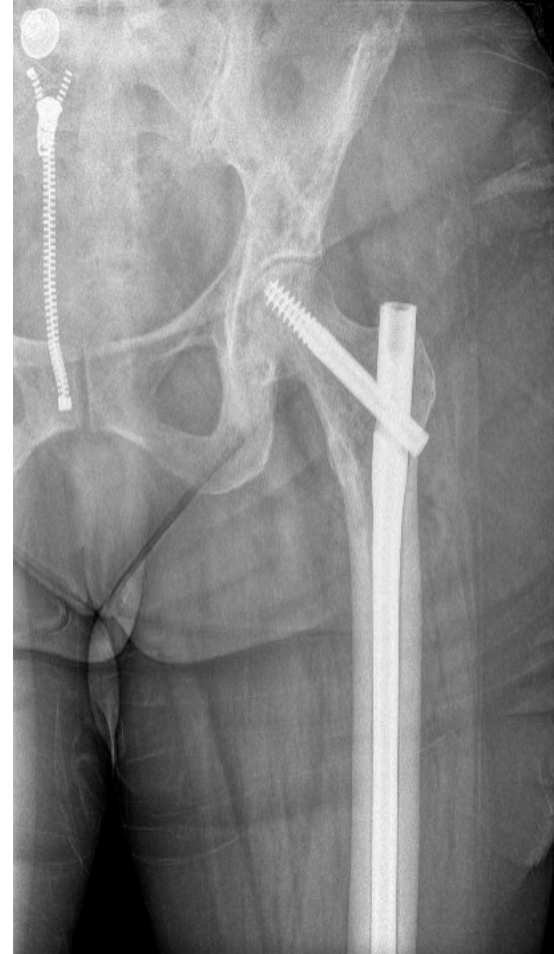
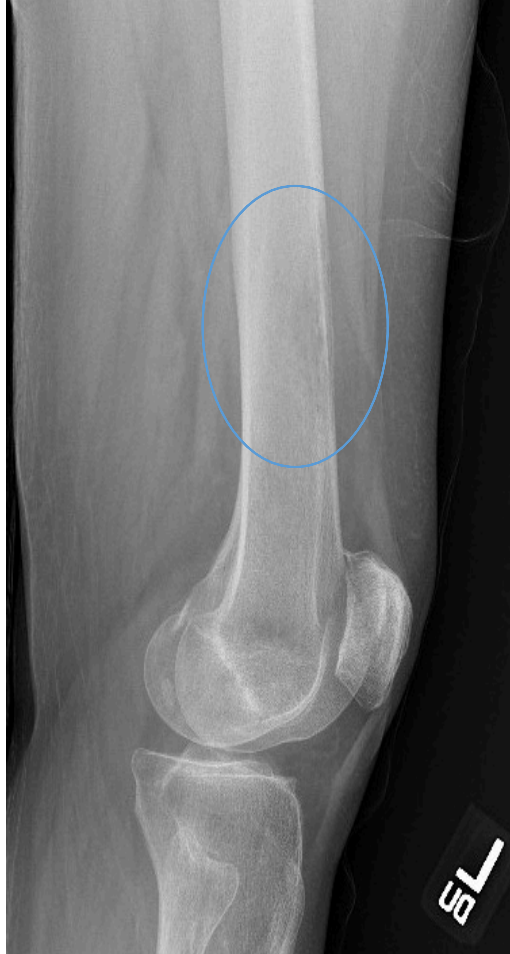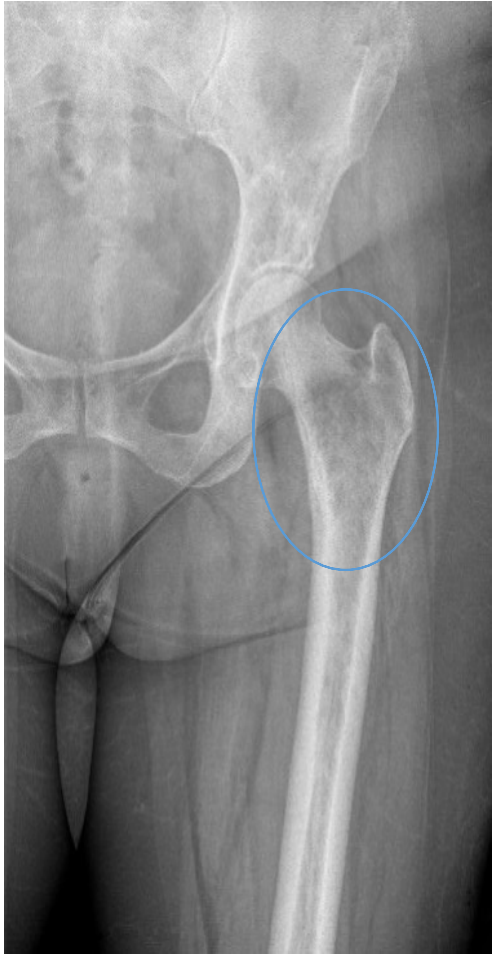- Intramedullary lesion with cortical disruption
- Originally only observed on axillary view of shoulder series)



Associated soft tissue mass visualized on MRI



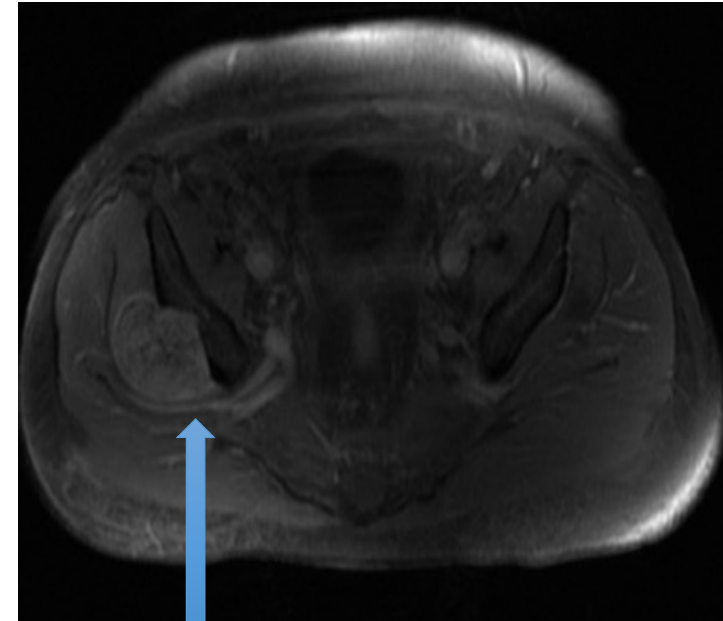
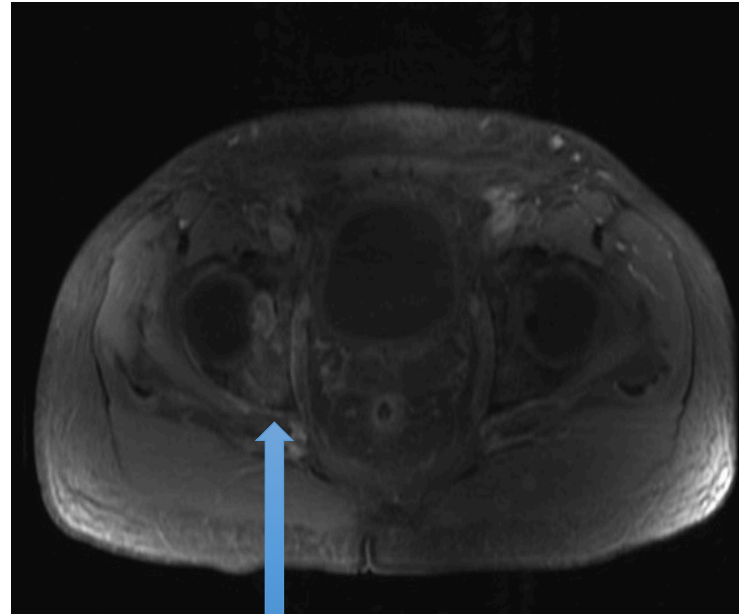
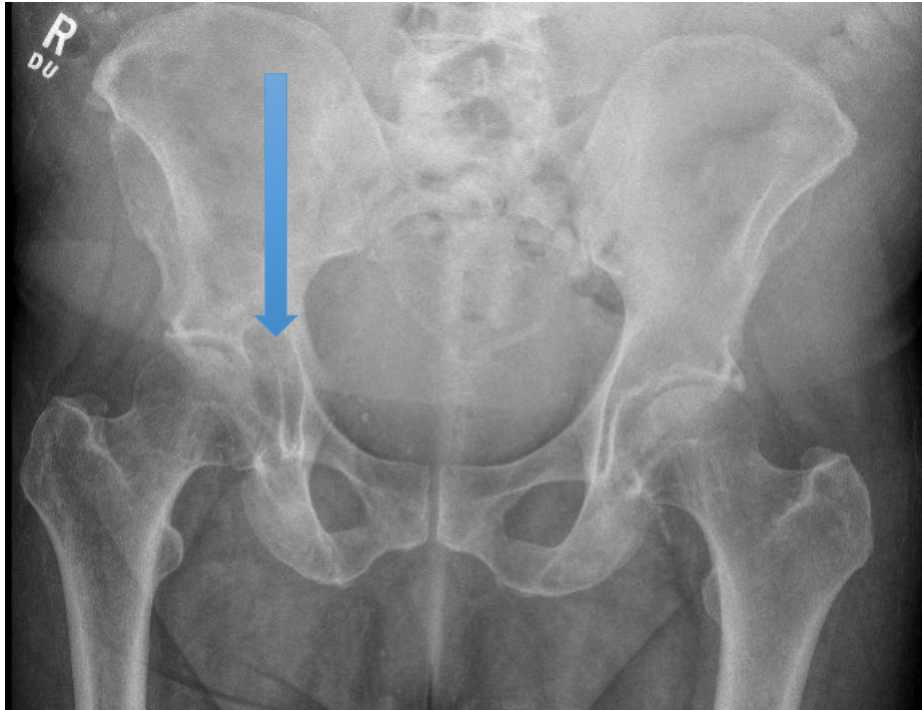
Full Length Radiographs



This patient was diagnosed with metastatic breast carcinoma. She had an impending pathologic intertrochanteric femur fracture. Full length radiographs also revealed the presence of a more distal lesion with cortical disruption.

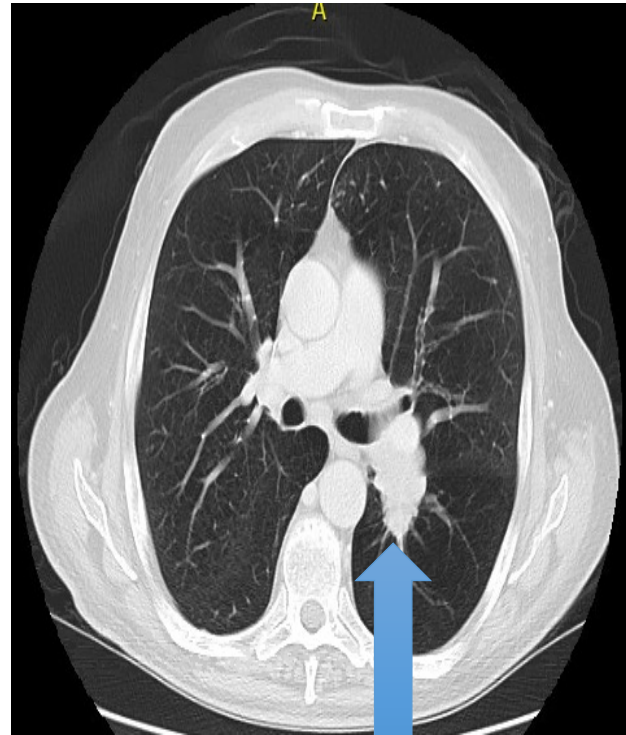
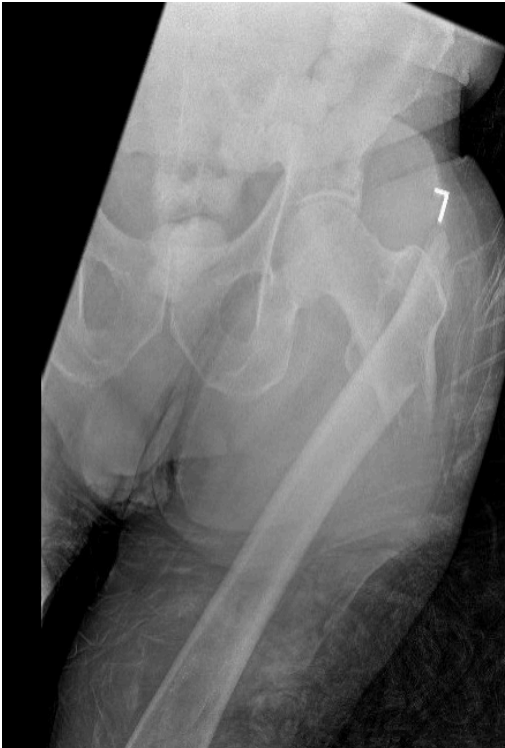Imaging-MRI (with contrast)

- Helps to delineate marrow or intraosseous extent of lesion
- Helps to delineate associated soft tissue mass as well as proximity to adjacent structures

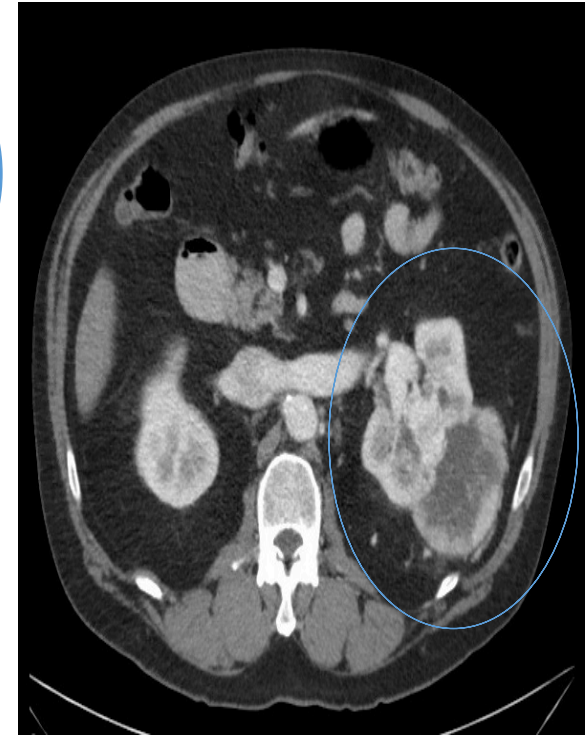
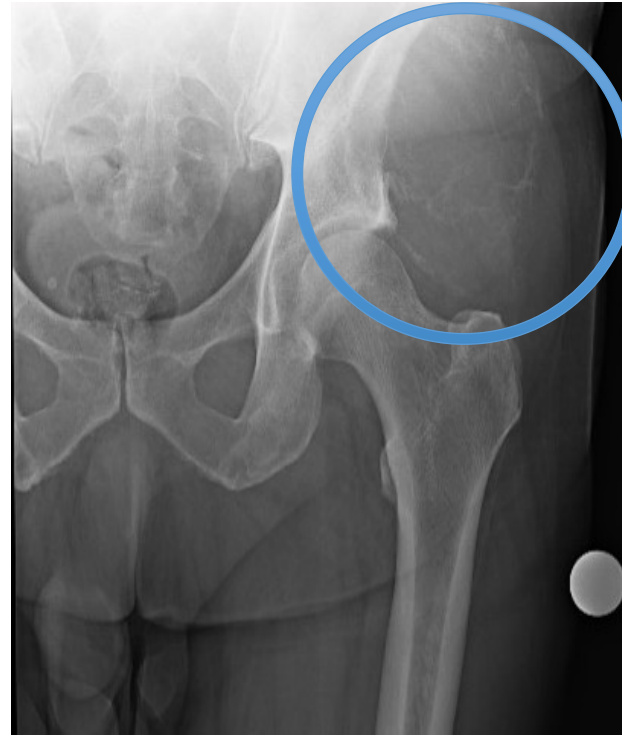
Imaging- CT Chest/Abdomen/Pelvis

Primary Lung Carcinoma



Primary Renal Carcinoma



Imaging- Bone Scan

- Sensitive, not specific (many different bony processes will be “hot” on bone scan)
 - Metastatic lesions
 - Arthritis
 - Stress fractures
- Detects **osteoblastic** activity; processes that are purely lytic may be missed (“cold” on bone scan)
 - Myeloma- **get skeletal survey instead**
 - Occasionally, lung carcinoma
- Utilities of a bone scan
 - 1) Help to detect presence of widespread disease
 - 2) Locate a more **accessible** lesion for biopsy (humerus versus acetabulum)

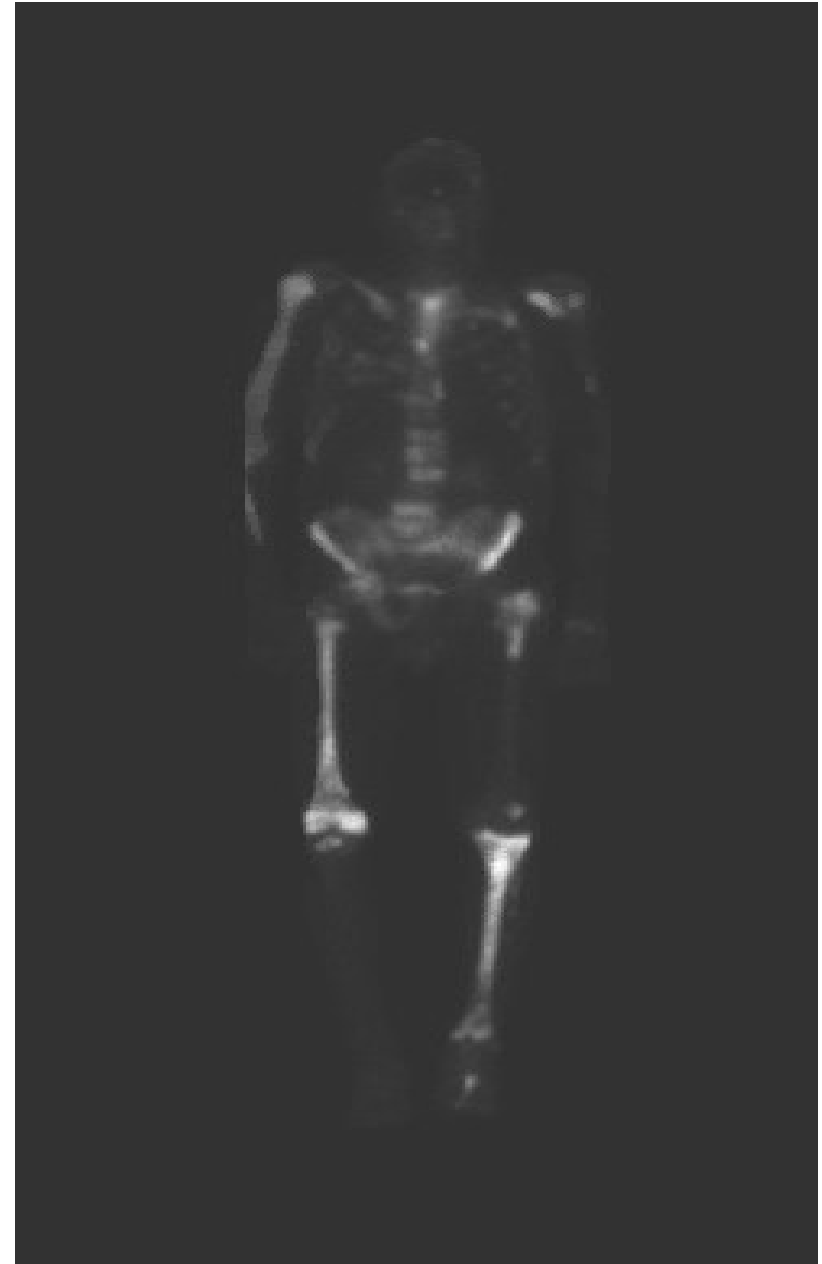
Bone Scan

Shows widespread bony involvement

This information can:

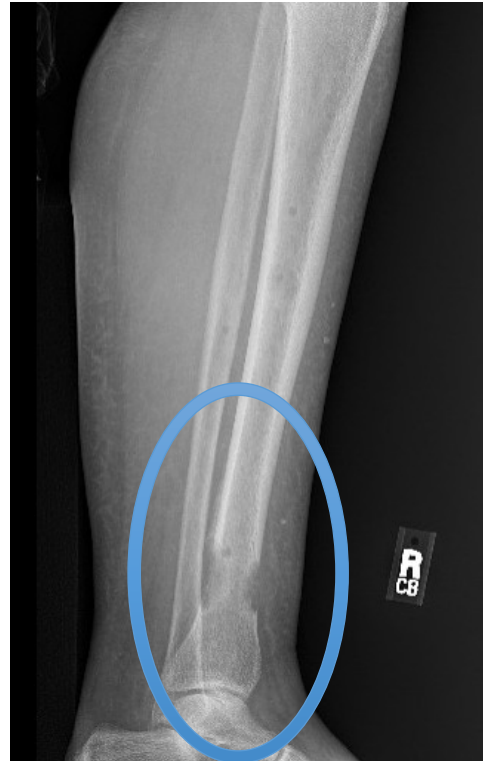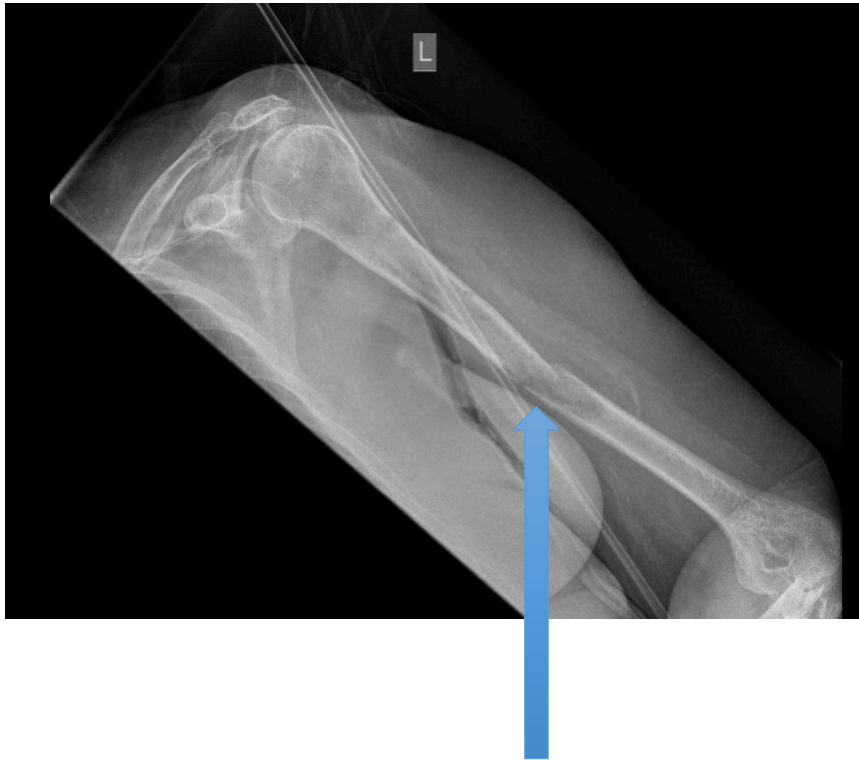- Help to target your biopsy site (pick the most accessible)

- Help with surgical decision making (widespread metastasis versus solitary site)

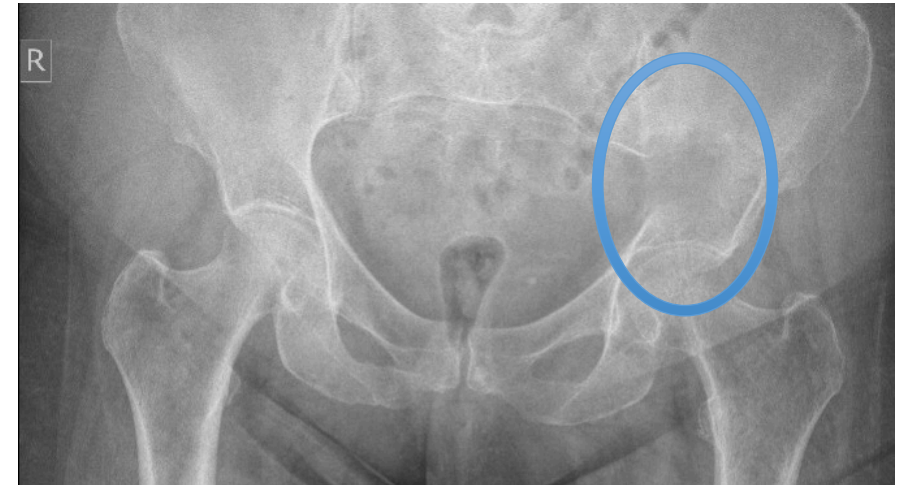


Skeletal Survey

- Useful for myeloma



Skeletal survey in this myeloma patient showed multiple lytic lesions with completed fracture or impending fracture

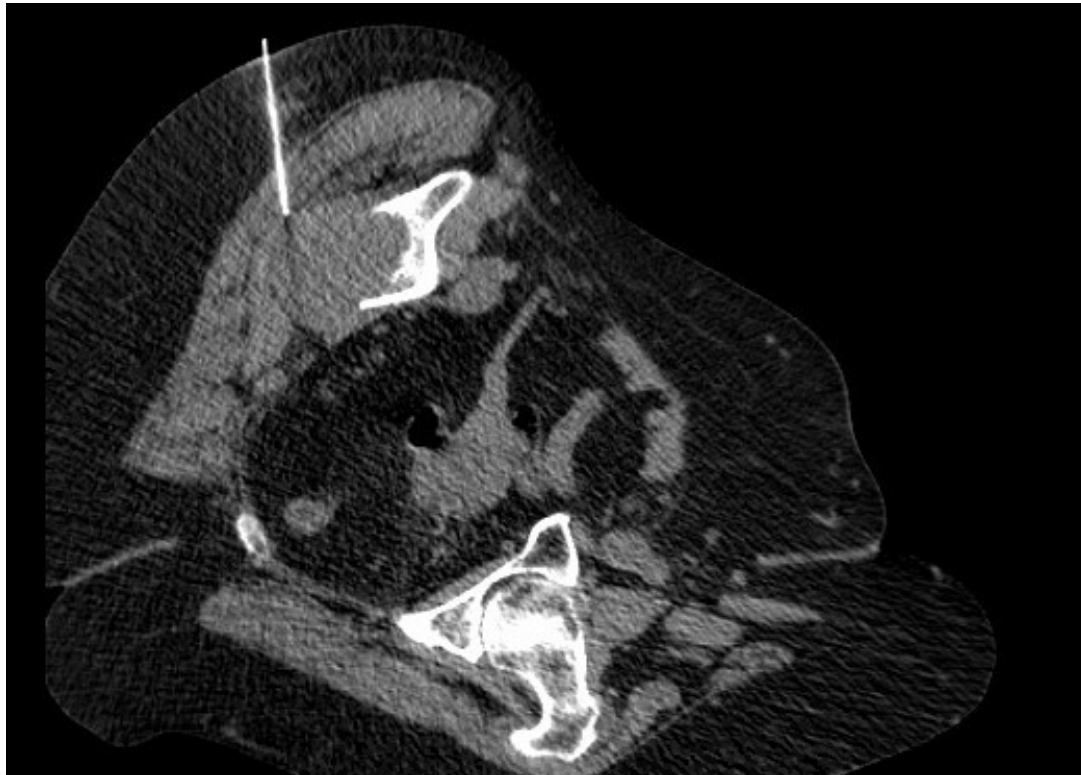


Work-Up: Biopsy

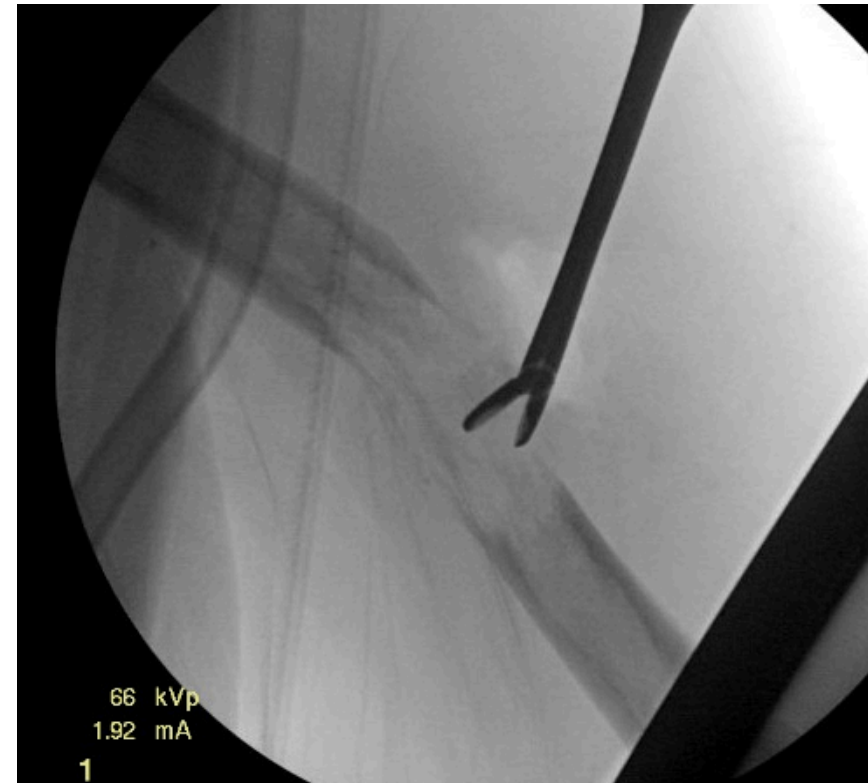- Usually the culmination of the aforementioned work-up
- A few options on how to perform this:
 - Imaged guided core needle biopsy- usually performed by radiologist with CT or ultrasound
 - Open biopsy (+/- frozen section)
- If performing open biopsy, adhere to the principles
 - Stay in one anatomic compartment, minimize contamination/hematoma, and make your incision in such a way that if a future resection is needed, this can be resected with the specimen (i.e. longitudinal incision on the extremities)

Biopsy

CT-guided core needle biopsy



Open Biopsy



Biopsy

- Send sample for:
 - Permanent pathology (in formalin)
 - Fresh pathology (not in formalin, allows for immunohistochemical testing for lymphoma, etc.)
 - Gram stain and culture
- Frozen section:
 - Useful to get a real-time diagnosis- biopsy is performed in the same setting as planned fixation/stabilization/reconstruction
 - Pathologist may not be able to give ultimate diagnosis, but will be able to tell you if carcinoma is present (proceed with planned surgery)
 - If there is any possibility that biopsy shows sarcoma- do not proceed with planned fixation/reconstruction and await final diagnosis

Now that we have a diagnosis...

Decision-Making in Osseous Metastatic Disease

- What is the risk of fracture and should we operate?
- Is there any role for non-operative treatment?
- What is the primary malignancy and what is the patient's prognosis?
- How can we accomplish our surgical goals (fixation versus reconstruction)?

How do we predict pathologic fracture?

- In patients with bony metastatic disease, we must ascertain whether the source of their pain is due to:

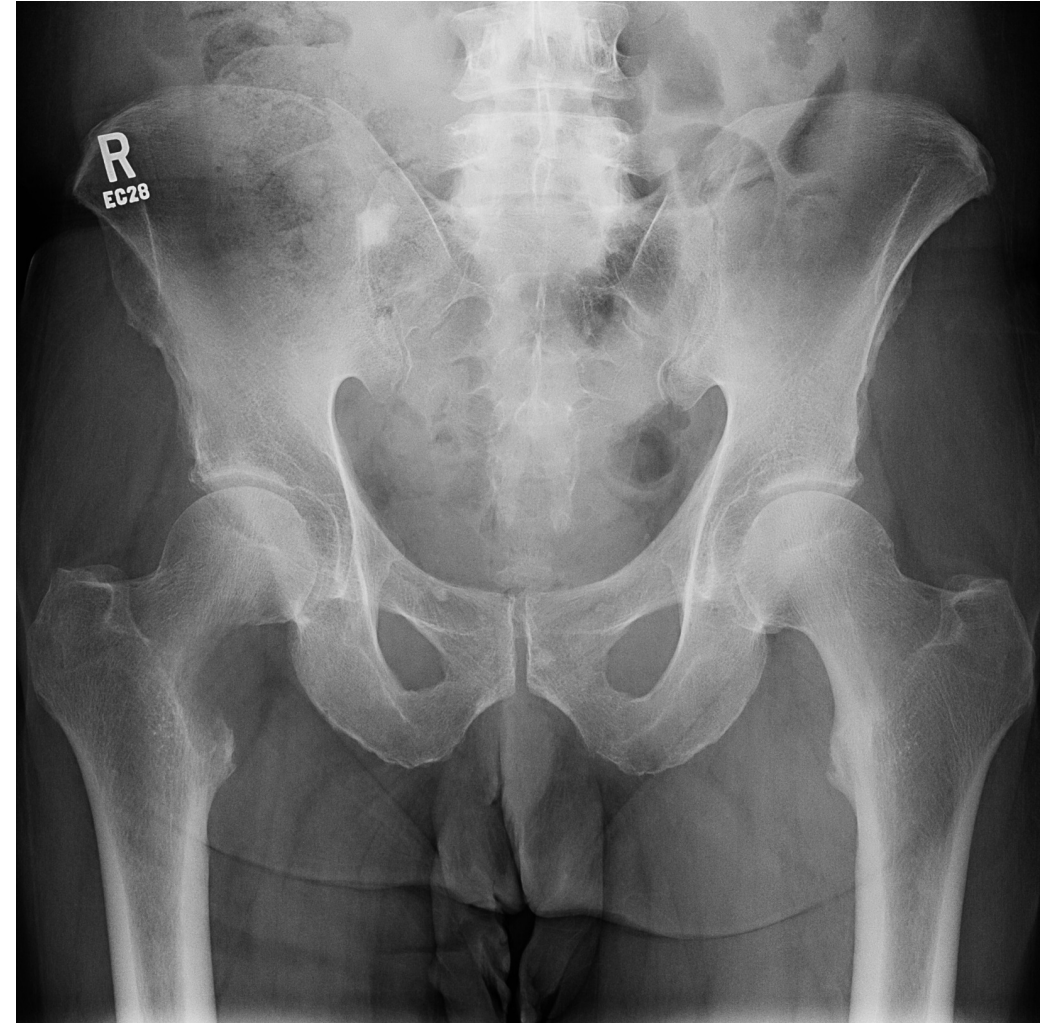-Impending fracture

OR:

-Bone turnover or tumor burden without impending fracture

Predicting Pathologic Fractures: Harrington Criteria

- Lesion is $>50\%$ of diameter of bone
 - Lesion is >2.5 cm in size
 - Persistent pain following radiation
 - Lesser trochanter fracture/avulsion
-
- But:
 - This classification accounts only for the proximal femur
 - Does not take into account primary tumor subtype



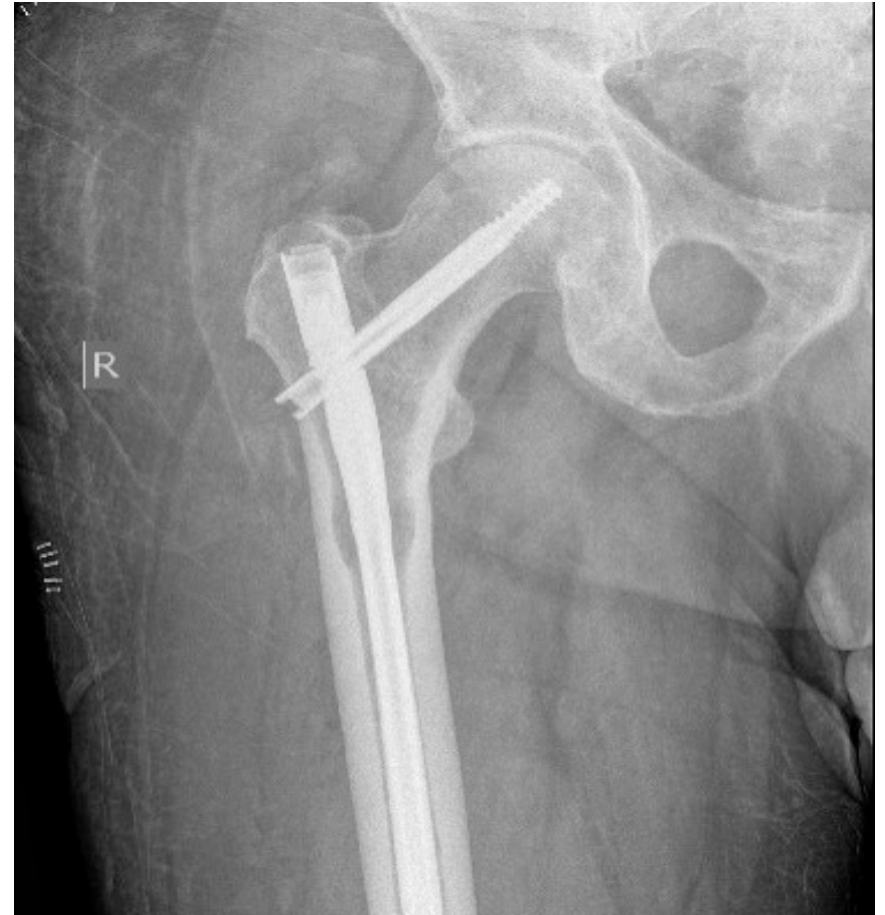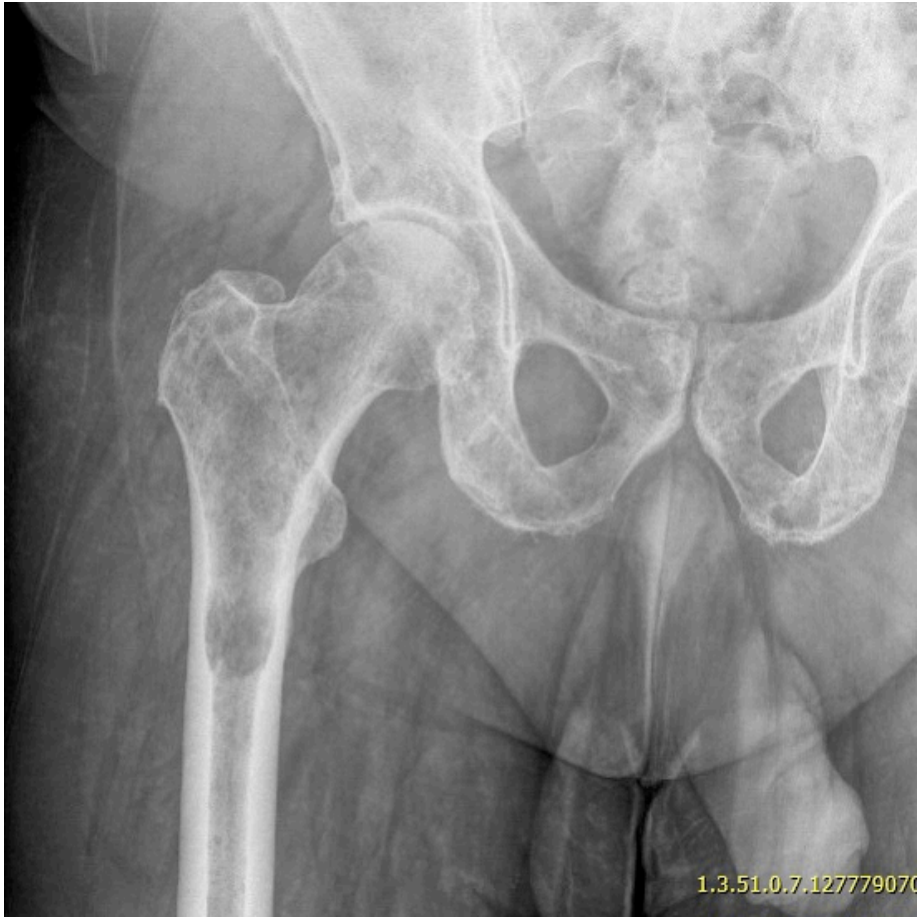
Predicating Pathologic Fractures: Mirel's Scoring

	Score		
	1	2	3
Site	Upper extremity	Lower Extremity	Peritrochanteric Area
Pain	Mild	Moderate	Functional/Pain at rest
Lesion type	Blastic	Mixed	Lytic
Size	< 1/3 bone diameter	1/3 – 2/3 diameter	> 2/3 diameter

Score > 8 usually portends prophylactic fixation

May lead to small degree of overtreatment as false positive rate is ~6 %

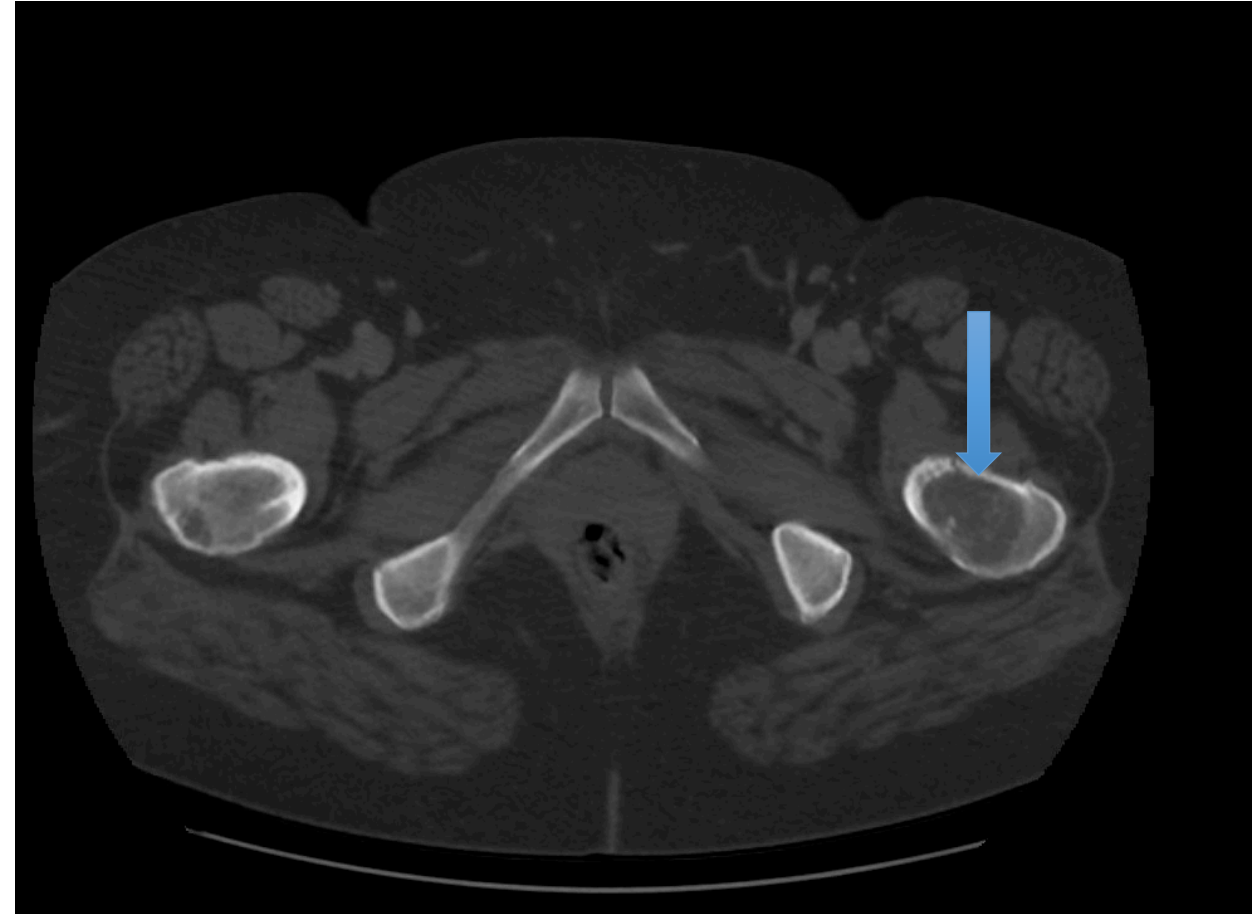
Mirels, H. CORR, 1989.



Site	Peritrochanteric femur	3 points
Pain	Moderate	2 points
Lesion type	Lytic	3 points
Size	>2/3 Diameter	<u>3 points</u>
		11 points

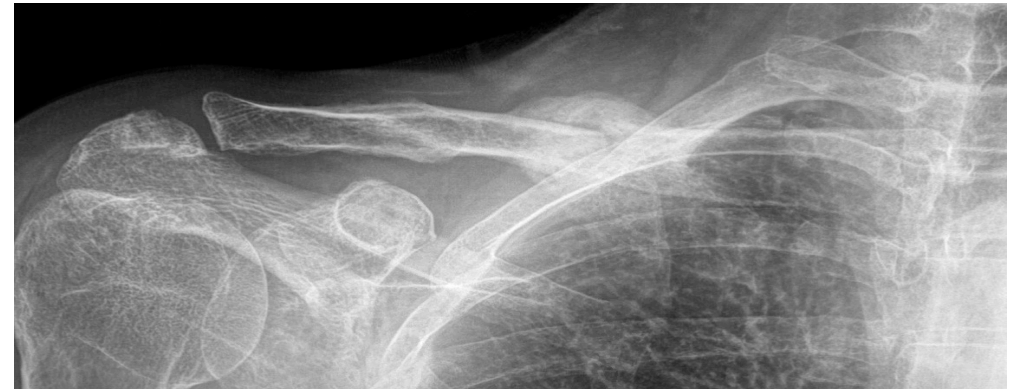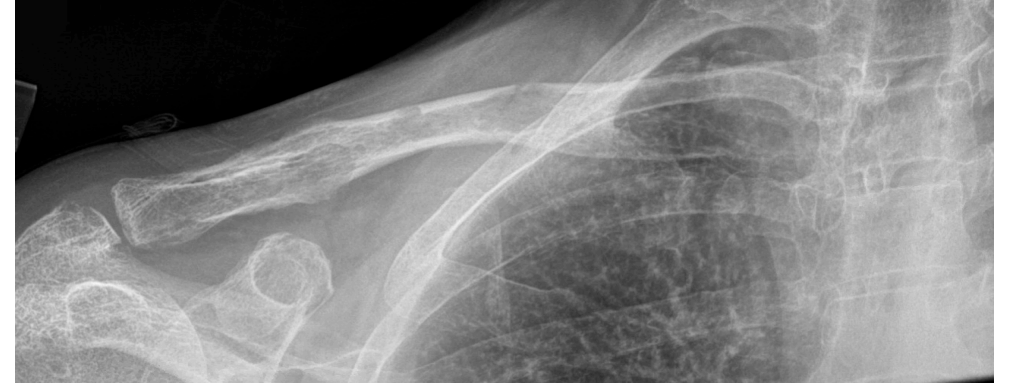
Predicting Pathologic Fractures: CTRA

- CT-Based Structural Rigidity Analysis (CTRA)
- Utilizes CT to quantify degree of bony involvement as compared to contralateral side or normal-matched controls
- Using 35% reduction in bony rigidity as threshold, CTRA showed improved sensitivity and specificity as compared to Mirel's threshold of > 8 points for risk of impending fracture



Non-Operative Treatment

- As orthopedic surgeons, we must help to decipher if a patient's pain is from tumor burden/bone turnover without risk of fracture VERSUS mechanical pain from impending fracture
- If risk of fracture is low (or if fracture can be treated non-operatively), non-operative modalities may be used for palliation

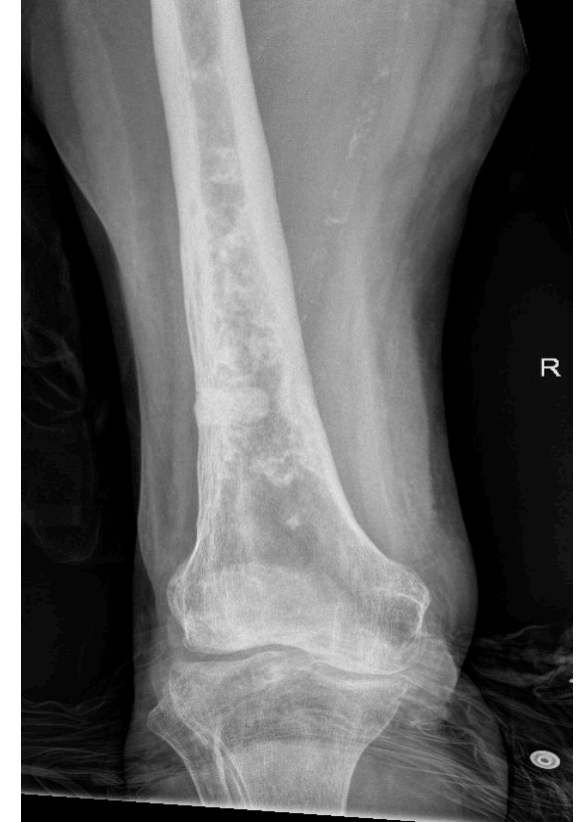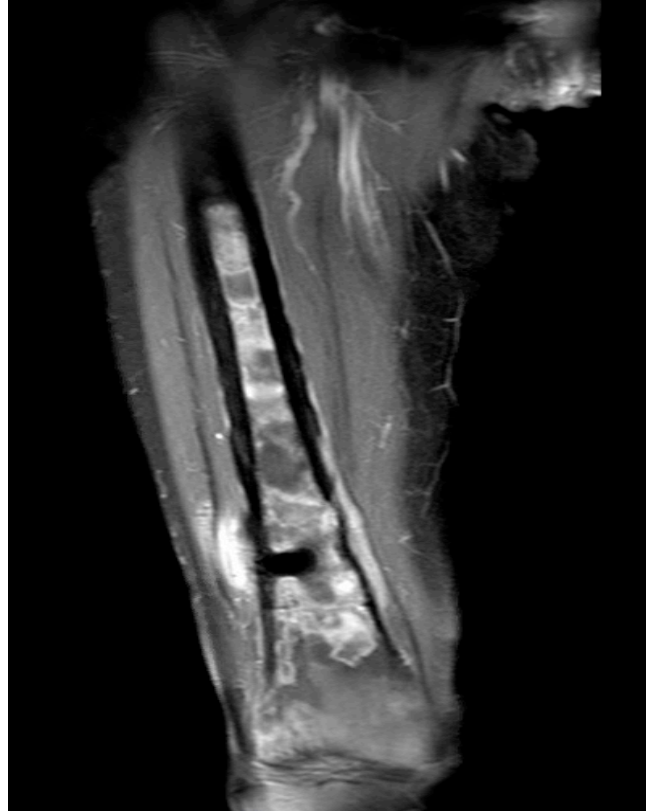

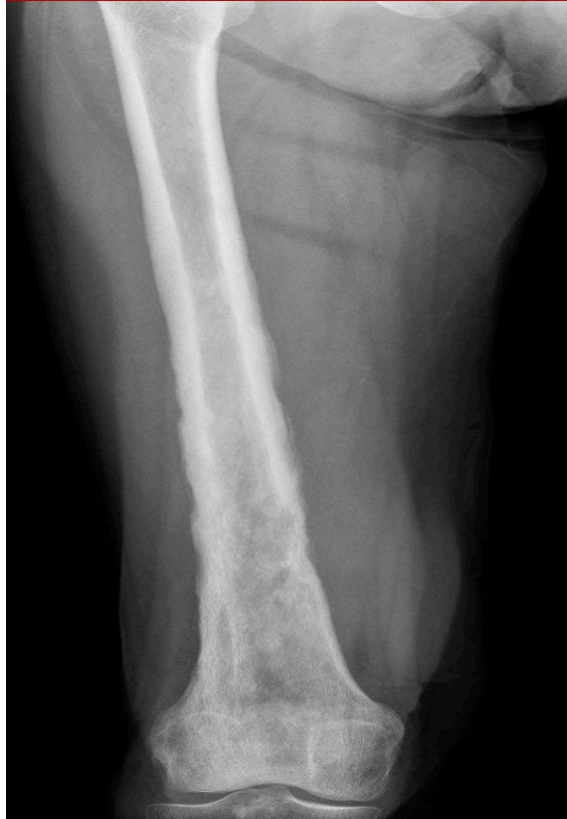
Myeloma patient with multiple punctate lesion at the clavicle. Given location and myeloma diagnosis, these lesions (and fracture) were amenable to non-operative treatment and responded well to the patient's myeloma medical treatments

Non-Operative Treatment

- Non-operative modalities:
 - Chemotherapy/immunotherapy, etc. directed at primary diagnosis
 - Lesions from myeloma/lymphoma tend to reconstitute well after primary treatment initiated
 - Bisphosphonates or Denosumab
 - Radiation therapy (XRT)
 - Percutaneous radiofrequency ablation (RFA) or cryoablation

Non-Operative Treatment



This is a lymphoma patient. Radiograph (left) and MRI (center) obtained at presentation. Post-treatment radiograph (right) shown following initiation of systemic medical therapy and XRT; note the cortical reconstitution (cement plug seen at lateral cortex at site of biopsy). Frequently, in the setting in lymphoma, our role as surgeons is usually limited to tissue sampling, as this diagnosis responds well to medical/XRT treatments.

Non-Operative Treatment

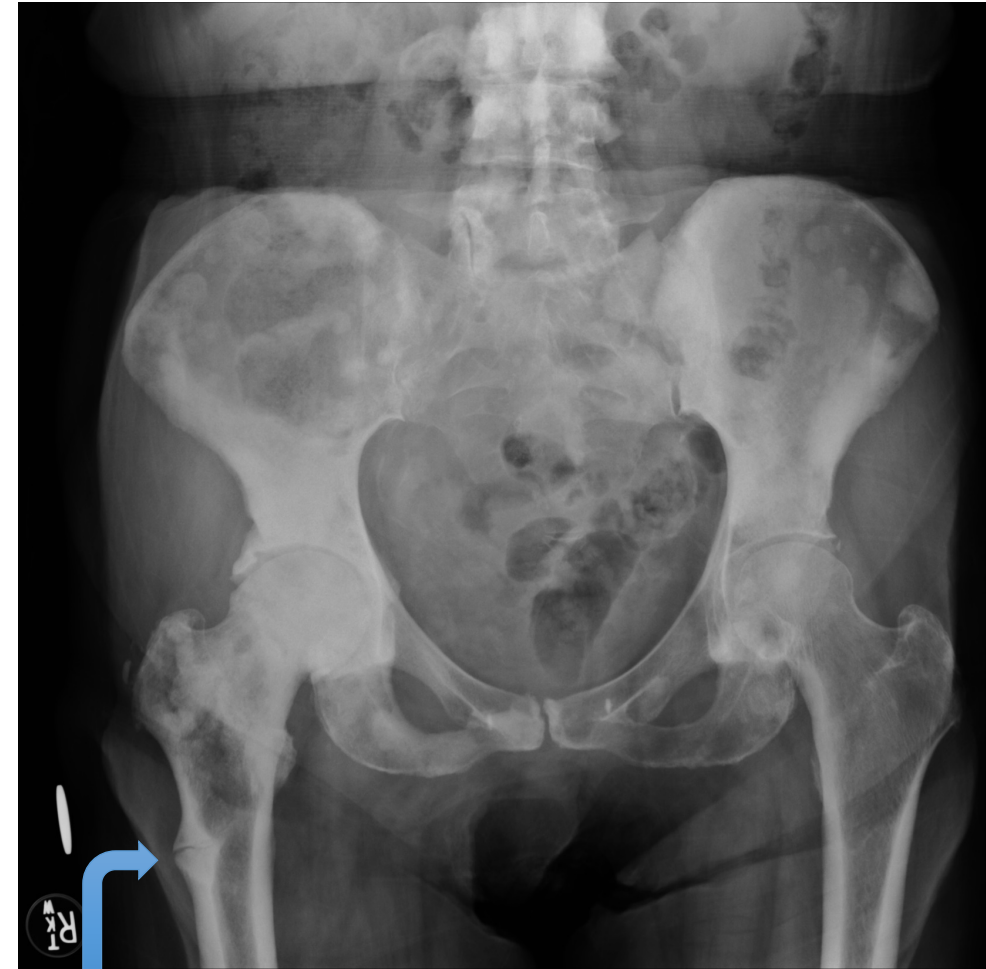- Bone-targeted medications
 - Aimed at decreasing Skeletal-Related Events (SREs)

1) Bisphosphonates

- Can also aid in treatment of malignant hypercalcemia (along with fluid hydration)
- Be aware of atypical subtrochanteric fractures

2) Denosumab

- Monoclonal antibody that competitively inhibits osteoclast binding to receptor activator nuclear factor (RANK) to RANKL
- At least equivalent to bisphosphonates in decreasing SREs with possibly fewer complications

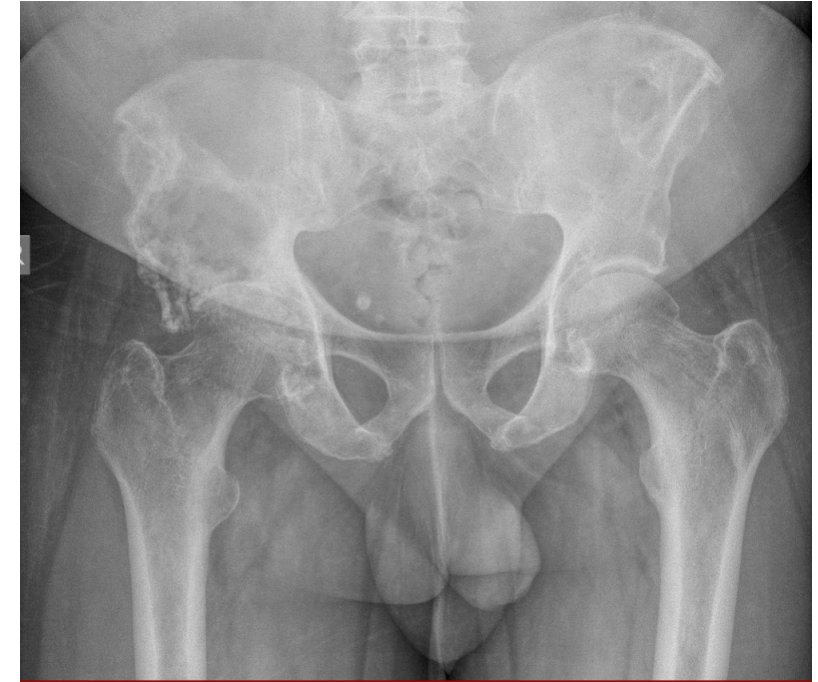
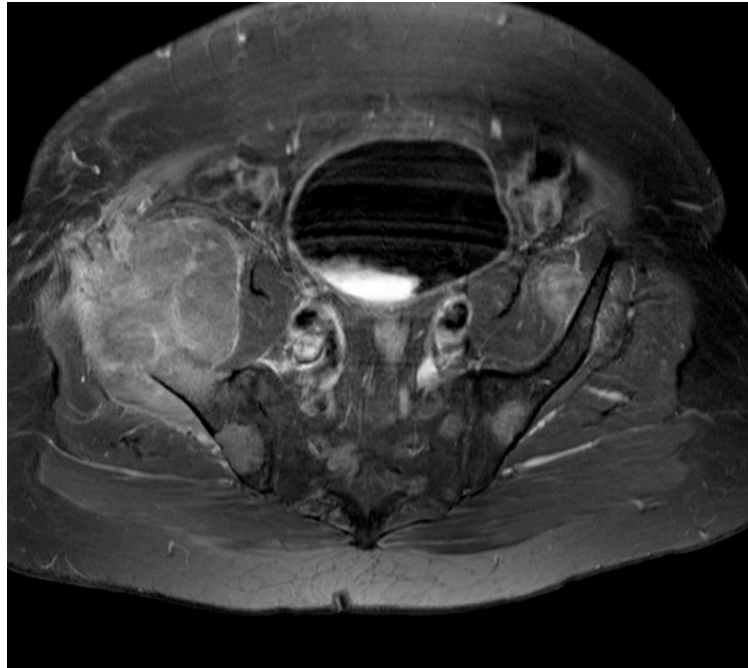
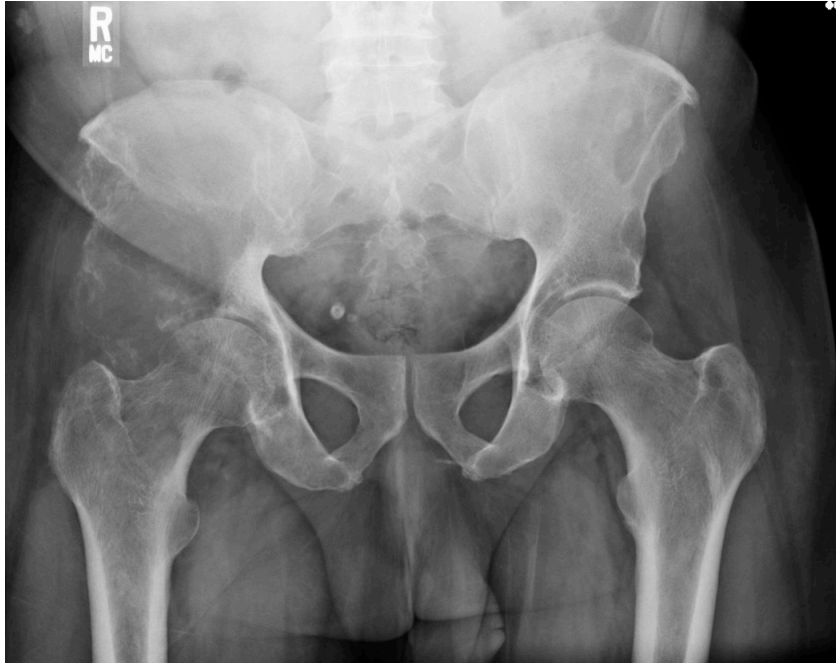


Atypical femur fracture in the setting of metastatic disease

Non-Operative Treatment

- Radiation Therapy (XRT)
 - Useful in treatment of painful metastases
 - Can be given as single fracture or multiple fractions (equivalent pain relief)
 - 90% of patients will get some degree of pain relief
 - Radiation-induced fractures are dose dependent
 - Increased dose of radiation = increased chance of fracture
 - These fracture are difficult as healing potential is low

Non-Operative Treatment (XRT)

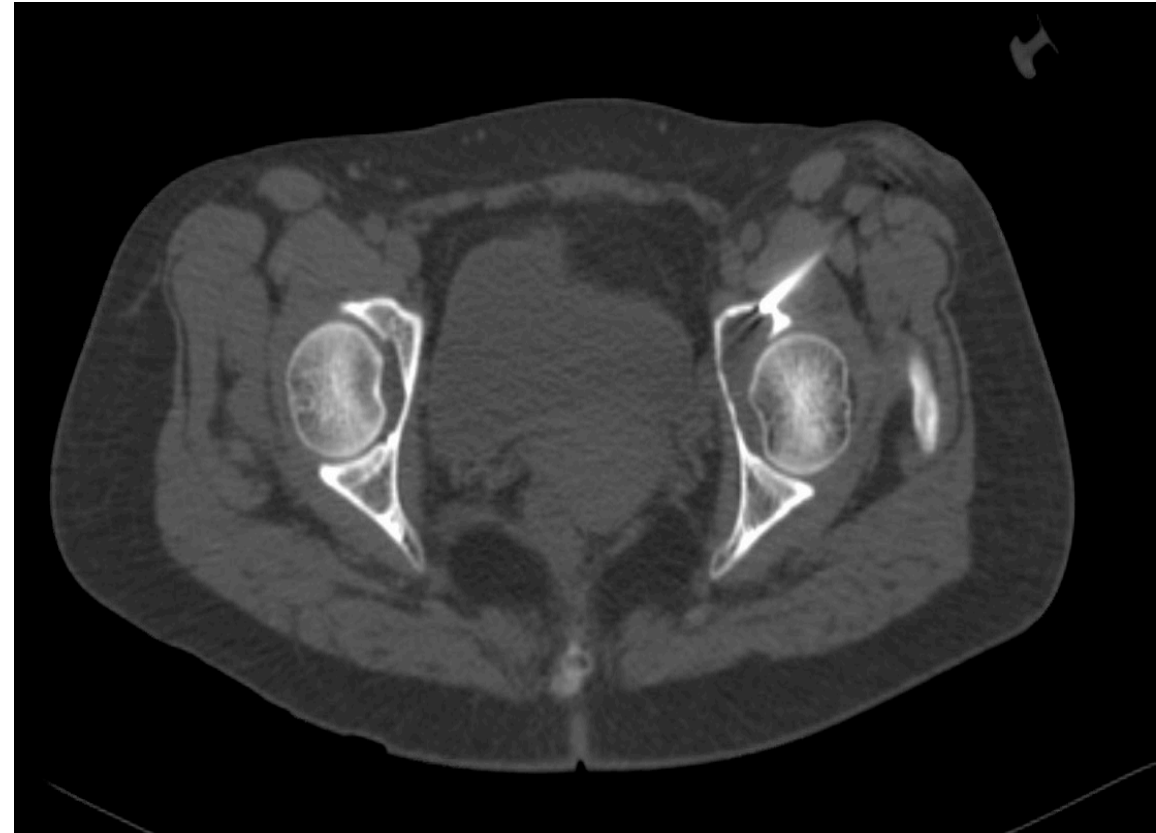


72 year old male that presented with right hip pain and a right femoral nerve palsy. Radiograph (left) and MRI (center) at presentation showed a large right periacetabular bone lesion and associated soft tissue mass. Work-up ultimately revealed metastatic prostate cancer. Given degree of soft-tissue involvement and the fact that this was a prostate primary (radiosensitive), he was given neoadjuvant XRT knowing that he may require reconstruction if this failed. Follow-up radiograph (right) showed marked reconstitution of periacetabular bone and his joint integrity was maintained.

Non-Operative Treatment

Percutaneous ablation (radiofrequency or cryoablation)

- Can be used for palliation or local tumor control
- Relatively non-invasive and may be useful for axial locations that may require extensive surgical approach (pelvis)
- Shown to be efficacious in renal cell carcinoma



Cryoablation probe introduced under CT-guidance

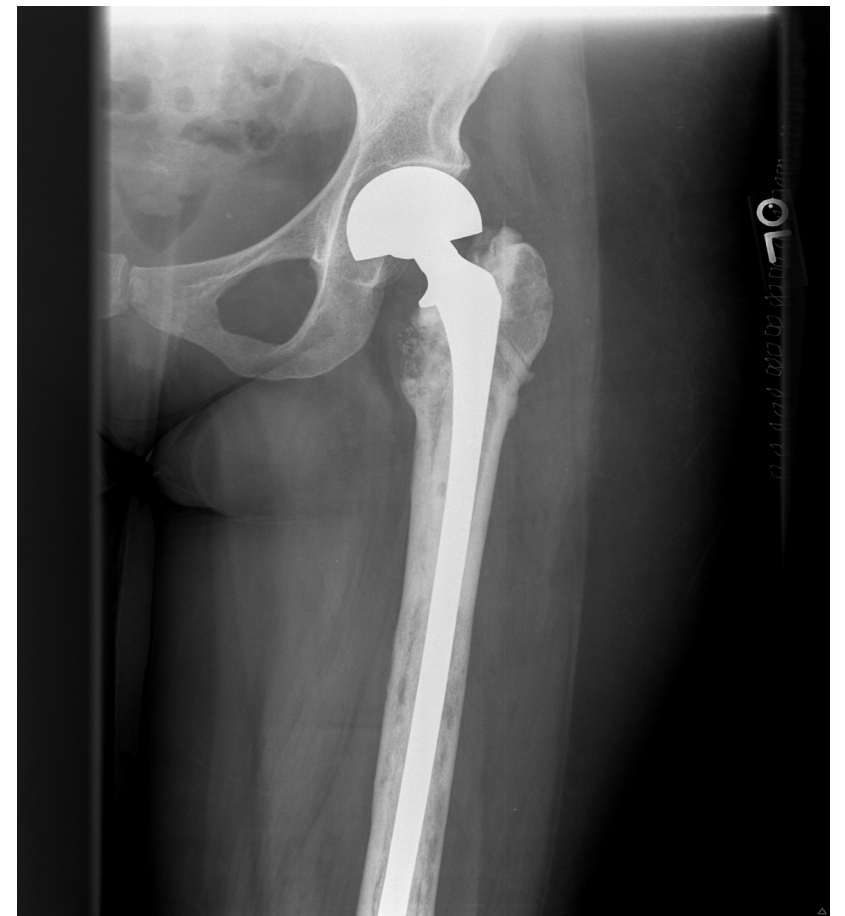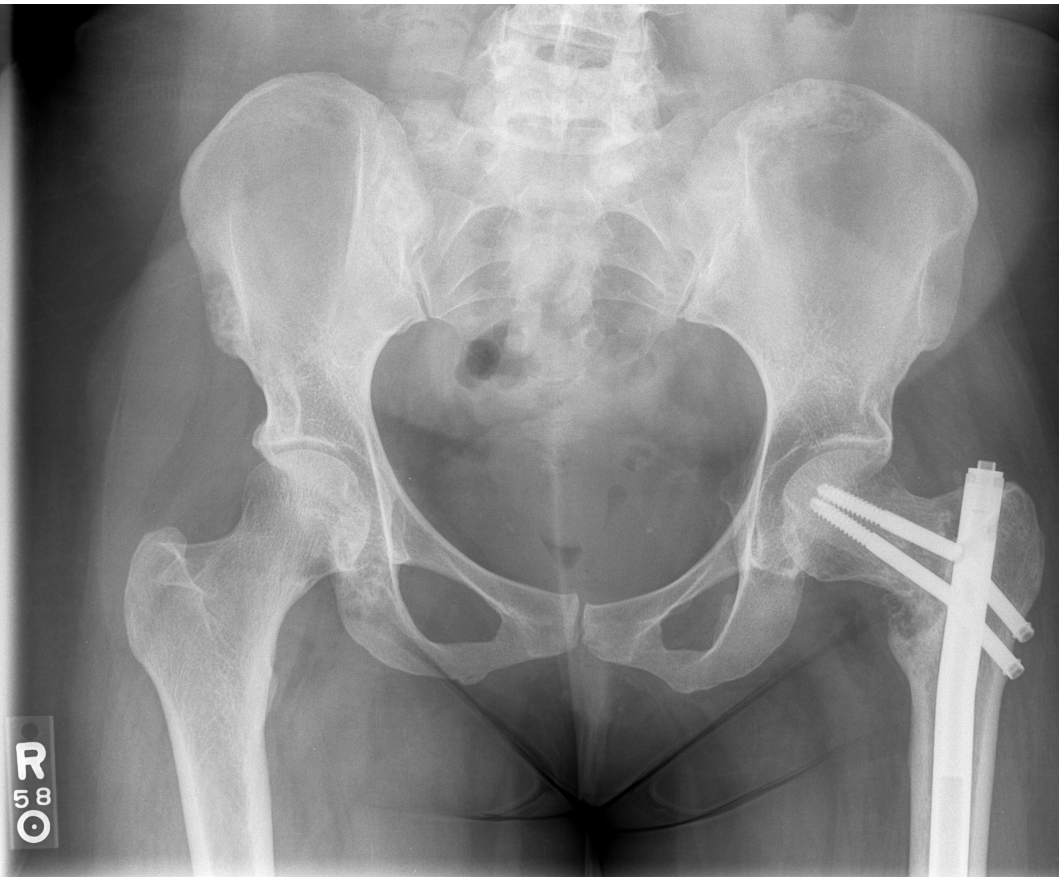Gardner et al. JBJS. 2017

Prognosis and Life Expectancy

- With the advent of biologics and immunotherapy, metastatic carcinoma patients are realizing increased life expectancy
- Many patients may survive several years after diagnosis (or surgery)
 - Be prepared to follow these patients; as survival increases, so does the chance of implant failure or re-operation
- Orthopedic surgeons must keep this improved prognosis in mind when planning durable fixation or reconstruction

Gutowksi et al. Surgical Management of Femoral Metastase in the Era of Biologics: A Shifting Paradigm. MSTs Annual Meeting Abstract 2017.





This is a patient with a pathologic pertrochanteric femur fracture from metastatic breast carcinoma. With follow-up, she was noted to have non-union at the fracture and construct failure. They were converted to arthroplasty to maintain function and mobility

Predicting Survival

- Most often requires consultation with Medical Oncology or other services
- Other variables include response to treatment, function level, etc.
- Oligometastatic (less than 5 sites of disease) versus widespread metastatic disease
- Synchronous versus metachronous skeletal metastatic disease

Predicting Survival: PathFx

- PathFx^{3.0}

www.pathfx.org

- Online- based tool
- Allows for the input of clinical and patient-specific variables
- Generates likelihood at survival at several time-points
- May aid in decision-making regarding extent of planned surgery



Anderson AB et al. CORR. 2019

Core Curriculum V5

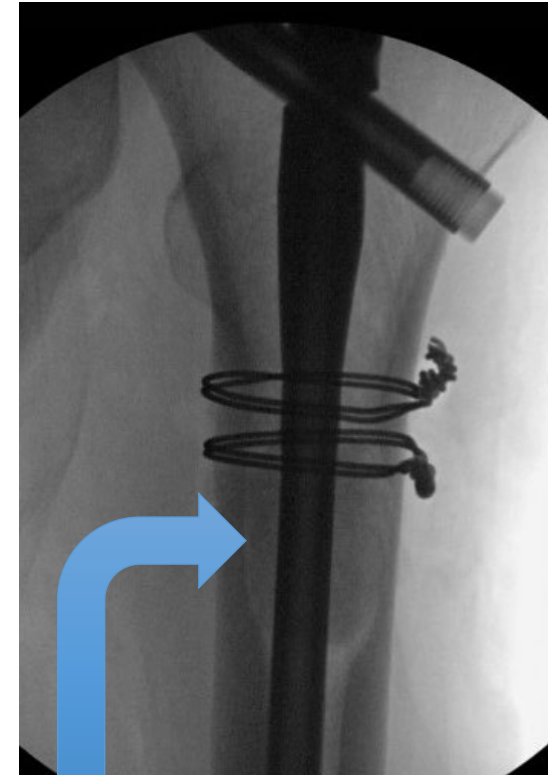
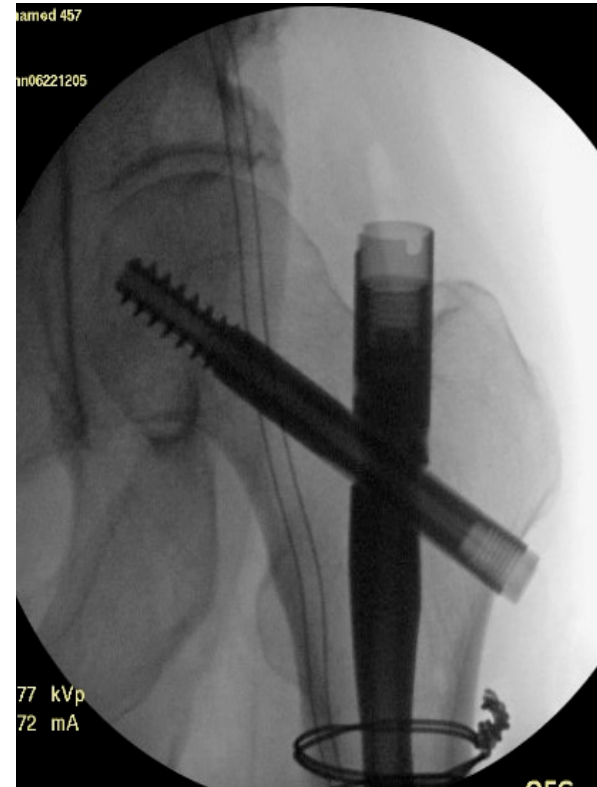
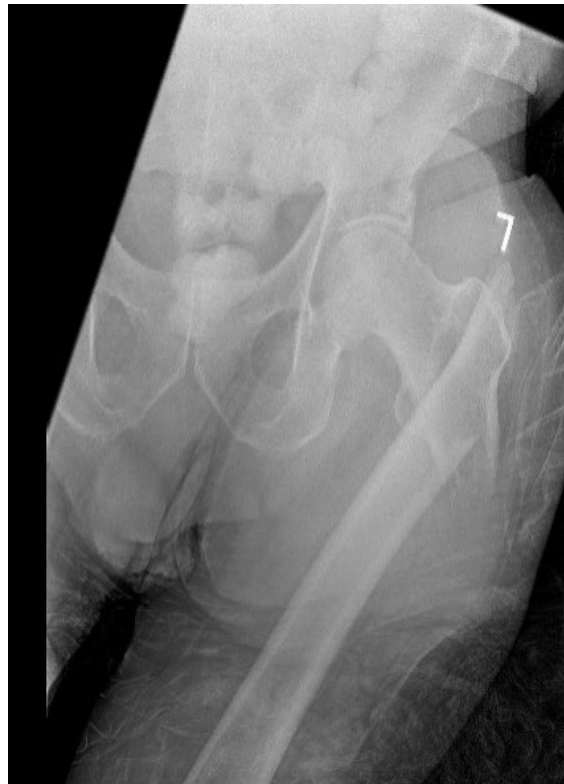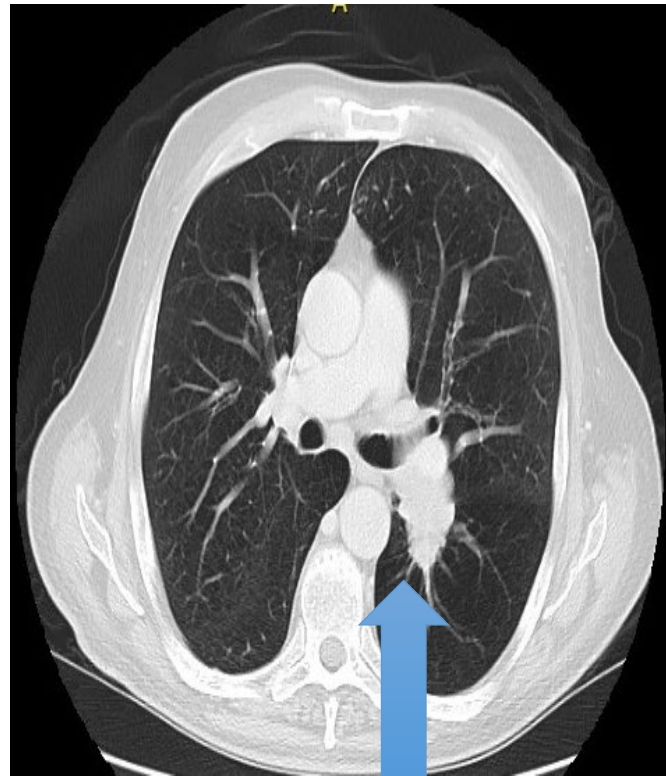
Disease Specific Considerations

- Each primary malignancy has some idiosyncrasies that will likely play a role in orthopedic treatment
- Each subtype has different prognosis/survival, fracture healing potential, sensitivity to medical or radiation treatments
- These patients are hypercoagulable and at ~8x greater risk of sustaining a venous thromboembolic event (VTE)
 - Must consider VTE prophylaxis

Metastatic Lung Carcinoma

- Traditionally, poor prognosis, but improved in recent years (especially in patients with PD-1 mutation that can be targeted with immunotherapy)
- Usually lytic appearance on radiographs (may be “cold” on bone scan) and often cortically-based
- Low propensity for fracture healing; sensitive to radiation
- Frequently requires fixation adjuncts (PMMA, etc) when performing fixation due to bone loss and decreased chance of bony healing or reconstitution

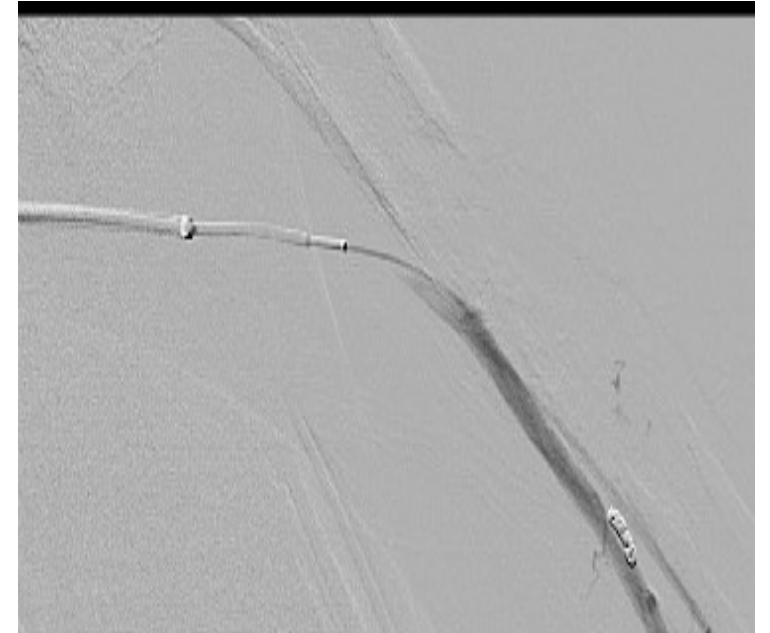
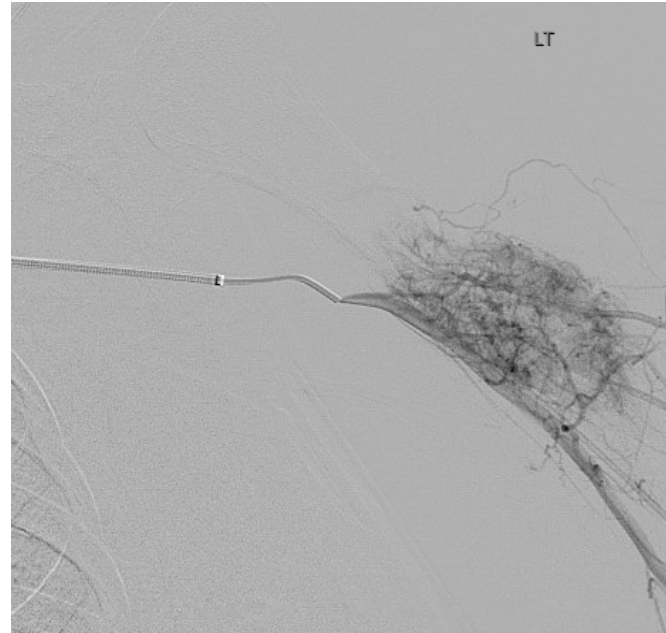
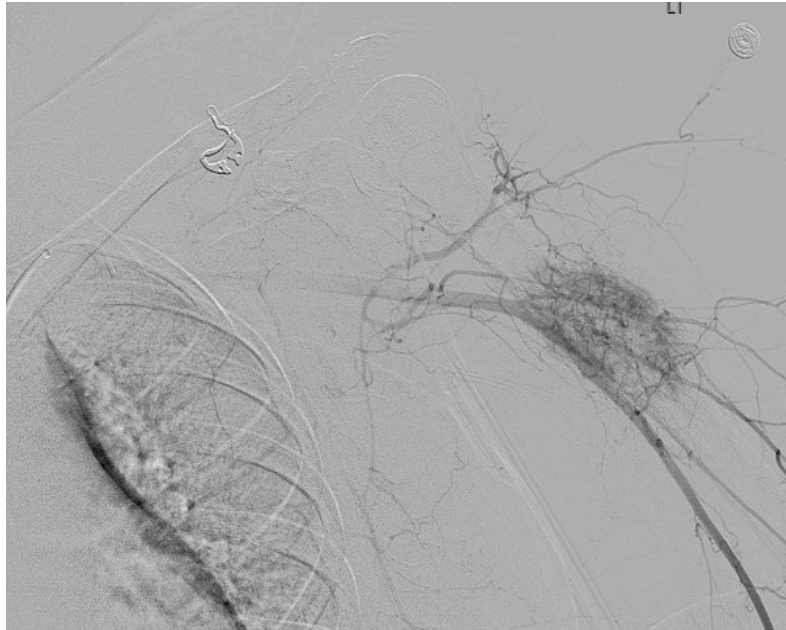
Metastatic Lung Carcinoma



Metastatic Renal Cell Carcinoma

- A few points:
 - Resistant/low sensitivity to radiation
 - Vascular tumors: always consider pre-operative embolization (especially when planning an intralesional procedure)
 - Some may consider wide resection/reconstruction of metastatic lesion in setting of oligometastatic disease (i.e. only a few sites of disease)
 - Local tumor progression is a real possibility following intralesional procedures

Embolization



Renal Cell: When to Resect?

- One may consider metastectomy or resection/reconstruction in certain situations:
 - Oligometastatic disease- resection of all sites of disease may portend a survival benefit
 - Peri-articular location
 - Chance of local tumor progression or need for re-operation due to construct failure is high
 - Remember that metastatic RCC is radioresistant; therefore, we cannot always rely on postoperative radiation to inhibit tumor progression following an intralesional procedure

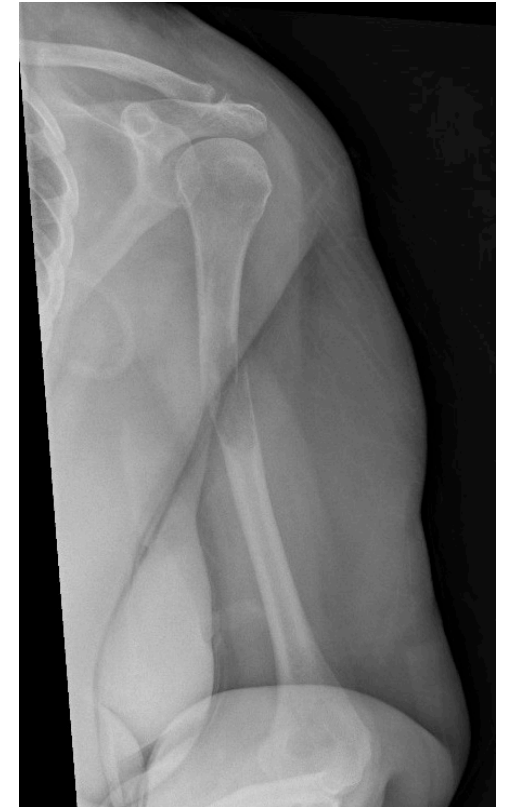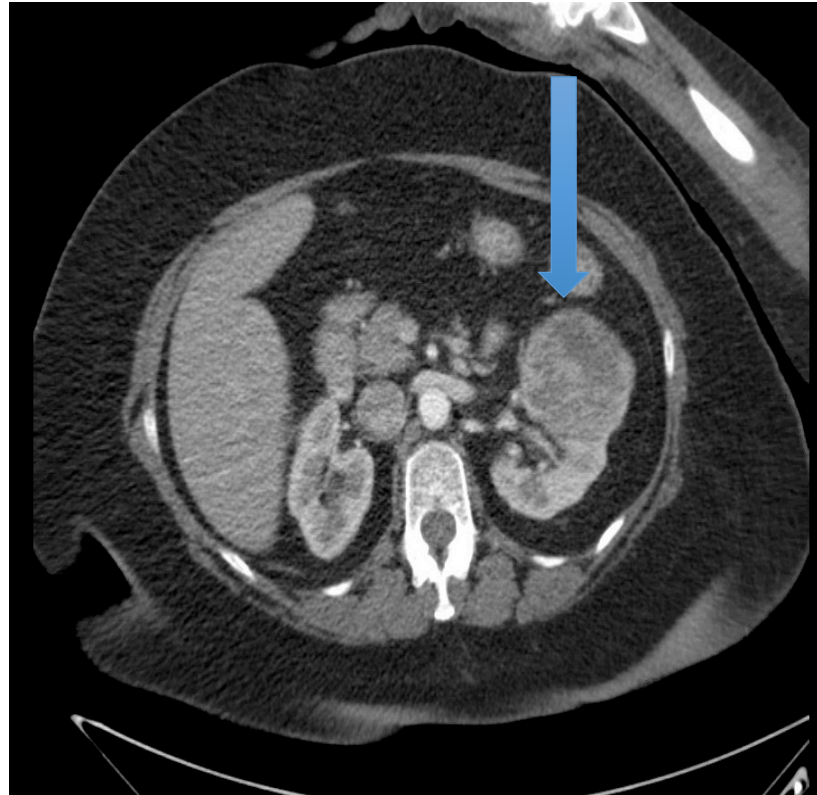
Renal Cell: When to Resect?

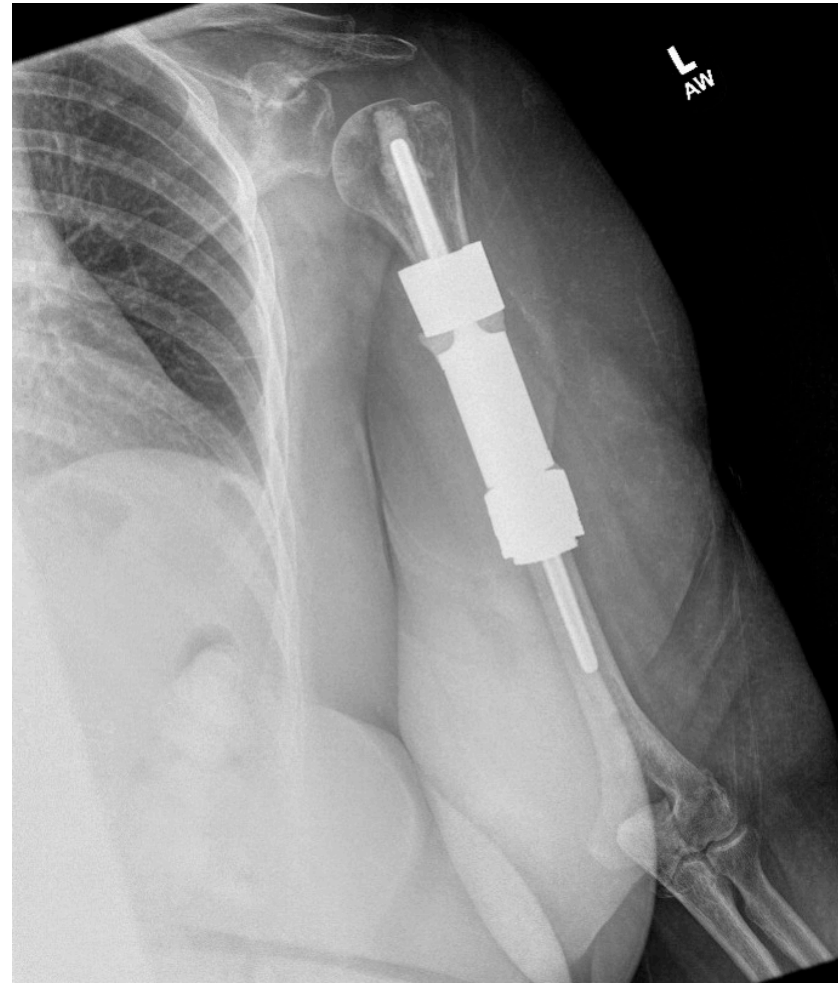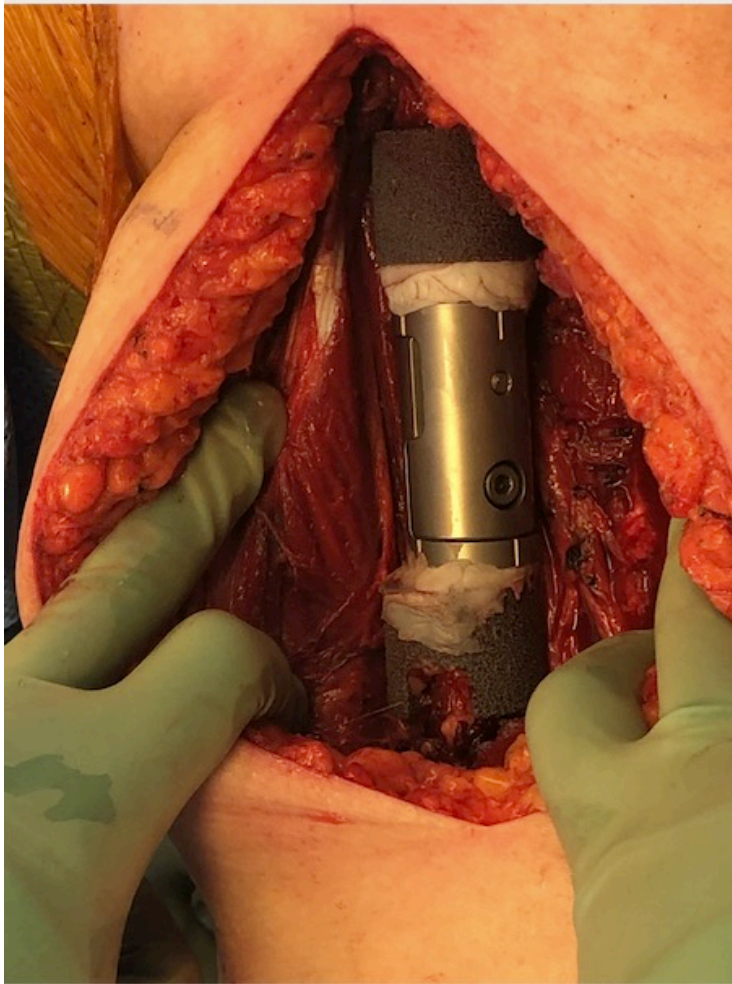
Oligometastatic Disease

60 year old female that was found to have metastatic renal cell carcinoma following a pathologic humerus fracture

Staging revealed two sites of disease
(oligometastatic)

- 1) Kidney mass
- 2) Left humerus

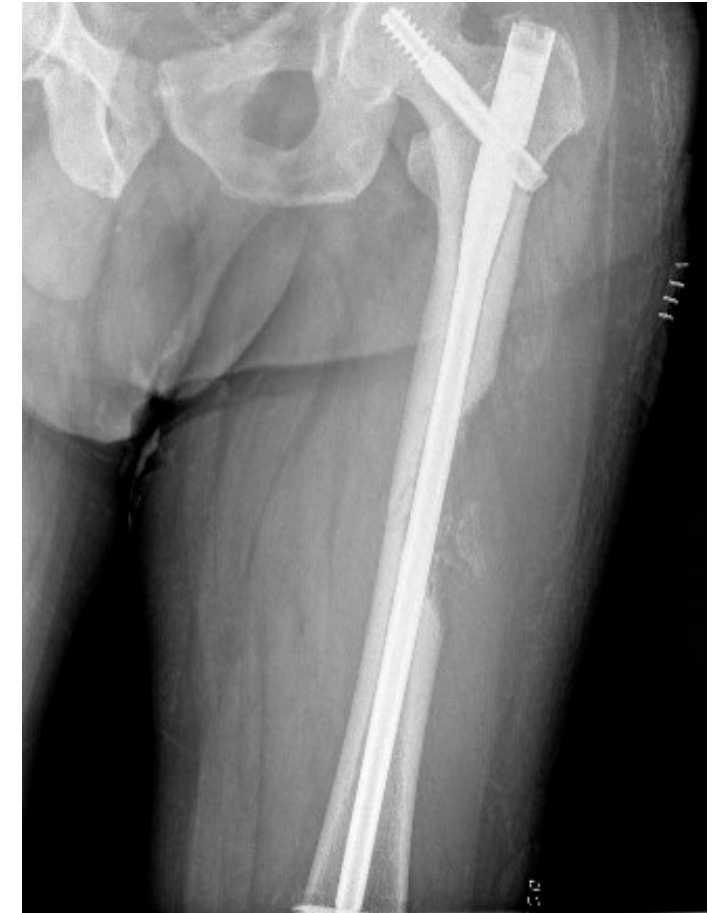
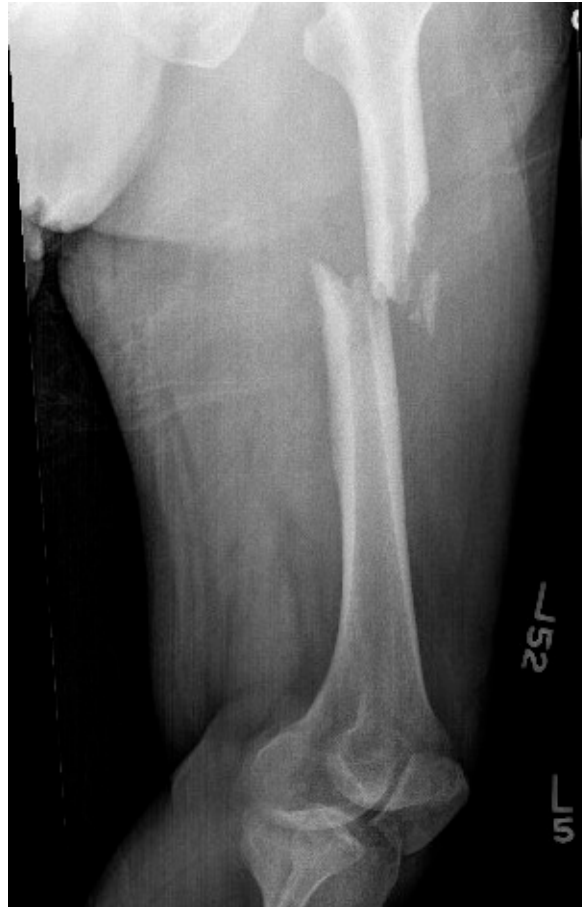


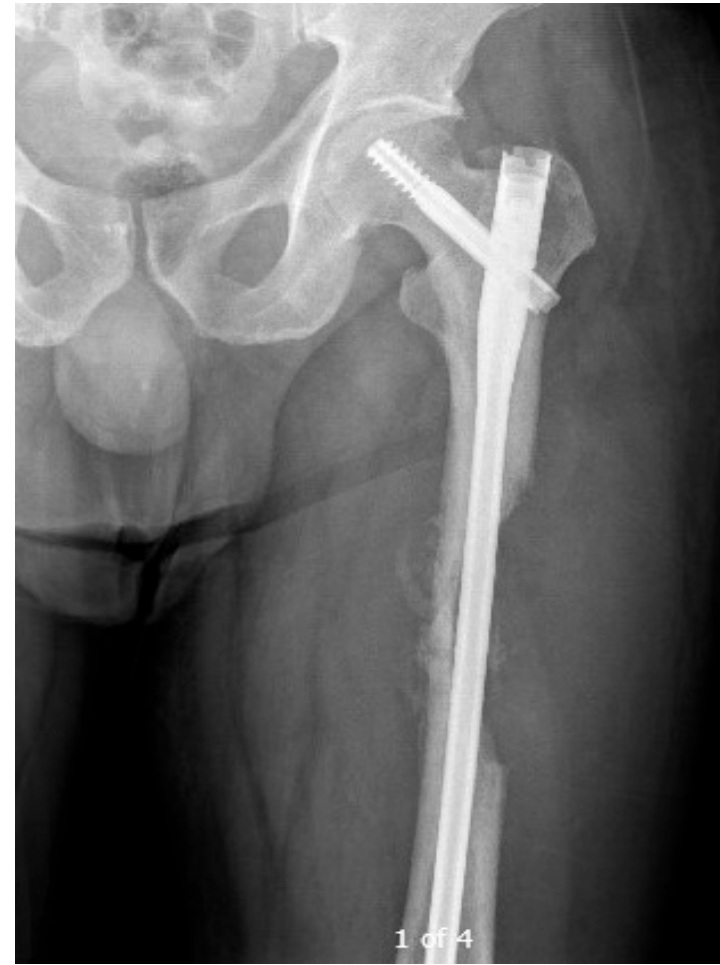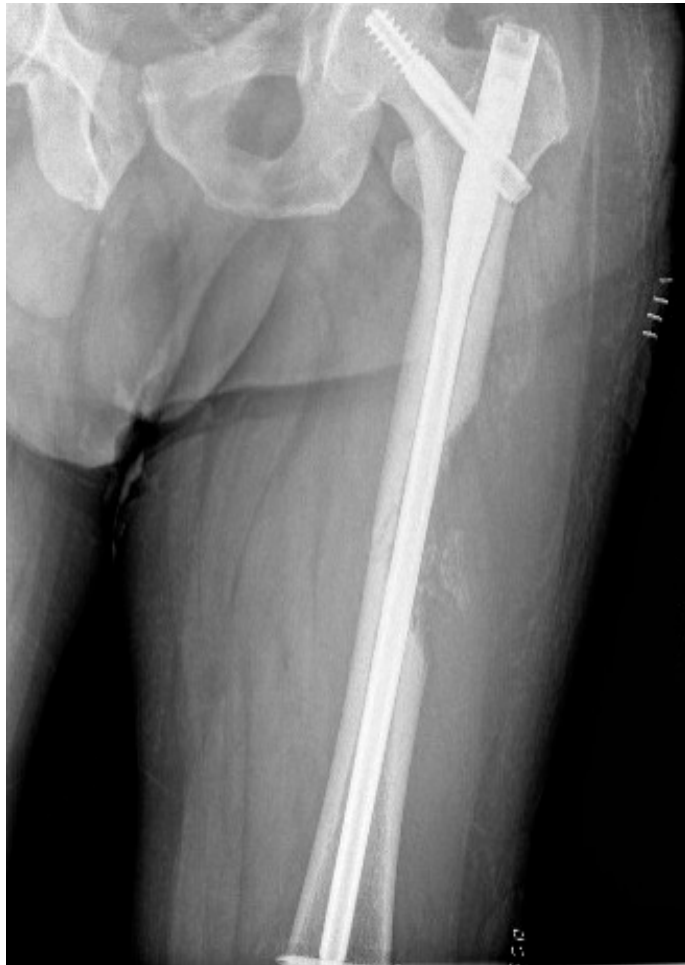This patient underwent intercalary resection and reconstruction of the humerus as well as a nephrectomy (performed later) in order to resect all sites of disease and hopefully increase survival. Wide resection performed at the humerus also meant that the patient could avoid postoperative radiation.

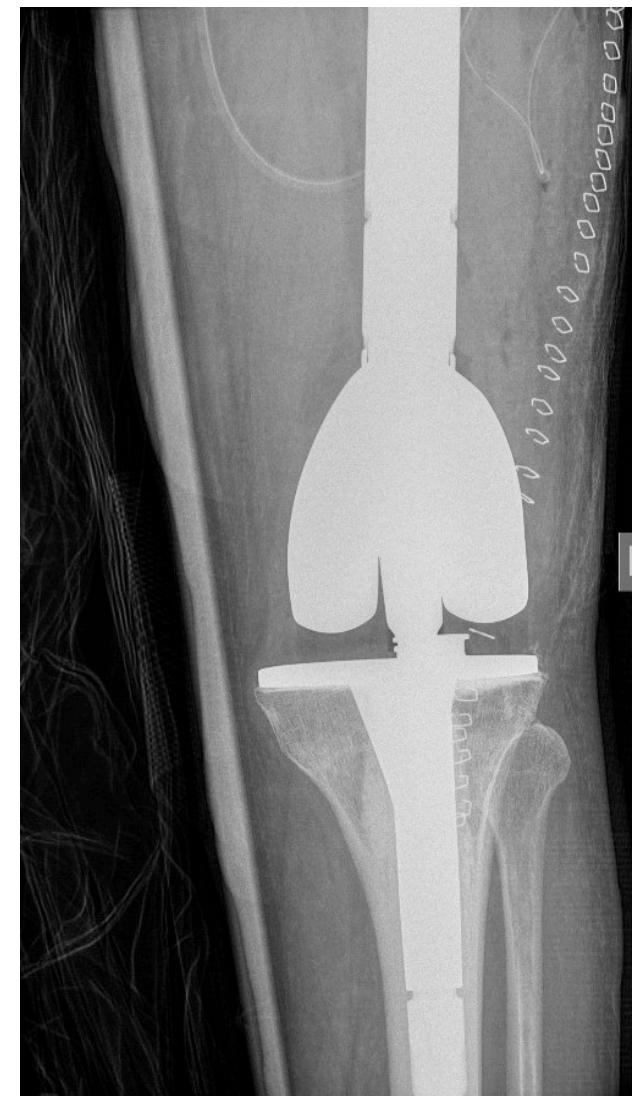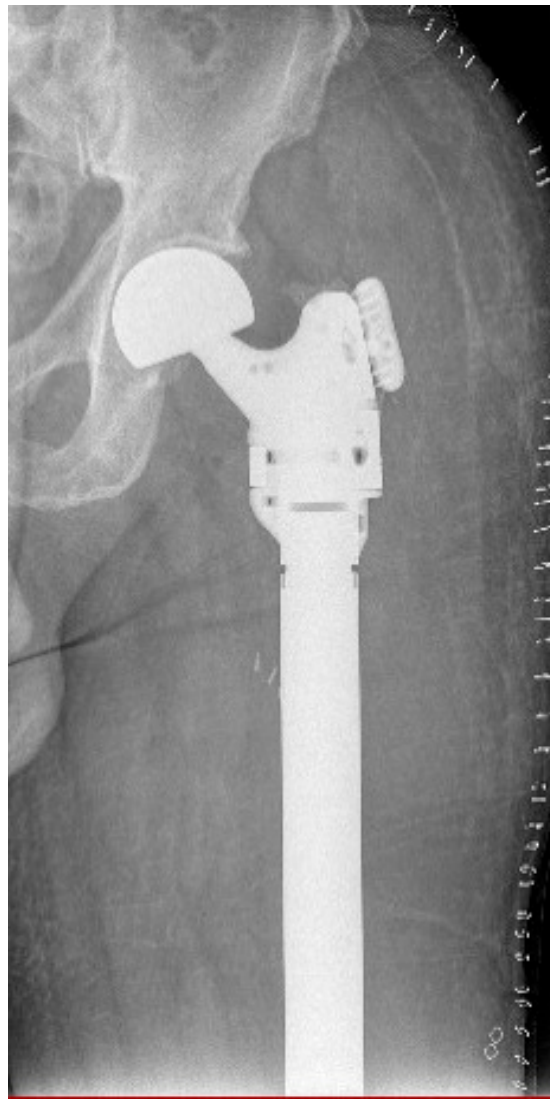
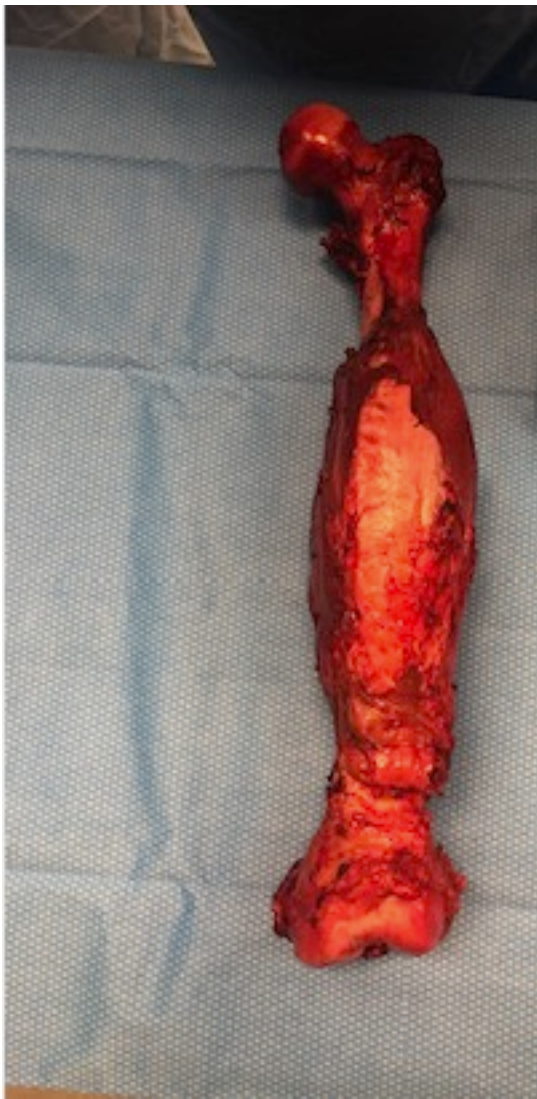Tumor Progression

- This patient presented with a pathologic femur fracture
- Workup revealed metastatic renal cell carcinoma with widespread visceral and bony metastases
- Elected to undergo fixation





Immediate postop and 3 month follow-up radiographs. At 3 months, significant tumor progression and bony destruction noted (although postop XRT was given). MRI revealed progression/recurrence of associated soft tissue mass



The patient underwent wide resection of the femur (including extraosseous mass) and endoprosthetic reconstruction to hopefully mitigate tumor recurrence or progression and allow durable reconstruction. Even in the setting of metastatic disease, his survival is still estimated at several years.

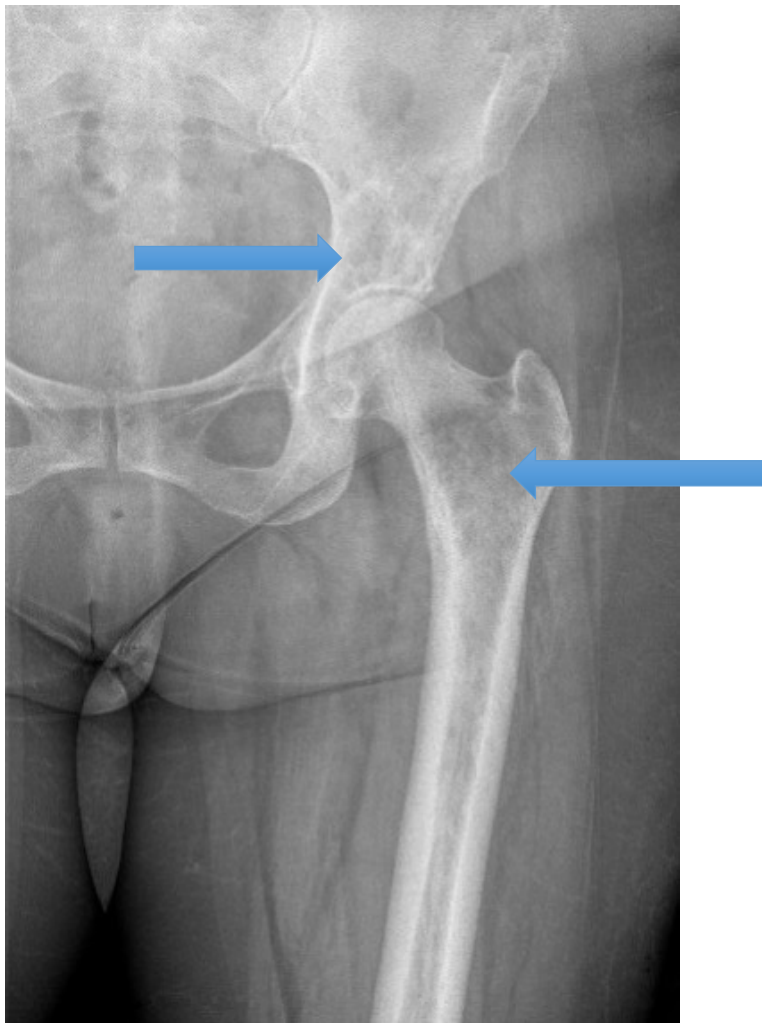
Metastatic Thyroid Carcinoma

- Relatively good prognosis for most types
- Relatively sensitive to XRT
- Vascular- consider **pre-op embolization** as with RCC
- Some also argue for metastectomy for solitary lesions or oligometastatic disease

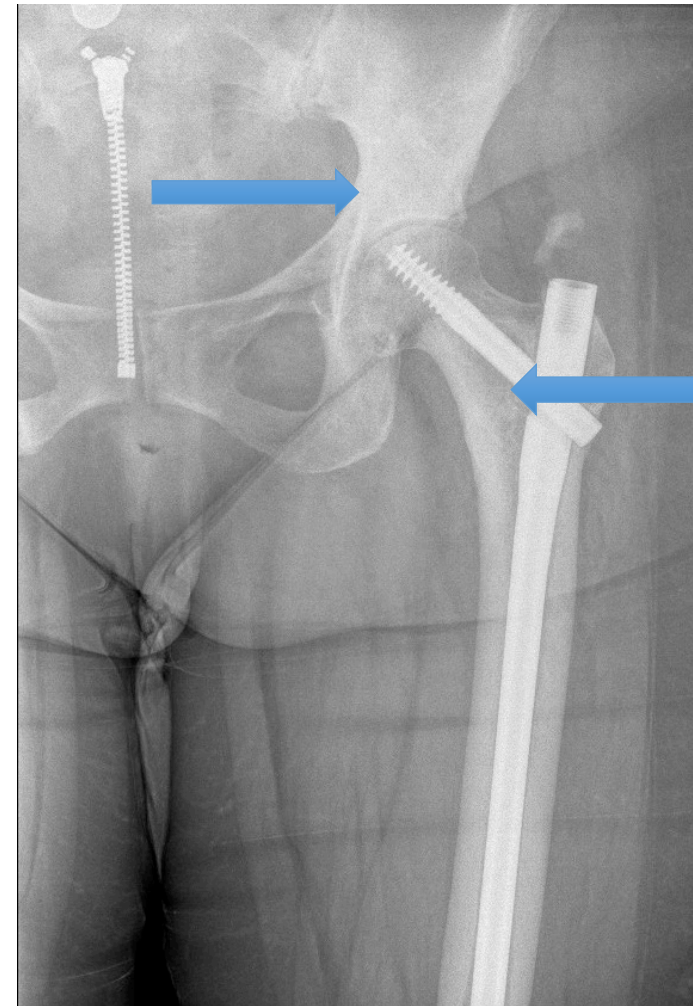
Metastatic Breast Carcinoma

- Medical treatments based on tumor expression of hormone receptors or HER-2/neu
- Lesions usually mixed or blastic in appearance
- Very sensitive to XRT

Pre- XRT



Post- XRT



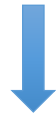Metastatic breast cancer patient that underwent prophylactic fixation for impending left proximal femur fracture. Also observed was a left periacetabular bone lesion. Both sites underwent XRT with excellent bony reconstitution, obviating the need for surgical intervention at the left acetabulum

Metastatic Prostate Carcinoma

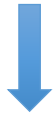- High incidence of bony metastasis
- Typically blastic in appearance
- Very radiosensitive
- If performing intramedullary fixation, beware of blastic lesions that may make this difficult
 - Re-cannulate intramedullary canal with drill bits, reamers, etc. under fluoroscopy

Surgical Treatment Techniques in Pathologic Fractures

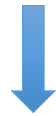What's the primary diagnosis?



What's the prognosis?



Where is the location of the lesion or fracture?



How much bone stock is left?

General Principles

- Provide a durable construct that will outlive the patient
 - “One operation for one patient”
- Provide a construct that allows for immediate weight-bearing and function
- Potential for bone healing is less (pathologic bone, likely need for postop XRT); strongly consider augmented fixation or reconstruction (additional plates, PMMA, etc)

Fixation versus Reconstruction

Fixation

- Adequate bone stock
- Bony healing or reconstitution possible (breast, prostate, myeloma, lymphoma)
- Non-periarticular location

Reconstruction (Endoprosthesis)

- Inadequate remaining bone stock
- Poor chance of bony healing
- Solitary lesion or oligometastatic disease in which resection/metastectomy is planned
- Peri-articular location

Upper Extremity Guide to Reconstruction

- Scapula/Clavicle
 - May consider non-op
- Proximal Humerus
 - Adequate remaining bone- locked plating +/- PMMA
 - Poor remaining bone- arthroplasty (+/- reverse shoulder arthroplasty)
- Diaphyseal Humerus
 - Adequate remaining bone- IMN or plate/screws +/- PMMA
 - Poor remaining bone- intercalary prosthesis
- Distal Humerus
 - Adequate remaining bone- dual plating +/- PMMA
 - Poor remaining bone- consider arthroplasty (total elbow or distal humerus/total elbow arthroplasty)

Johnson et al. JAAOS. 2019.



Lower Extremity Guide to Reconstruction

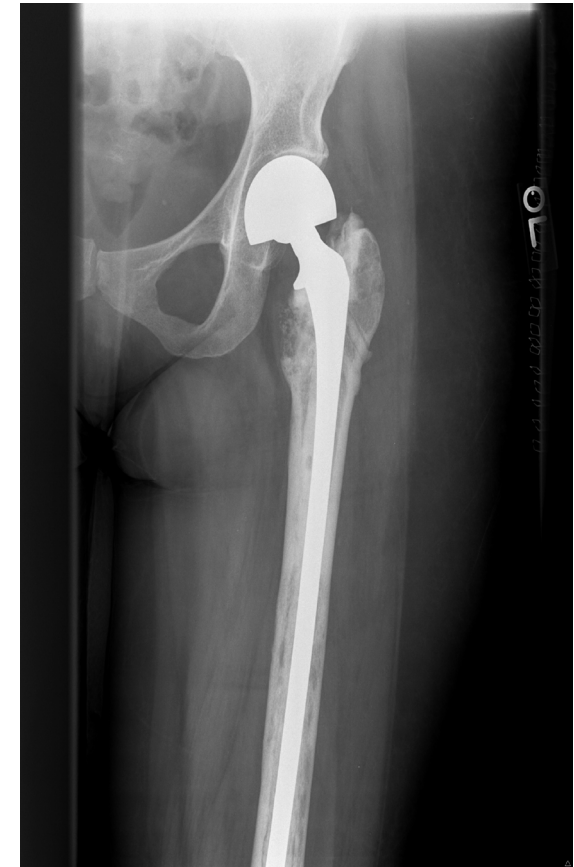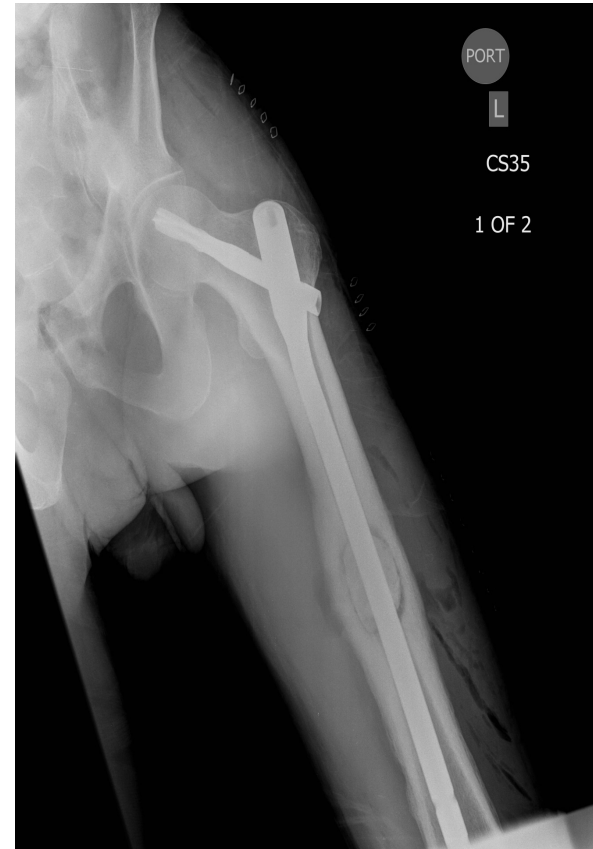- Iliac crest or pubic rami
 - Consider non-op
 - If acetabular involvement- consider arthroplasty
- Femoral head/neck
 - Adequate remaining bone stock- can consider fixation +/- PMMA
 - Poor remaining bone stock- arthroplasty (hemiarthroplasty versus total hip arthroplasty)
- Pertrochanteric femur
 - Adequate remaining bone- cephalomedullary fixation +/- PMMA
 - Poor remaining bone- arthroplasty
- Diaphyseal femur
 - Adequate remaining bone- intramedullary fixation +/- PMMA
 - Poor remaining bone- intercalary prosthesis
- Distal femur
 - Adequate remaining bone- fixation +/- PMMA
 - Poor remaining bone- arthroplasty (TKA versus distal femur arthroplasty)
- Proximal tibia
 - Adequate bone- fixation +/- PMMA
 - Poor bone- arthroplasty (TKA versus proximal tibia replacement)

Johnson et al. JAAOS. 2019.



Should we protect the entire bone?

- Traditional teaching states that we should stabilize the entire bone in order to avoid future operations if new lesions present
 - Example #1) Cephalomedullary or recon-style screws across the femoral neck when stabilizing a diaphyseal femur lesion
 - Example #2) Use of long-stemmed arthroplasty stem for proximal femur periarticular lesion



Should we protect the entire bone?

- However, complications do exist from using these implants
 - Particularly, long stemmed cemented femoral arthroplasty implants

Bone Cementation Implantation Syndrome (BCIS)

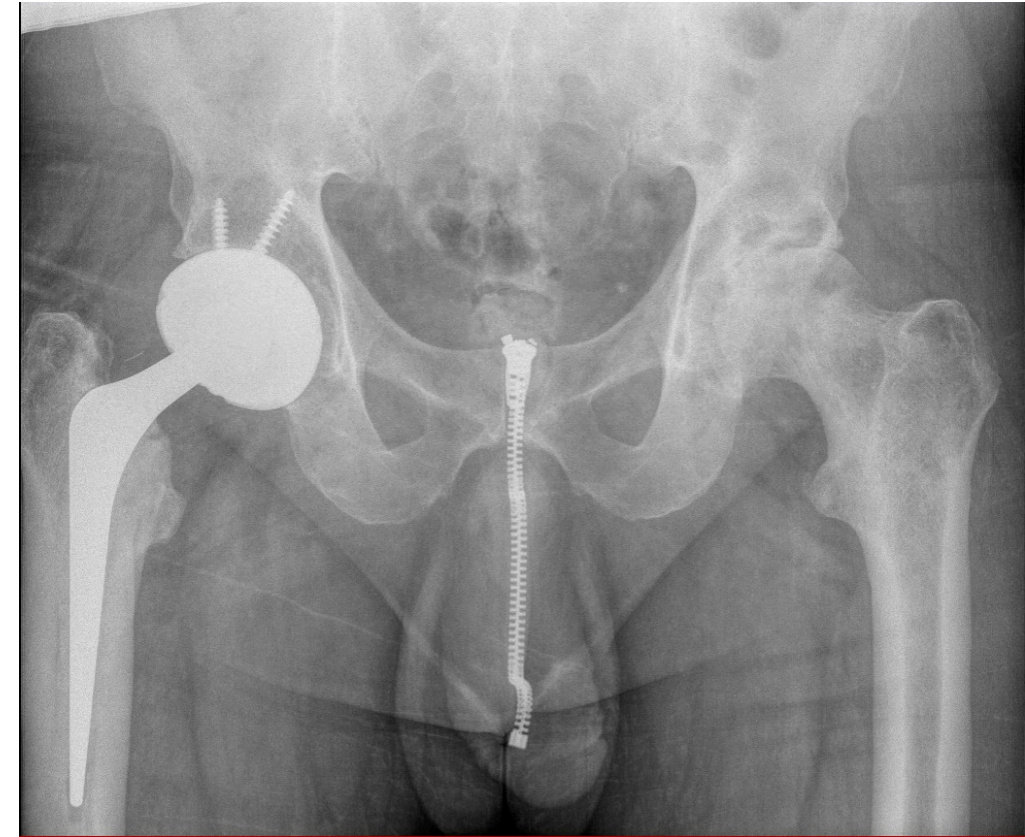
-Mechanism still unclear but appears to be embolic phenomenon that leads to acute cardiopulmonary collapse

-Risks factors include:

- 1) Use in the setting of metastatic or pathologic fracture
- 2) Use of long stemmed **cemented** implant
- 3) Underlying pulmonary disease

Should we protect the entire bone?

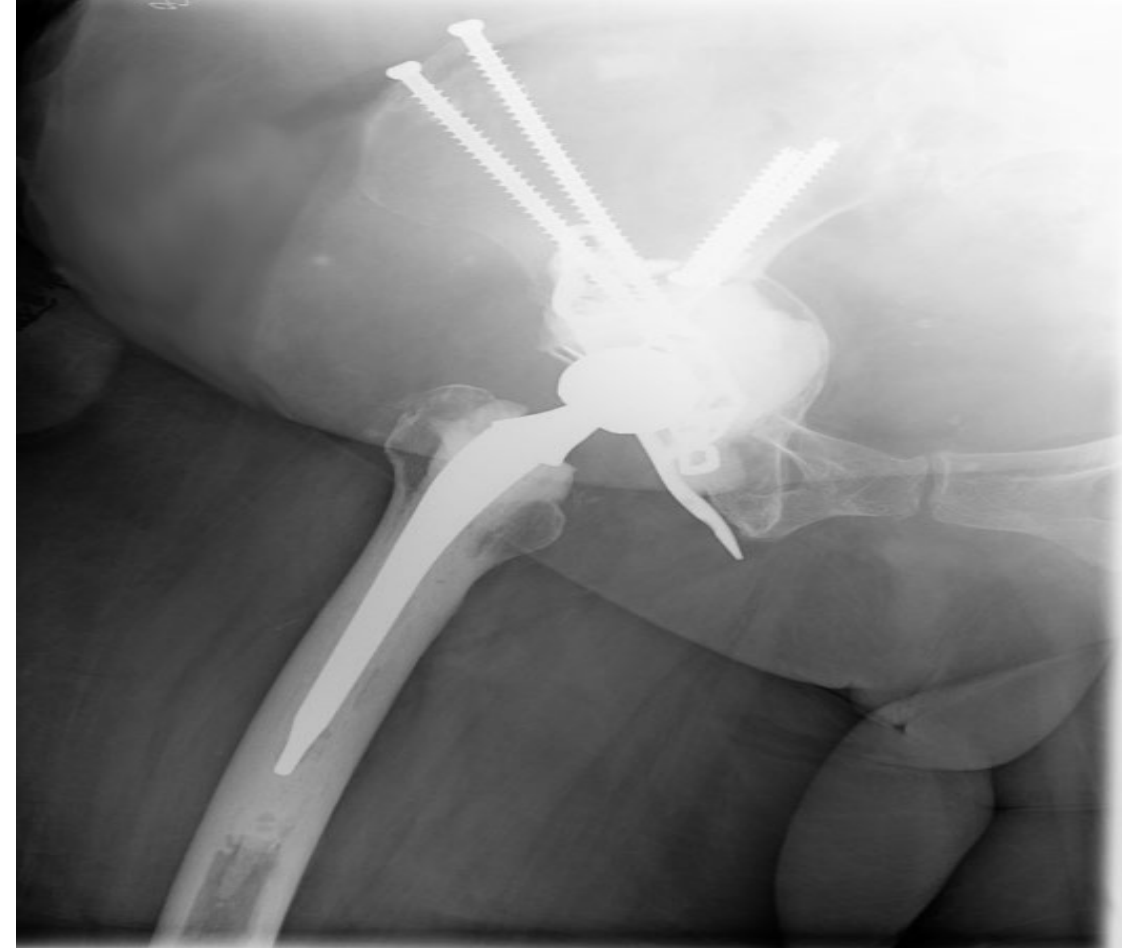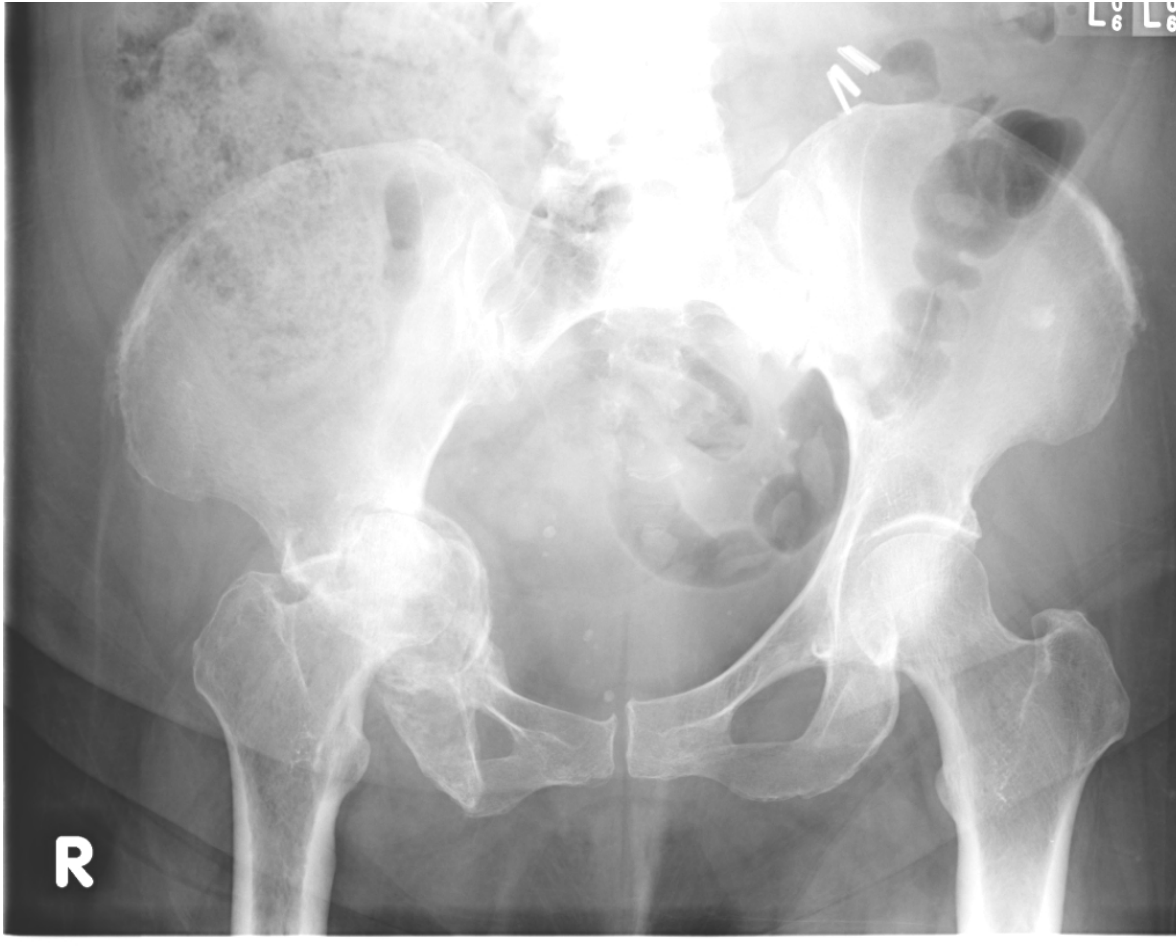- For most entities, the possibility of developing a new lesion not included in the original original construct is low
 - Myeloma and renal cell carcinoma may be exceptions to this
- Further, although the incidence of BCIS is low, treatment is only supportive and mortality is high
- Therefore, some argue that for proximal femur metastatic lesions requiring arthroplasty:
 - Short or medium stem length femoral stems options are acceptable
 - Long stemmed prostheses may be reserved for patients with concomitant diaphyseal lesions



Considerations for Pelvis/Acetabulum Reconstruction

- Degree of bone loss may warrant use of revision-style implants
 - Augments, cement, jumbo cups, etc.
- Harrington-style reconstruction:
 - “Rebar and cement”
 - Utilizes screws or pins (inserted antegrade or retrograde) in the periacetabular defect and then filled with cement
 - Helps to restore continuity from the ilium to the pubic segment
 - Often requires lateral window/incision over crest to insert pins
 - Good short-term results, however long-term results appear to be intermediate or worse

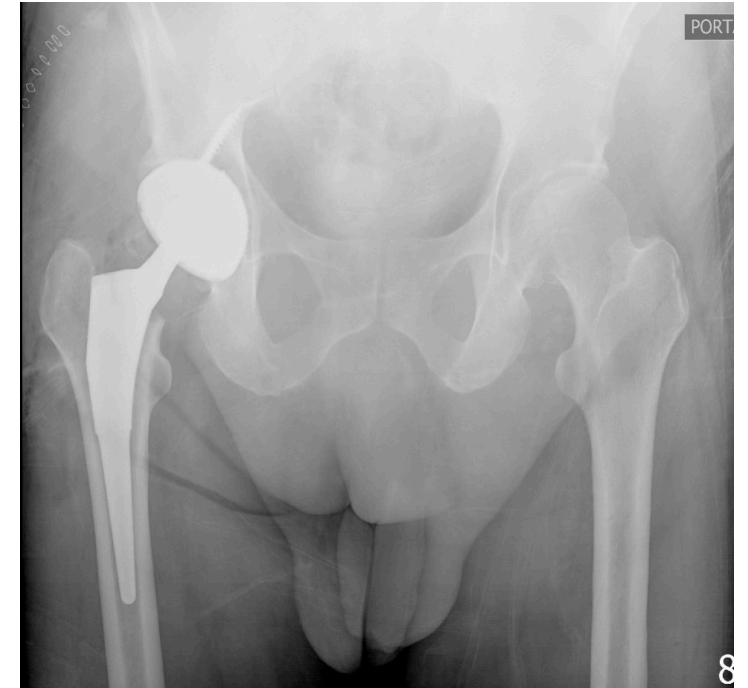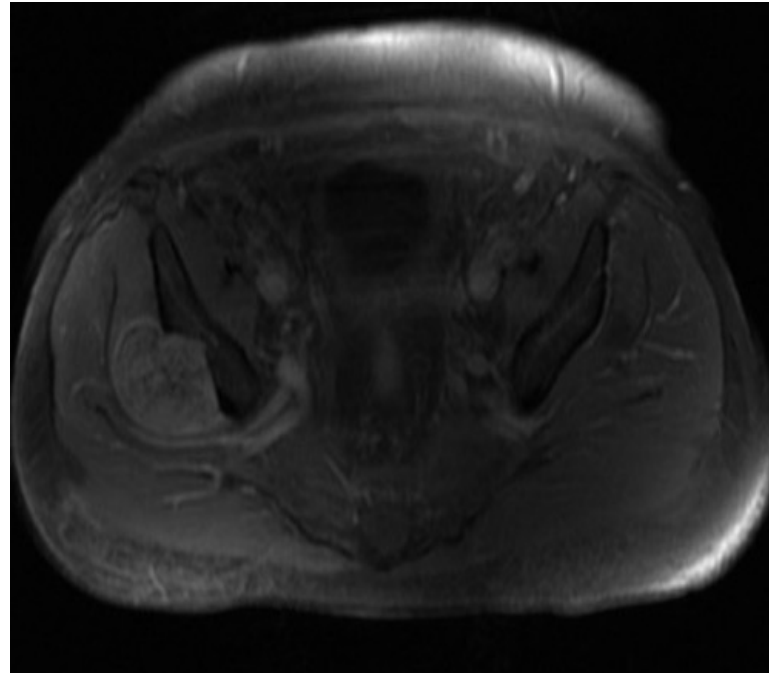
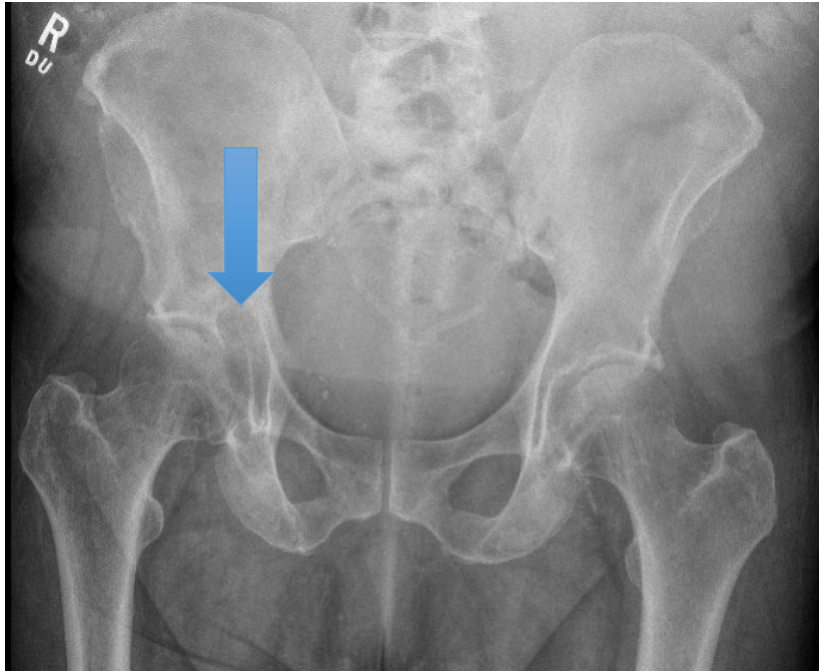
Harrington Reconstruction



Acetabular Reconstruction

- Newer techniques are now supplanting the traditional pins-and-cement with porous metal (tantalum) reconstruction
- Have been used even in setting of previously irradiated bone
- The possibility of bony-ingrowth may increase long-term durability

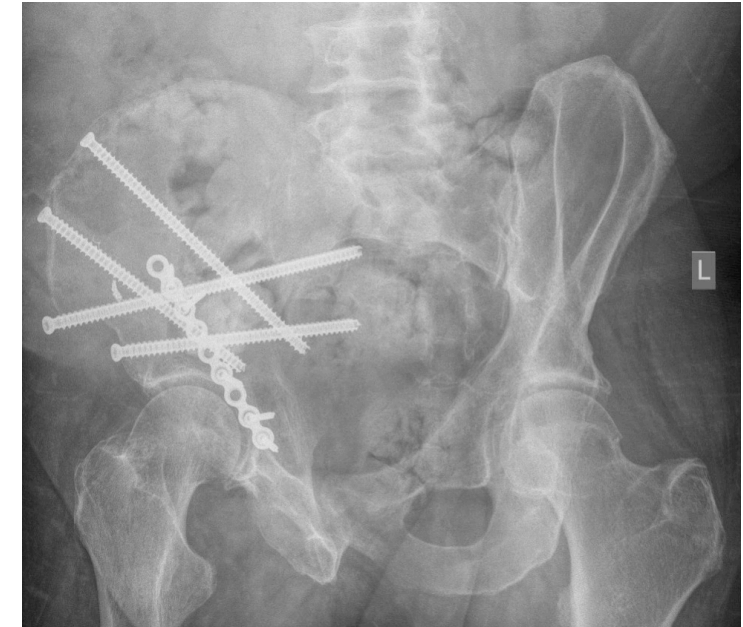
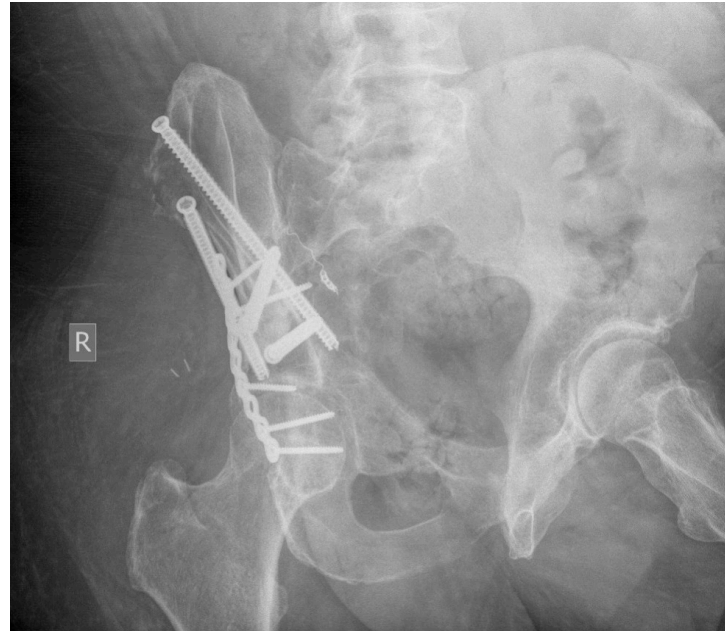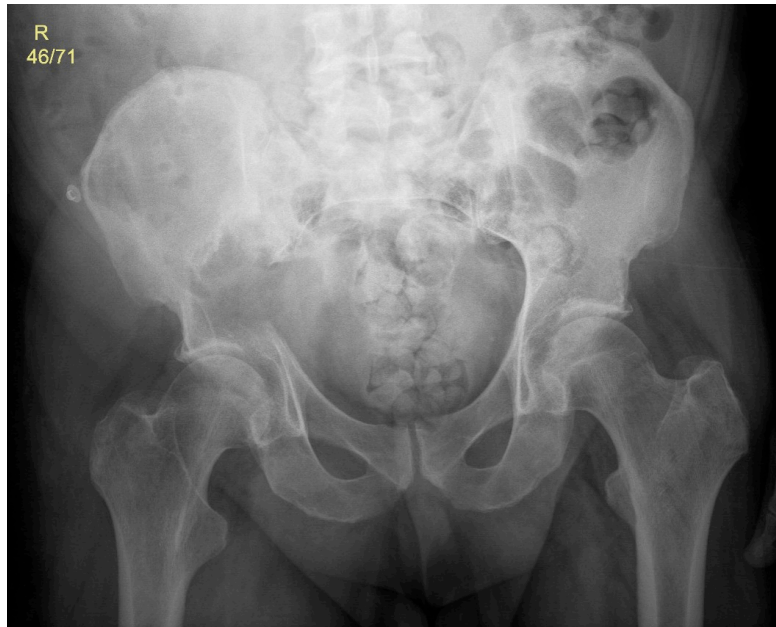Houdek et al. JBJS. 2020
Khan et al. CORR. 2010
Houdek et al. JAAOS. 2020.



Right acetabulum bone lesion from metastatic renal cell carcinoma seen on radiograph (left) and MRI (center). This underwent curettage of the lesion (involving the medial and posterior acetabular walls) and total hip arthroplasty reconstruction utilizing a porous metal acetabular shell and multiple screws.

Acetabular Reconstruction Utilizing Fixation

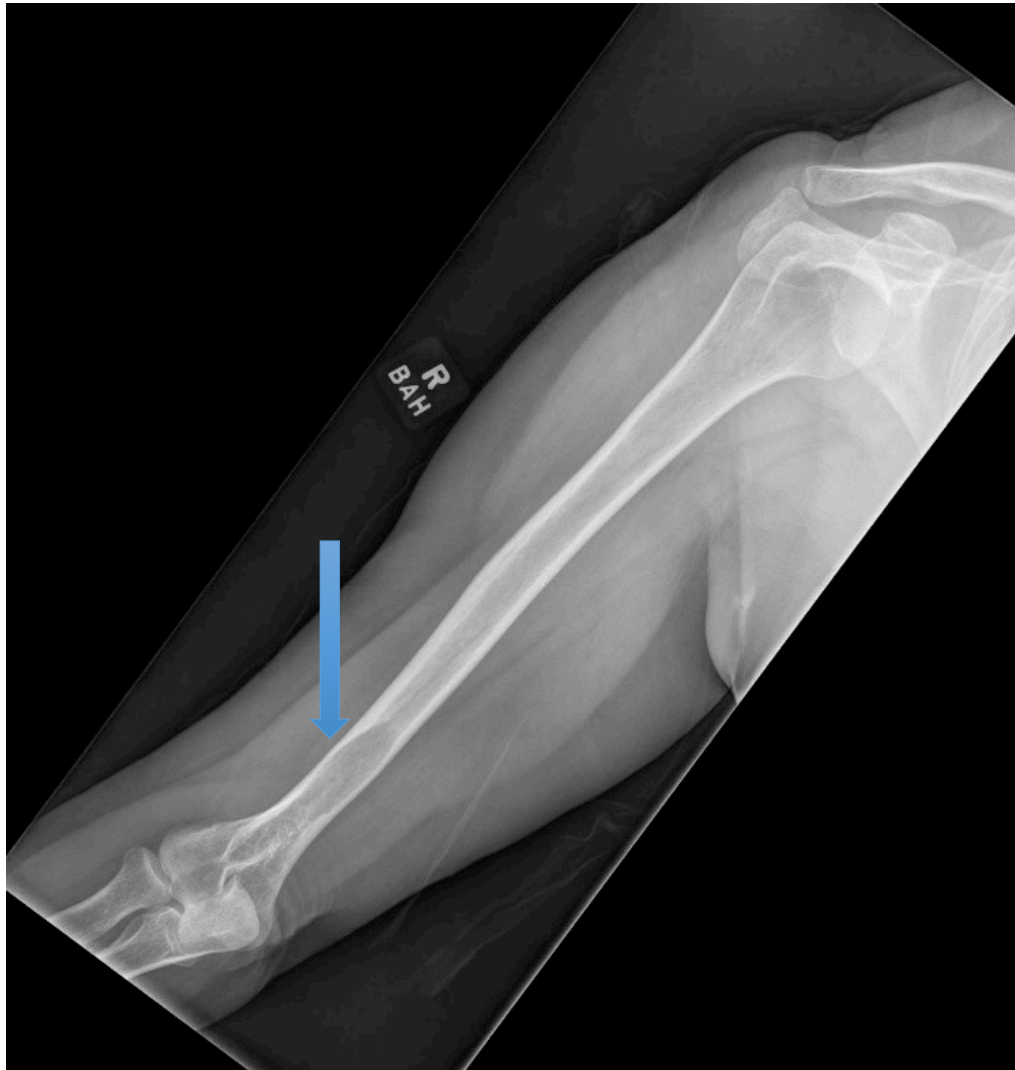- Goal is to unitize the pelvis/acetabulum columns across bone loss
- Can utilize traditional osseous fixation pathways for screw insertion



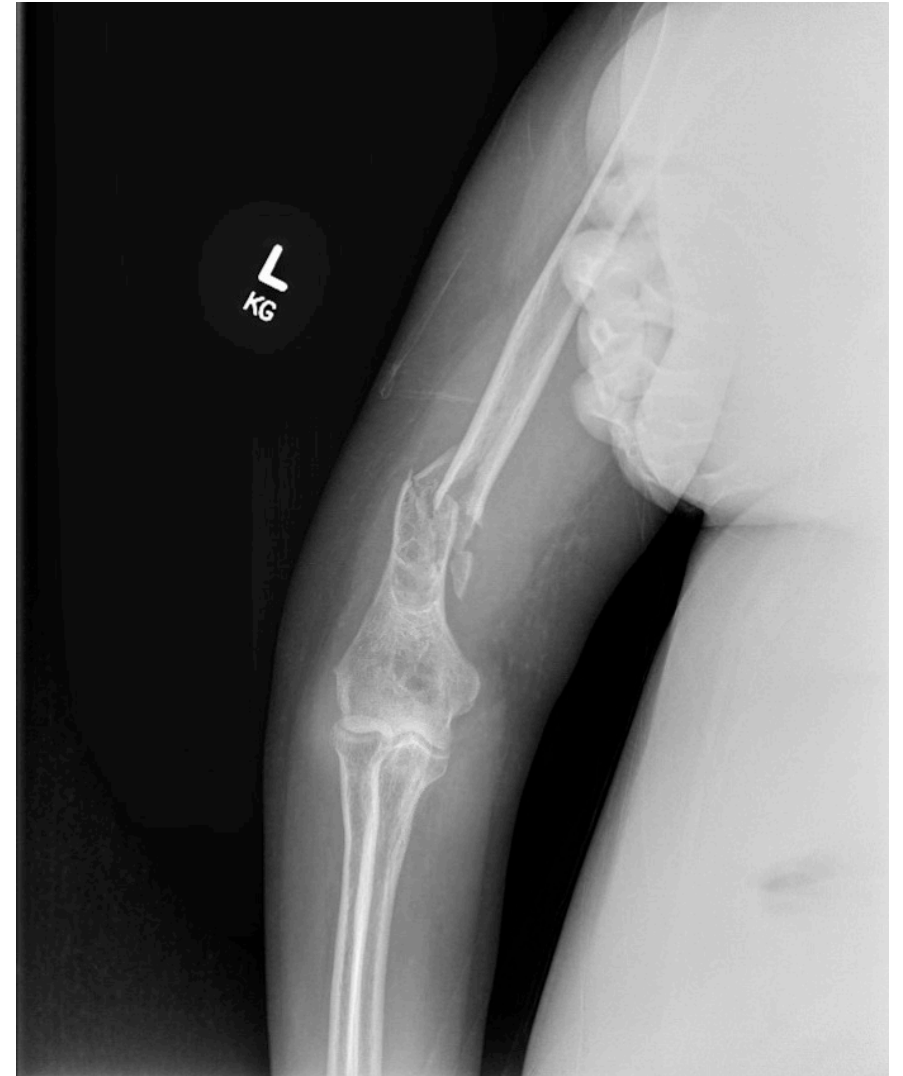This patient underwent curettage and pelvis fixation. Curettage was performed first. Next, screws were inserted from the iliac crest to the peri-acetabular area followed by traditional “LC2” screws. Finally, a posterior column plate was applied and cement was used as reinforcement.

Case Example #1

- 57 year-old female presents with right arm pain, no trauma
- Dominant arm
- History of metastatic renal cell carcinoma with known bony and visceral metastases (previous biopsies already performed)
- Right distal metadiaphyseal humerus lesion
 - Has previously undergone XRT to this area prior to consultation



XR prior to consultation



XR at consultation

Case Example #1

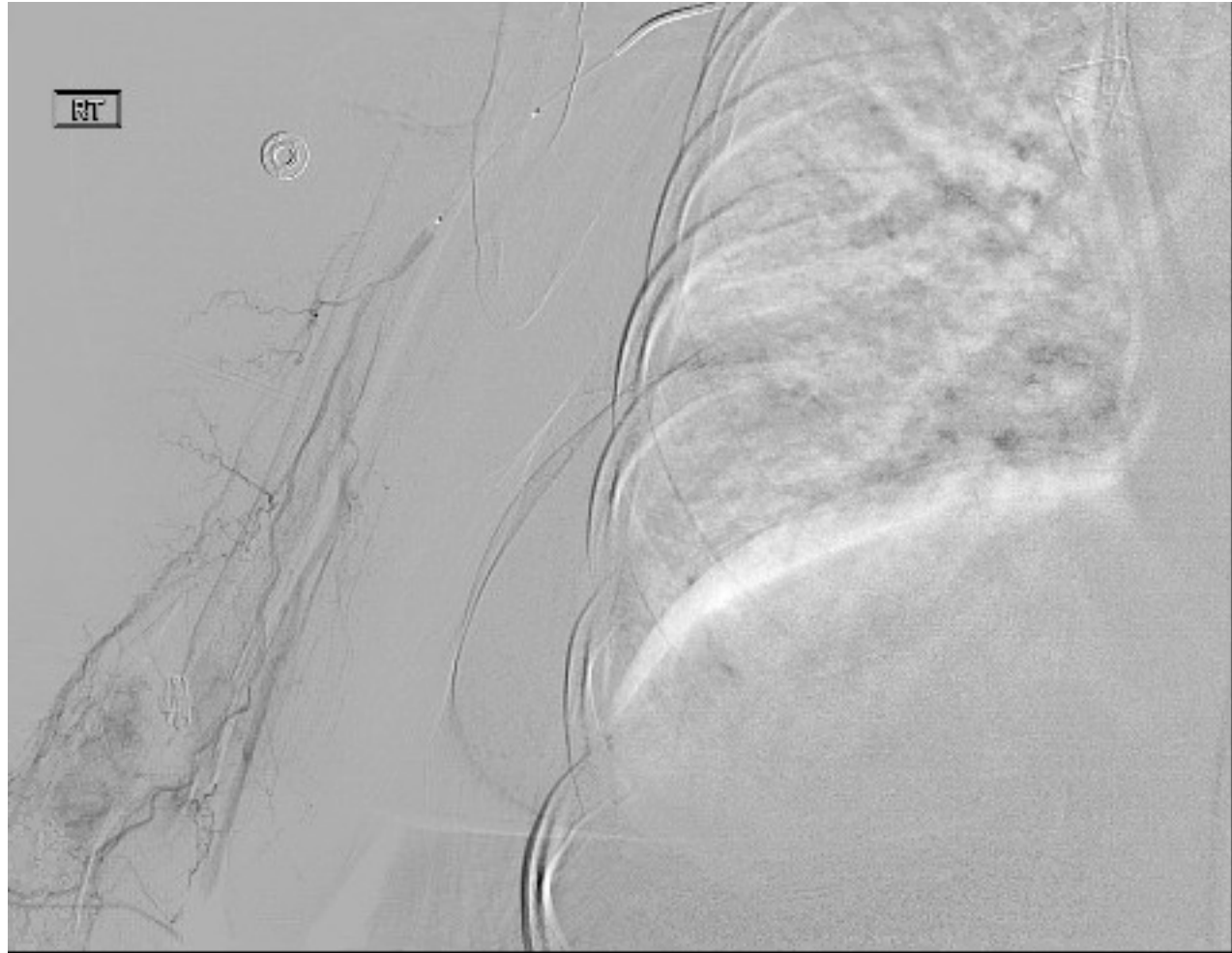
- Key points to consider:
 - Pathologic fracture at right distal humerus
 - **Diagnosis:** metastatic renal cell carcinoma already confirmed (metastatic RCC): known bony mets
 - **Prognosis:** Fair at 1 year
 - **Location:** Distal humerus
 - **Bone Stock:** Decreased due to lesion/previous XRT; joint appears to be salvageable

Case Example #1

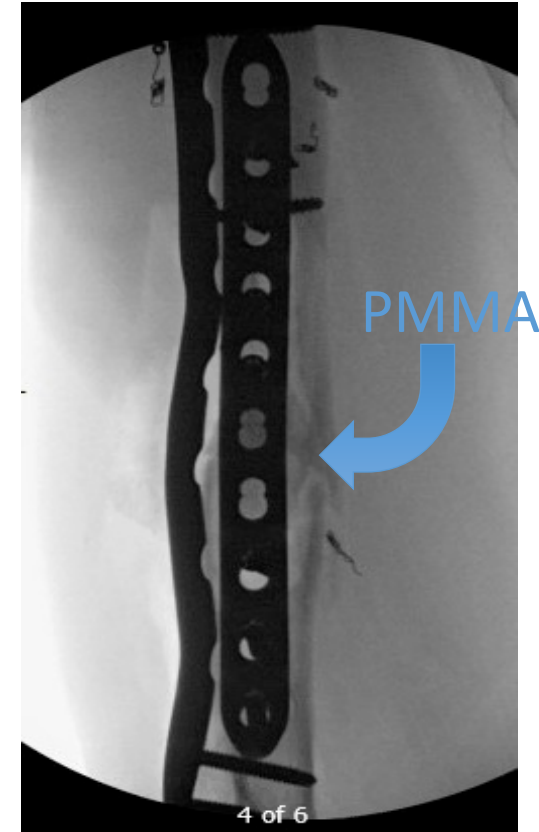
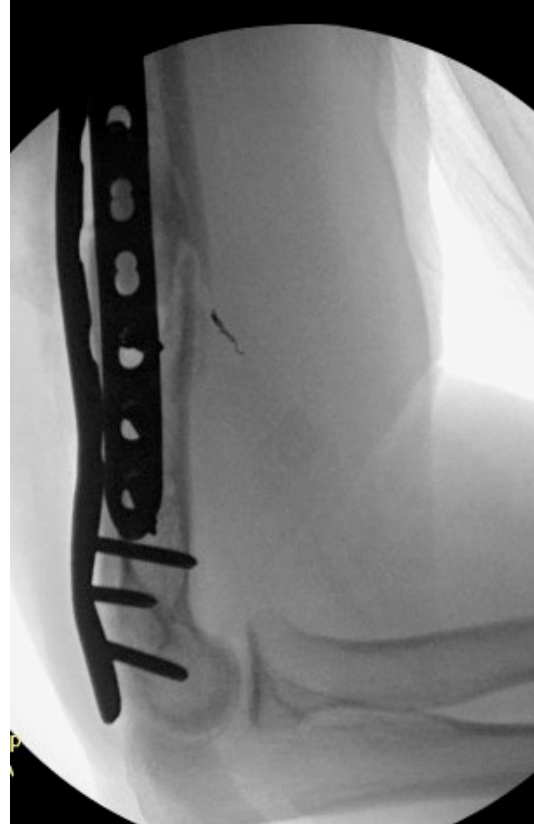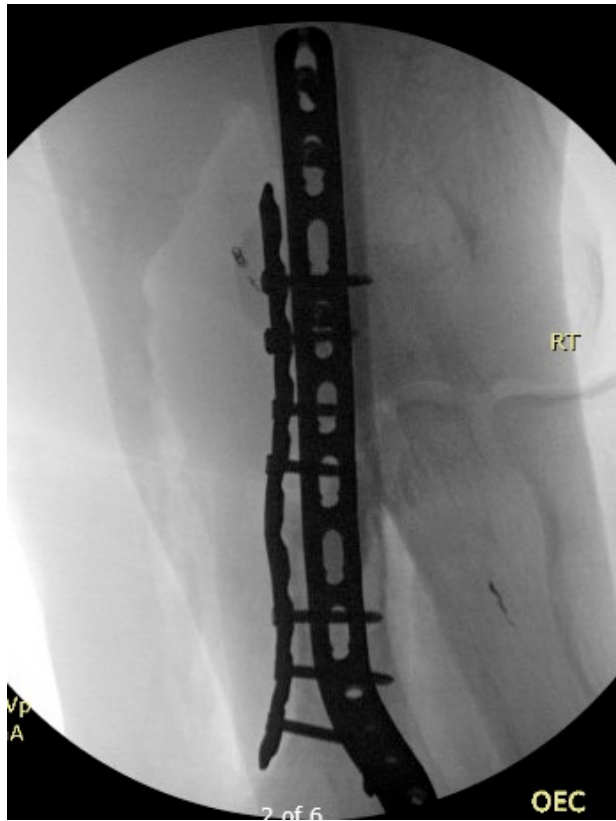
- ORIF was chosen as surgical treatment
- Fixation considerations
 - ORIF vs Resection/Reconstruction: known widespread mets, dominant arm and location (as resection would require elbow arthroplasty) were reasoning for ORIF in this patient
 - Planned intralesional procedure and metastatic RCC: consider pre-operative embolization
 - Bone loss: will need fixation augmentation (PMMA) to ensure construct durability
 - Location: will likely need dual plating, enough remaining bone stock to salvage joint

Step 1: Pre-op Embolization

Embolization performed due to planned intralesional procedure and vascular nature of RCC mets



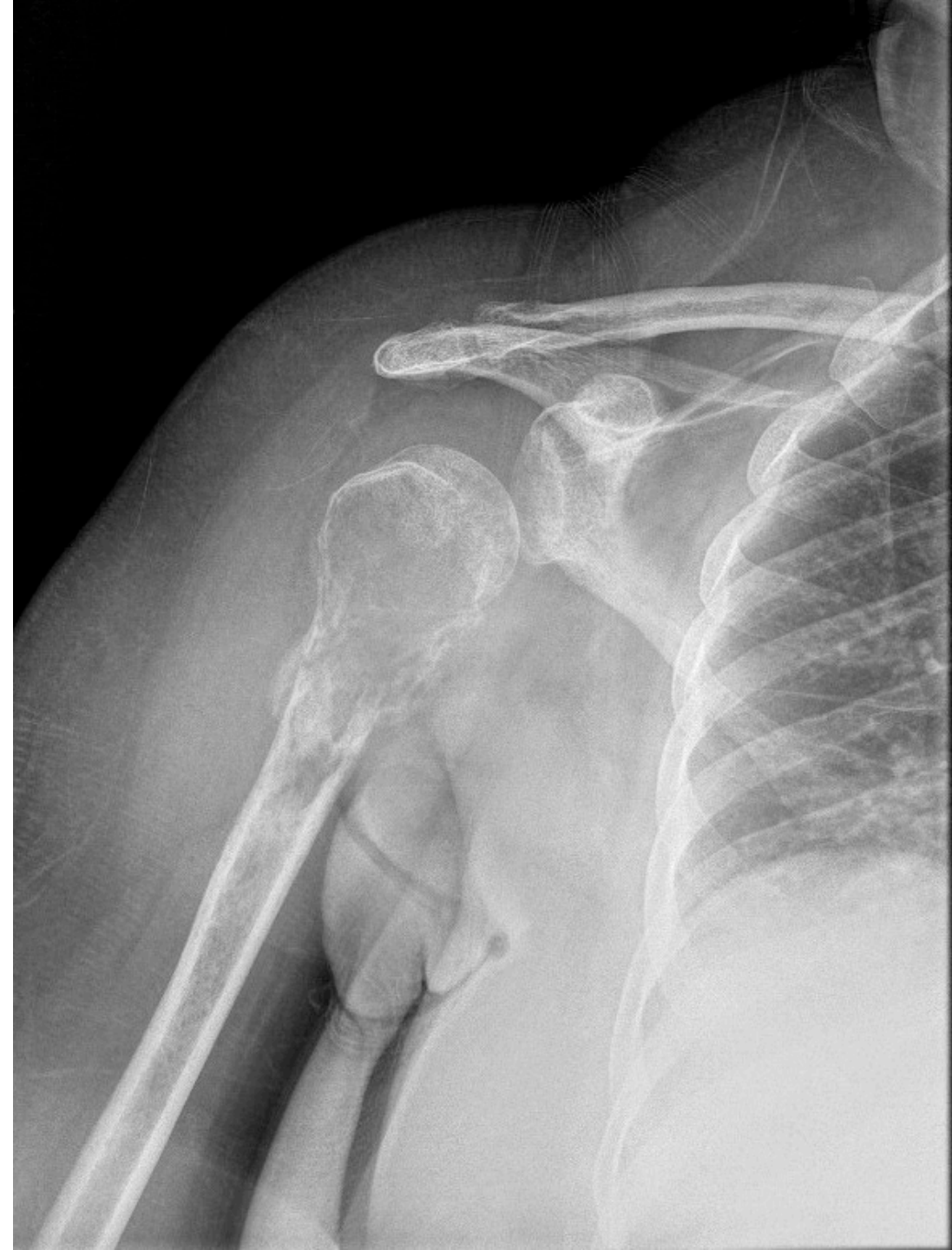Step 2: Operative Sequence



1) Small fragment plate applied medially for provisional reduction/fixation 2) Posterolateral plate applied with provisional screws 3) Curettage performed at lesion, PMMA then placed 4) Completion of fixation construct

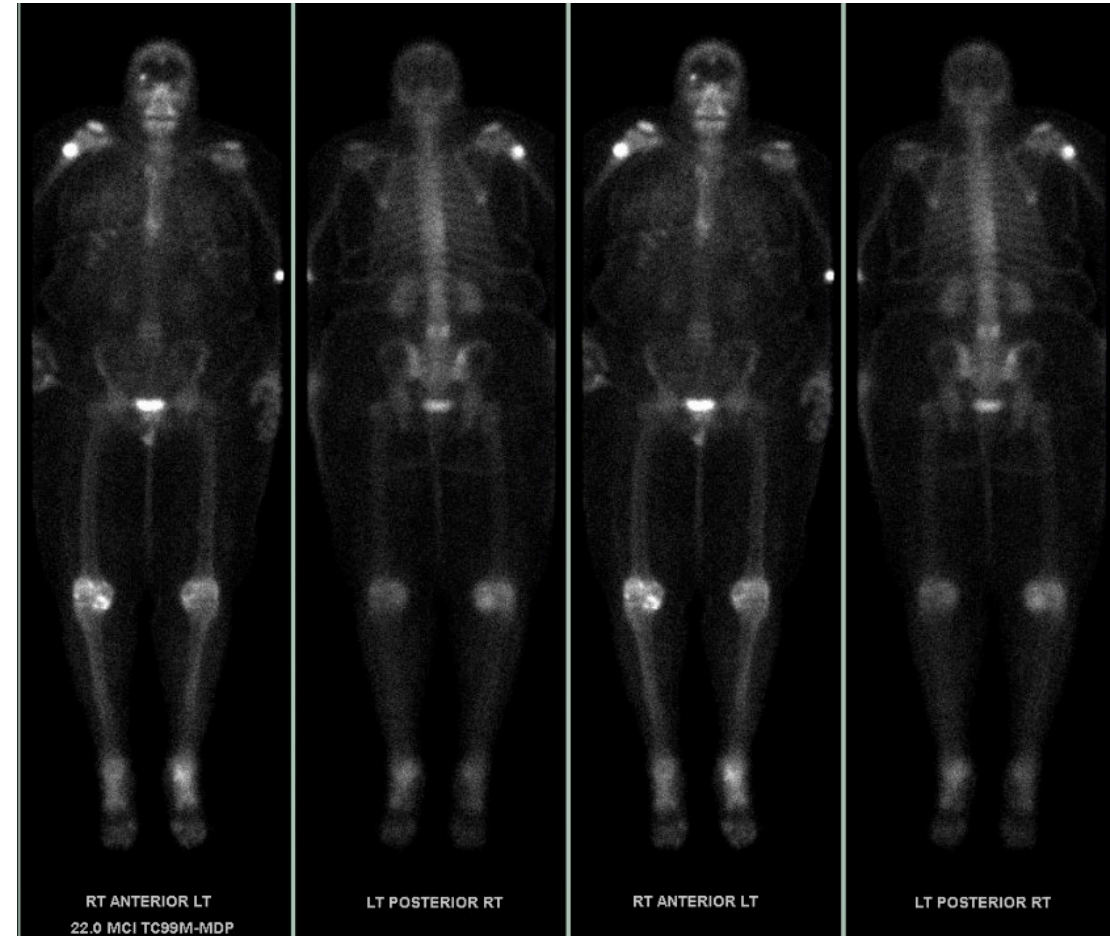
Case Example #2

- 48 year-old female presents with right shoulder pain x 2 months
- Radiographs show pathologic fracture through lesion at proximal humerus
- Further work-up pursued



Case Example #2

- CT chest/abdomen/pelvis negative
- SPEP shows monoclonal protein peak
- Bone scan only showed pathologic activity at right proximal humerus
- Skeletal survey showed multiple lytic lesions at ilium
- Core need biopsy (CT-guided) at right shoulder shows **myeloma**



Case Example #2

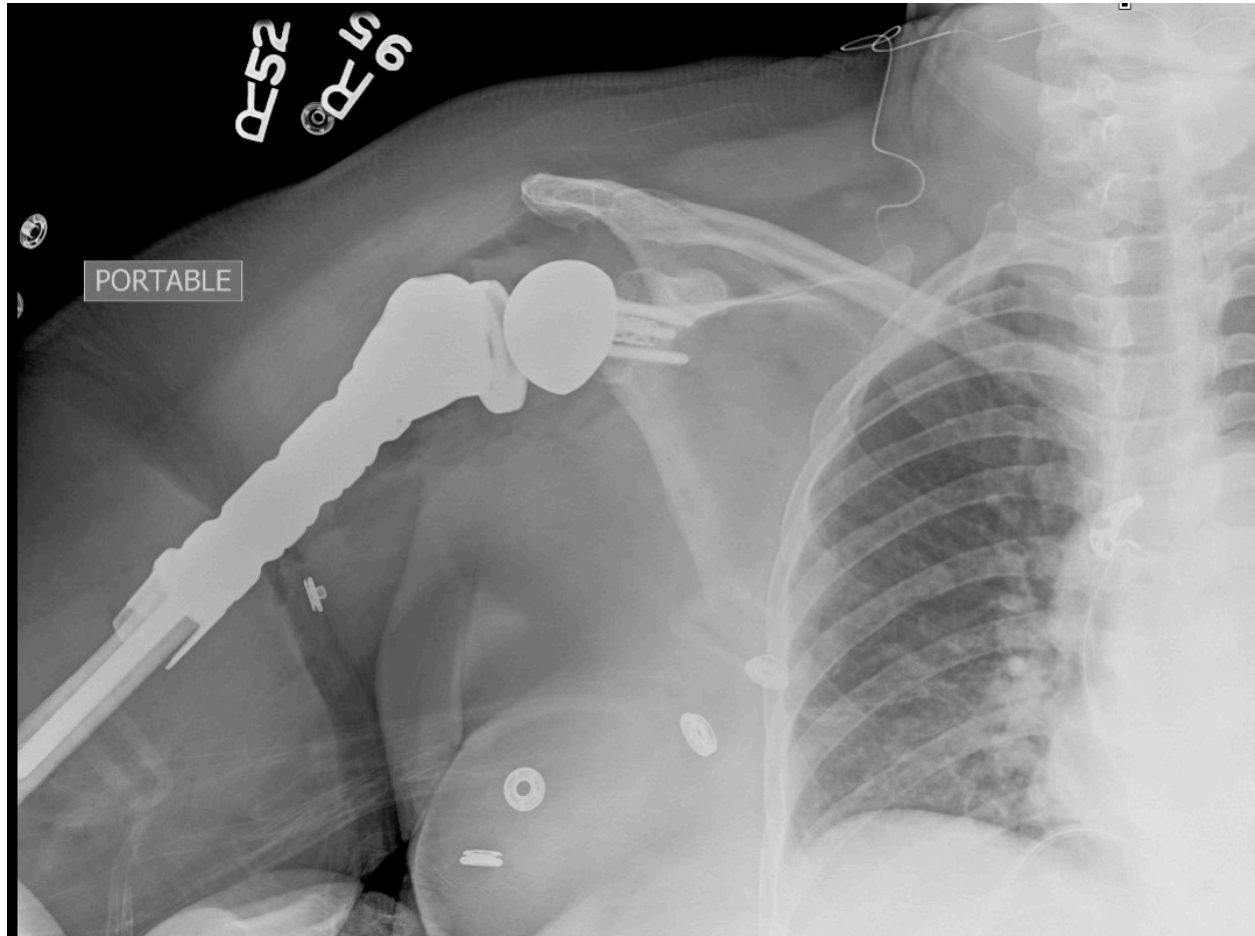
- Next steps?

Primary malignancy: multiple myeloma

Prognosis: Relatively good at 5 years

Location: Periarticular proximal humerus

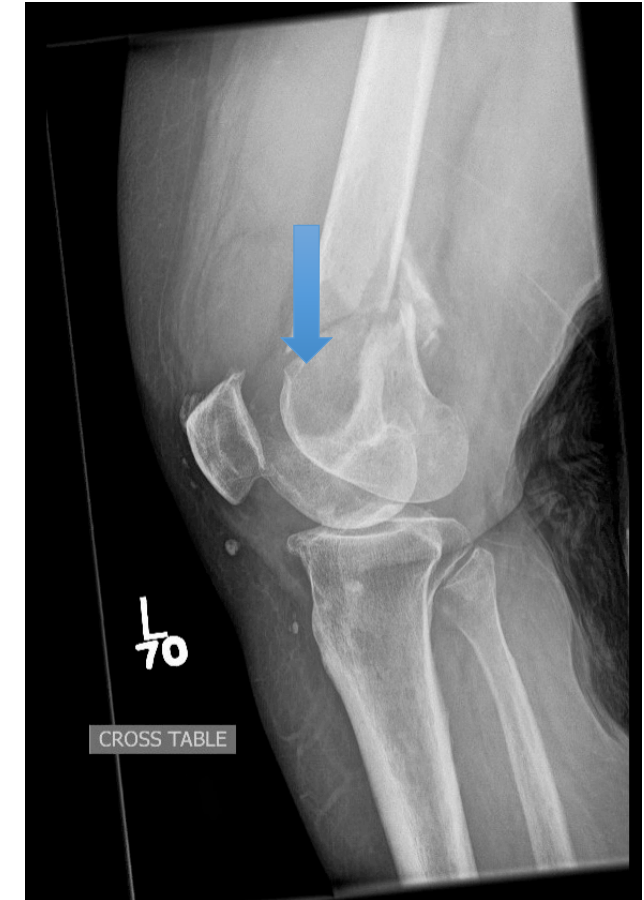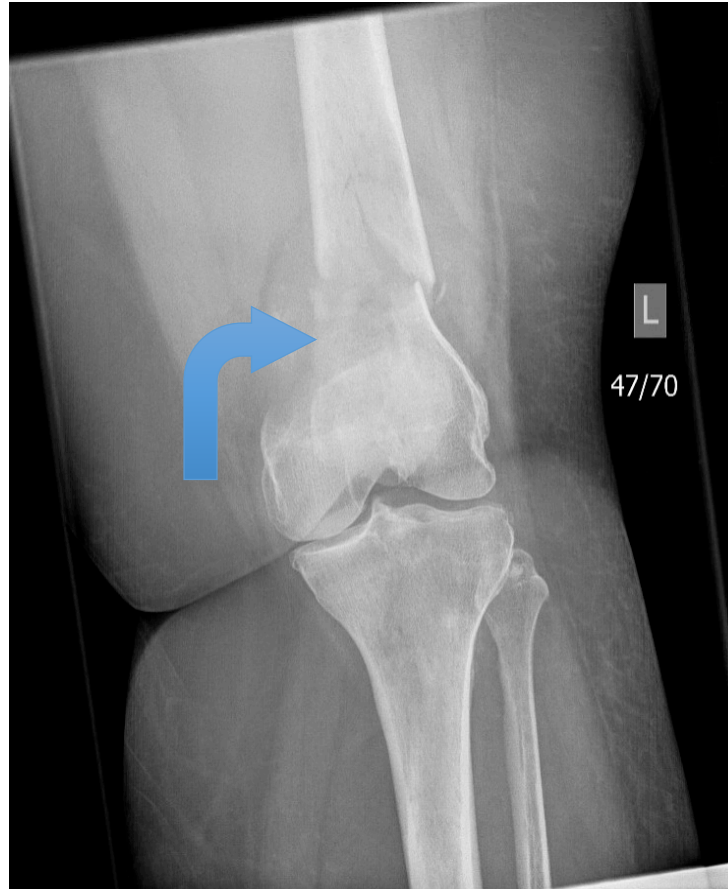
Remaining bone stock: Poor



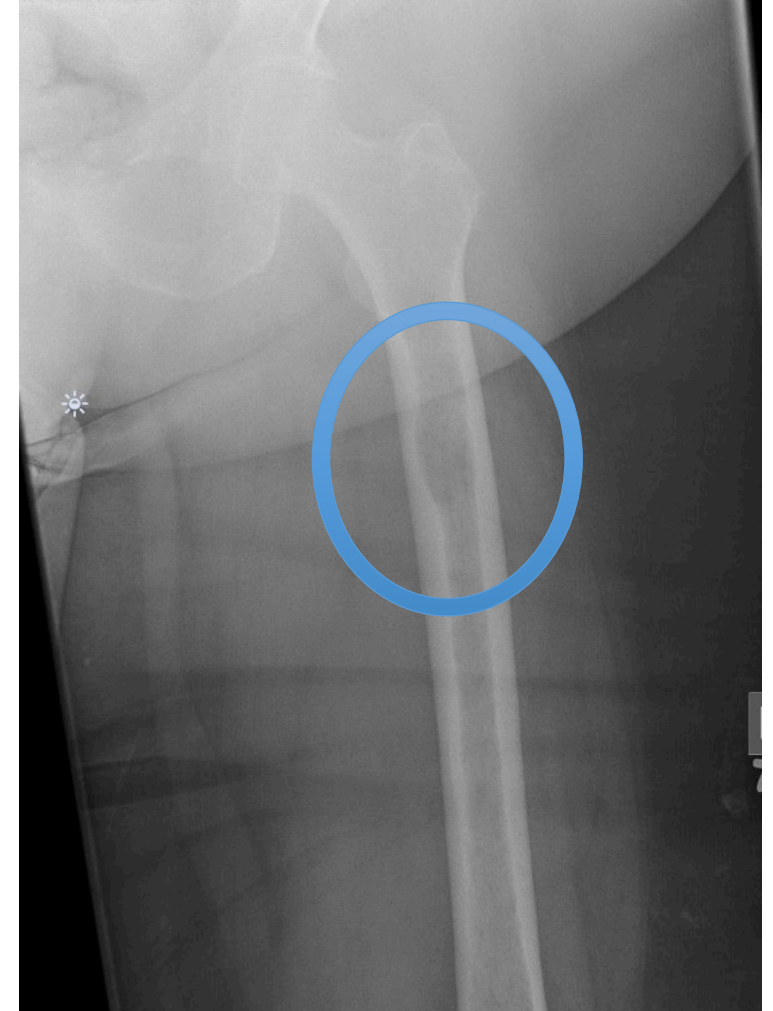
Given location (periarticular) and remaining bone stock for fixation (poor), this patient underwent resection and reconstruction with proximal humerus/reverse total shoulder arthroplasty as this was deemed the most durable reconstructive option. The rotator cuff and pectoralis tendons were secured to the prosthesis with heavy suture. The majority of the deltoid insertion was maintained (which will power the prosthesis), and the remaining portion was also repaired to the prosthesis.

Case Example #3

- 63 year old female presents to ED following a fall
- Radiographs show pathologic fracture through distal femur lesion



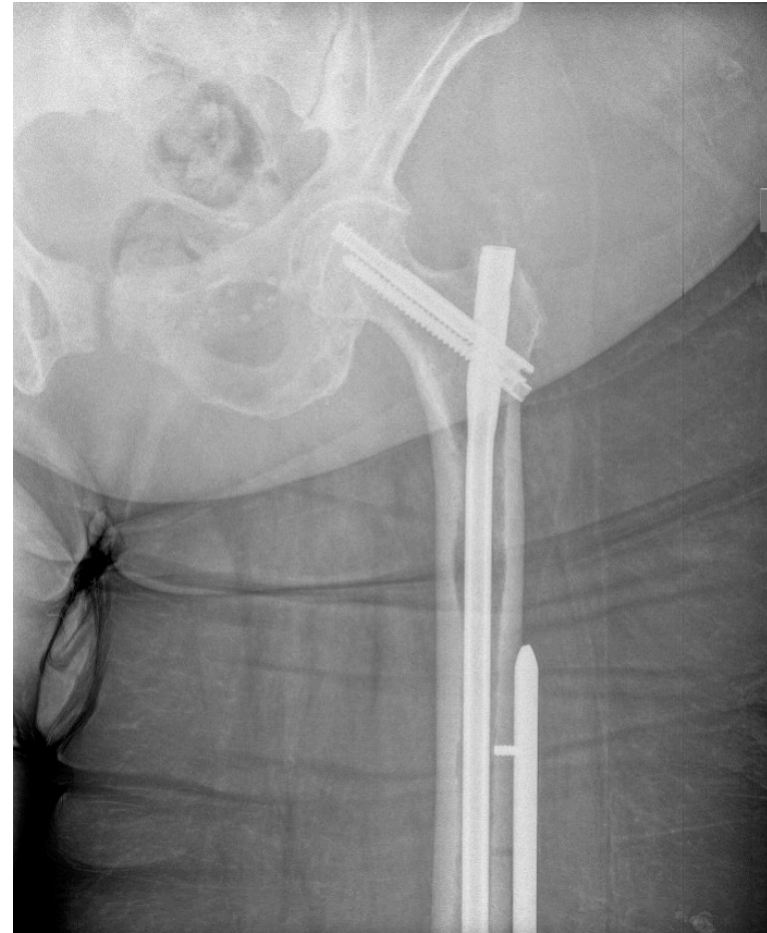
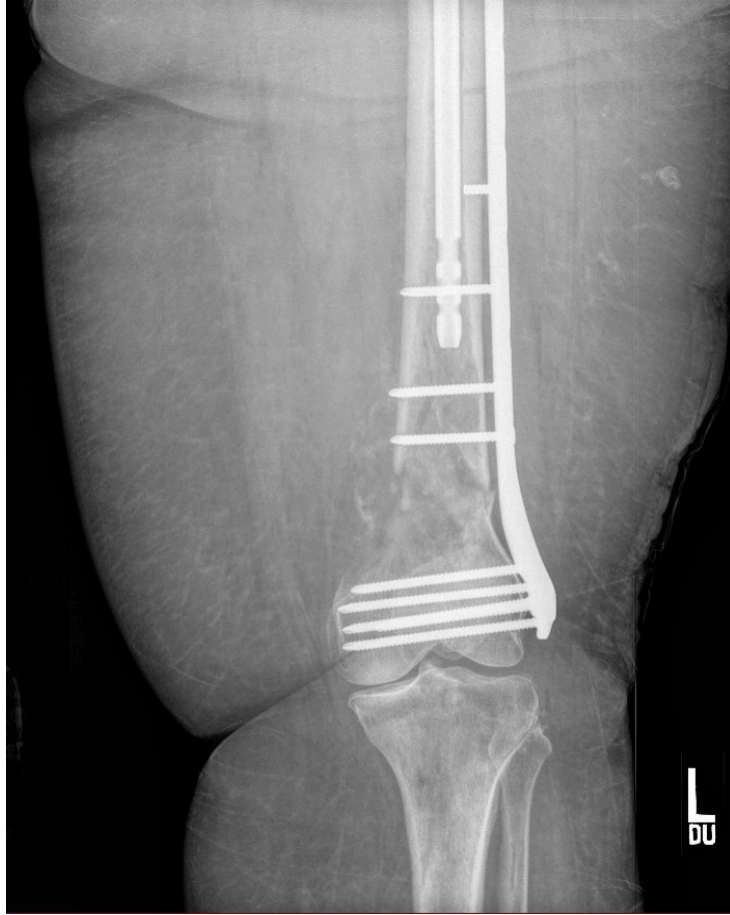- Work-up:
 - Full length femur radiographs: proximal subtrochanteric lesion
 - MRI left femur: lesions corresponding to radiographs; no significant extraosseous mass
 - CT chest/abdomen/pelvis: Innumerable bony lesions, most blastic in appearance, a few pulmonary nodules
 - SPEP: normal
- Plan:
 - Open biopsy with frozen section given high likelihood of metastatic carcinoma; **if (+) for carcinoma**, proceed with planned surgery
 - Pre-op axial imaging shows adequate bone stock distally for fixation
 - Fixation at distal femur with proximal fixation given subtrochanteric lesion



Case Example #3

- 1) Open biopsy with frozen section
 - Antero-lateral through vastus lateralis (one compartment, incision in-line with planned future resection if biopsy showed **sarcoma**)
 - Frozen section showed metastatic carcinoma, likely breast primary

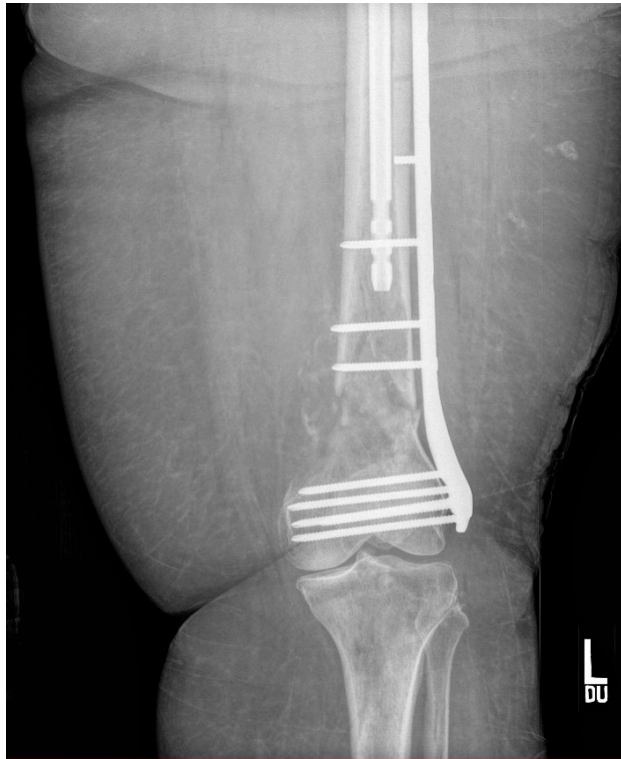- 2) Proceed with planned fixation



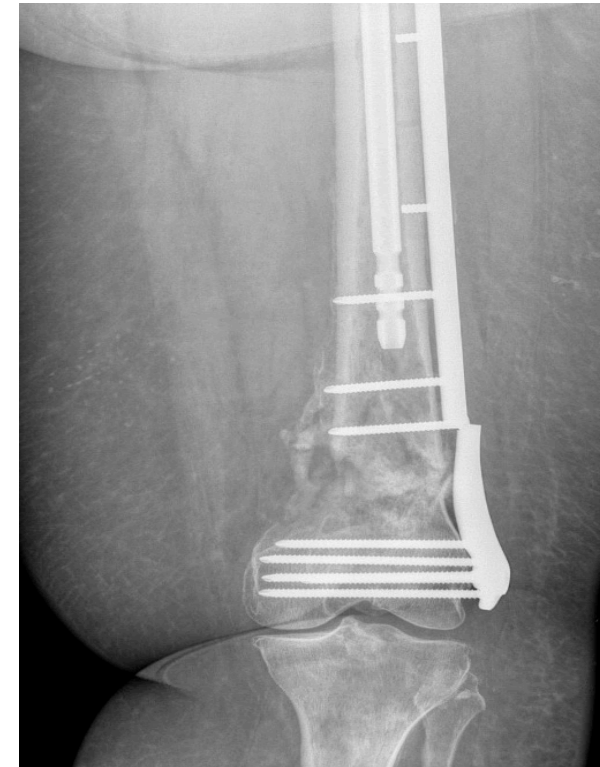Fixation performed using plate/screw construct at distal femur and intramedullary implant to bypass the more proximal subtrochanteric lesion. This patient also received post-op XRT.

Case Example #3: Follow-up

Immediate Post-Fixation



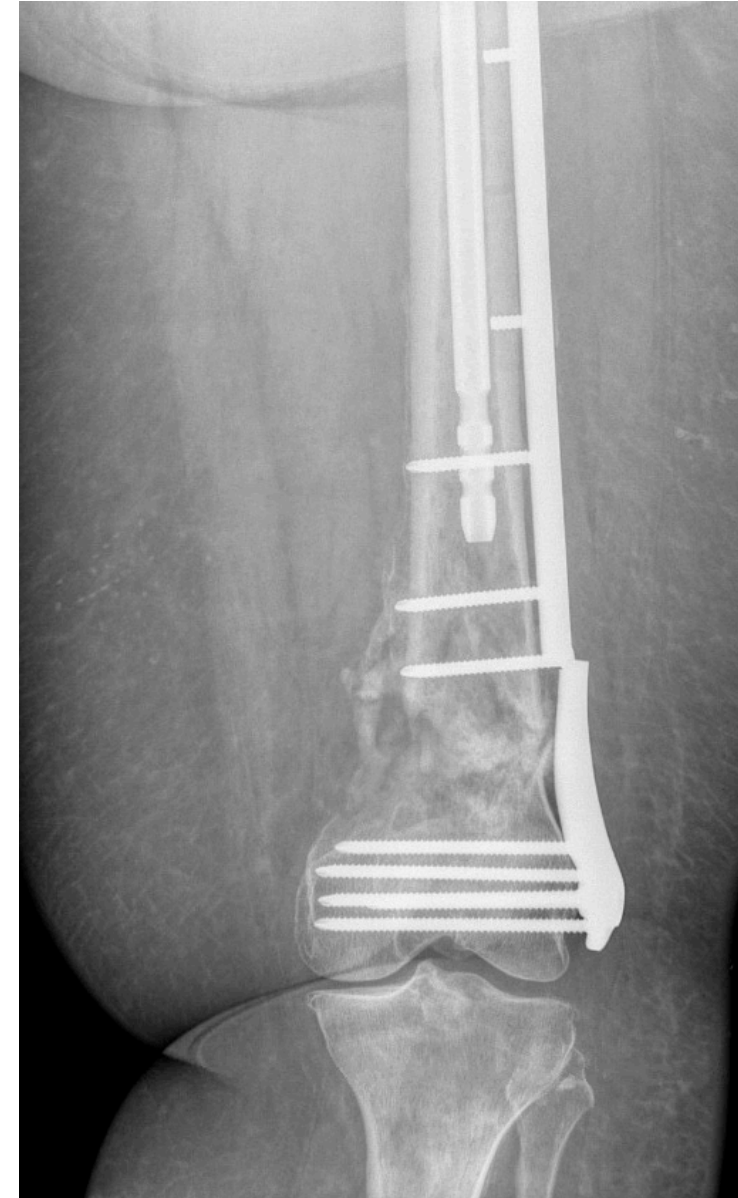6-month Follow-up



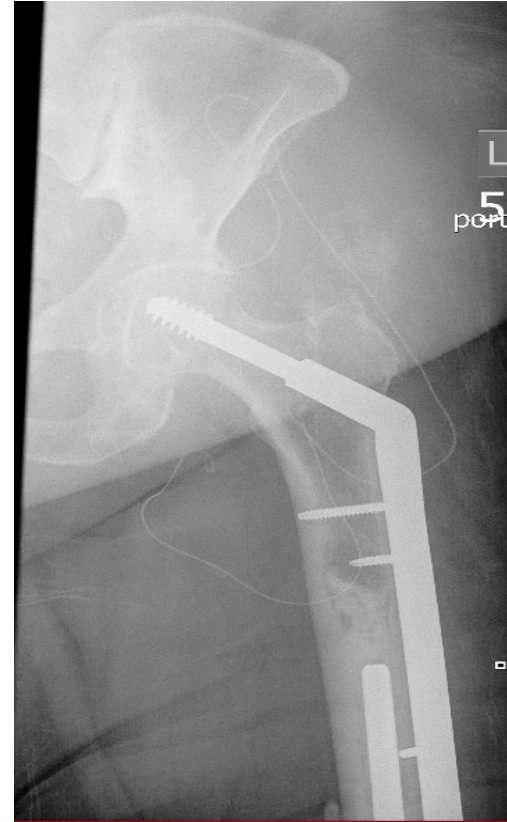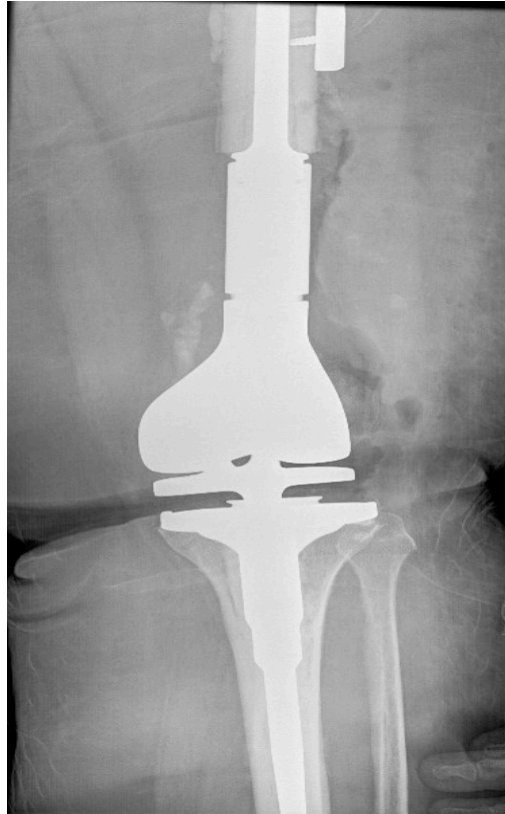
Incomplete healing,
implant failure, and
increased varus
alignment noted

Case Example #3

- Why did this fail?
- Several possible factors:
 - Infection- ruled out with normal ESR/CRP and intraoperative cultures
 - Bone loss/pathologic bone with limited healing potential
 - Breast/Prostate/Myeloma usually respond well to primary treatments and radiation; however, healing rates are still lower than normal bone
 - Postop XRT
 - Perhaps original construct was too rigid; or, construct could have been augmented with PMMA or additional implants, etc. to increase rigidity given lower healing rates in the setting of post-op XRT



Case Example #3:



This patient was ultimately converted to a distal femur arthroplasty and proximal extramedullary implant. Arthroplasty was pursued given history of pathologic bone, poor remaining juxta-articular bone stock, and previous XRT making repair of the nonunion difficult. This construct did not rely on bony healing and also allowed immediate weight bearing.

Summary

- Establish a diagnosis prior to making any surgical decisions
- When in doubt, a well-done biopsy (and frozen section) can help establish a diagnosis
- Prognosis should be estimated, and this may require input from Medical Oncology and Radiation Oncology
- Patients with metastatic disease are living longer, and our role as orthopedic surgeons is to provide a durable reconstruction that allows for immediate weight bearing
- Reconstruction options depend on the primary tumor, location of the lesion, and the amount of bone remaining
- Be prepared to use fixation adjuncts to enhance the durability of the construct

References

- Johnson CN, Gurich RW Jr., Pavey GJ, Thompson MJ. Contemporary Management of Appendicular Skeletal Metastasis by Primary Tumor Type. *J Am Acad Orthop Surg*. 2019 May 15;27(10):345-355.
- Rougraff BT, Kneisl JS, Simon MA. Skeletal Metastases of Unknown Origin. A prospective study of diagnostic strategy. *J Bone Joint Surg Am*. 1993;75:1276-1281.
- Gutowski CJ, Zmistowski B, Boland PJ, Healey JH. Surgical Management of Femoral Metastases in the Era of Biologics: A Shifting Paradigm. *MSTS Annual Meeting Abstract*. 2017.
- Mirels, H. Metastatic Disease in Long Bones. A proposed scoring system for diagnosing impending pathologic fractures. *Clin Orthop Relat. Res*. 1989 Dec;(249):256-64.
- Damron TA, Nazarian A, Entezari V, Brown C, Grant W, Calderon N, Zurakowski D, Terek RM, Anderson ME, Cheng EY, Abouafia AJ, Gebhardt MC, Snyder BD. CT-based Structural Rigidity Analysis Is More Accurate Than Mirels Scoring for Fracture Prediction in Metastatic Femoral Lesions. *Clin Orthop Relat Res* (2016) 474:643-651.
- Anderson AB, Wedin R, Fabbri N, Boland P, Healey J, Forsberg JA. External Validation of PathFx Version 3.0 in Patients Treated Surgically and Non-Surgically for Symptomatic Skeletal Metastases. *Clin. Orthop Relat. Res*. 2019. Publish ahead of print. 1-11.
- Lin PP, Mriza AN, Lewis VO, Cannon CP, Tu SM, Tannir NM, Yasko AW. Patient survival after surgery for osseous metastases from renal cell carcinoma. *J Bone Joint Surg Am*. 2008 Aug;89(*):1794-801.
- Wang X, Yang KH, Wanya P, Tian JH. Comparison of the efficacy and safety of denosumab versus bisphosphonates in breast cancer and bone metastases treatment: A meta-analysis of randomized controlled trials. *Oncol Lett* 2014;7:1997-2002.
- Frassica FJ, Frassica DA: General principles of external beam radiation therapy for skeletal metastases. *Clin Orthop Relat Res*. 2003(415 suppl):S158-S164.
- Lutz S, Balboni T, Jones J, et al. Palliative radiation therapy for bone metastases: Update of an ASTRO evidence-based guideline. *Pract Radiat Oncol* 2017;7:4-12.
- Gardner CS, Ensor J, Ahrar K, Huang SY, Sabir SH, Tannir NM, Lewis VO, Tam AL. Cryoablation of bone metastases from renal cell carcinoma for local tumor control. *J Bone Joint Surg Am*. 2017 (99):22:1916-1926.
- Alvi HM, Damron TA. Prophylactic stabilization for Bone Metastases, Myeloma, or Lymphoma: Do We Need to Protect the Entire Bone? *Clin Orthop Relat Res*. 2013 Mar;471(3):706-714.
- Xing Z, Moon BS, Satcher RL, Lin PP, Lewis VO. A Long Femoral Stem is Not Always Required in Hip Arthroplasty for Patients with Proximal Femur Metastases. *Clin Orthop Relat Res*. 2013 May;471(5):1622-1627.
- Houdek MT, Fegruson PC, Abdel MP, Griffin AM, Hevesi M, Perry K, Rose PS, Wunder JS, Lewallen DF. Comparison of Porous Tantalum Acetabular Implants and Harrington Reconstruction for Metastatic Disease of the Acetabulum. *J Bone Joint Surg Am*. 2020©102(14):1239-1247
- Khan FA, Rose PS, Yanagisawa M, Lewallen DF, Sim FH. Porous Tantalum Reconstruction for Destructive Nonprimary Periacetabular Tumors. *Clin Orthop Relat Res* (2012)470:594-601.
- Houdek MT, Abdel MP, Perry KI, Saldut, A, Rose pS, Sim FH, Lewallen DG. Outcome of Patients Treated With Porous Tantalum Acetabular Implants for Neoplastic Periacetabular Lesions. *J Amer Acad Ortho Sur*. 2020; (28)6:256-262.