

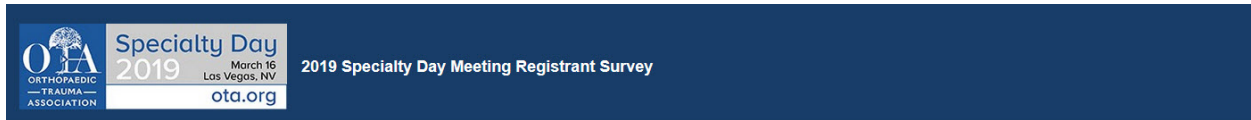

**Session II: Postoperative Complications:
How to Get Out of this Mess (Case Based at Your Request)**

Resolve or Refer 1 and 2

8:25am - 8:55am

Thank you for attending this OTA Specialty Day Meeting. This year a unique format is offered to address previous participant suggestions and needs. Twelve clinical scenarios requiring surgical revision have been selected by two moderators and 4 expert panelists. To invite audience participation and address your concerns and clinical dilemmas we asked you to select 4 of the 12 below. Those that received the most votes are being reviewed by the moderators and panelists in advance of the meeting and pearls and caveats offered. Methods to avoid adverse outcome and surgical means towards resolution will be emphasized.



Thank you for registering for the forthcoming OTA Specialty Day Meeting to be held March 16th, 2019 at the annual meeting of the American Academy of Orthopaedic Surgeons in Las Vegas, Nevada.

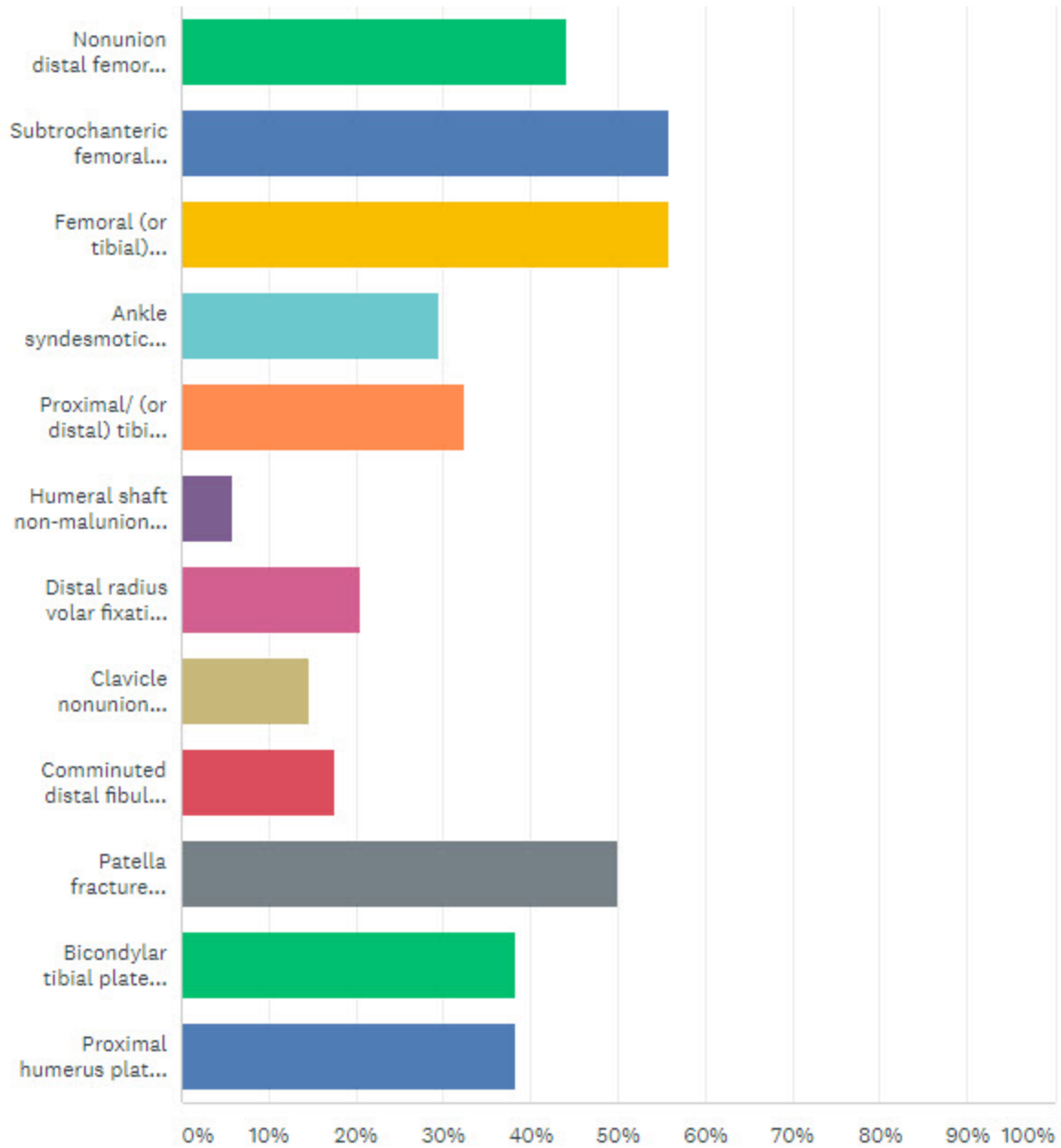
A unique format will be offered entitled "Resolve or Refer" to address previous participant suggestions and needs. Twelve clinical scenarios requiring surgical revision have been selected by two moderators and 4 expert panelists. To invite audience participation and address your concerns and clinical dilemmas we ask you to select 4 of the 12 below.

Those that receive the most votes will be reviewed (4-6 total) by moderators/panelists in advance of the meeting and pearls and caveats offered. Methods to avoid adverse outcome and surgical means towards resolution will be emphasized.

Please only choose 4:

- | | |
|--|---|
| <input type="checkbox"/> Nonunion distal femoral fracture s/p locked plating | <input type="checkbox"/> Distal radius volar fixation failure |
| <input type="checkbox"/> Subtrochanteric femoral fracture managed with intramedullary nail with malreduction | <input type="checkbox"/> Clavicle nonunion subsequent to operative fixation |
| <input type="checkbox"/> Femoral (or tibial) intramedullary sepsis s/p intramedullary fracture fixation | <input type="checkbox"/> Comminuted distal fibular fracture malreduction |
| <input type="checkbox"/> Ankle syndesmotic malreduction requiring surgical resolution | <input type="checkbox"/> Patella fracture fixation failure |
| <input type="checkbox"/> Proximal/ (or distal) tibial fracture managed with intramedullary nailing requiring surgical revision | <input type="checkbox"/> Bicondylar tibial plateau fracture (inadequate medial construct) |
| <input type="checkbox"/> Humeral shaft non-malunion after insufficient fixation | <input type="checkbox"/> Proximal humerus plating with construct failure |

Comments:



RESOLVE OR REFER 1

Moderator; Stephen Kottmeier MD

Panelists : J Tracy Watson MD / Paul Tornetta III MD

RESOLVE OR REFER 2

Moderator; Clifford B Jones MD

Panelists : Heather Vallier MD / Philip Wolinsky MD