

Hip Dislocations and Femoral Head Fractures

Fernando Serna, MD

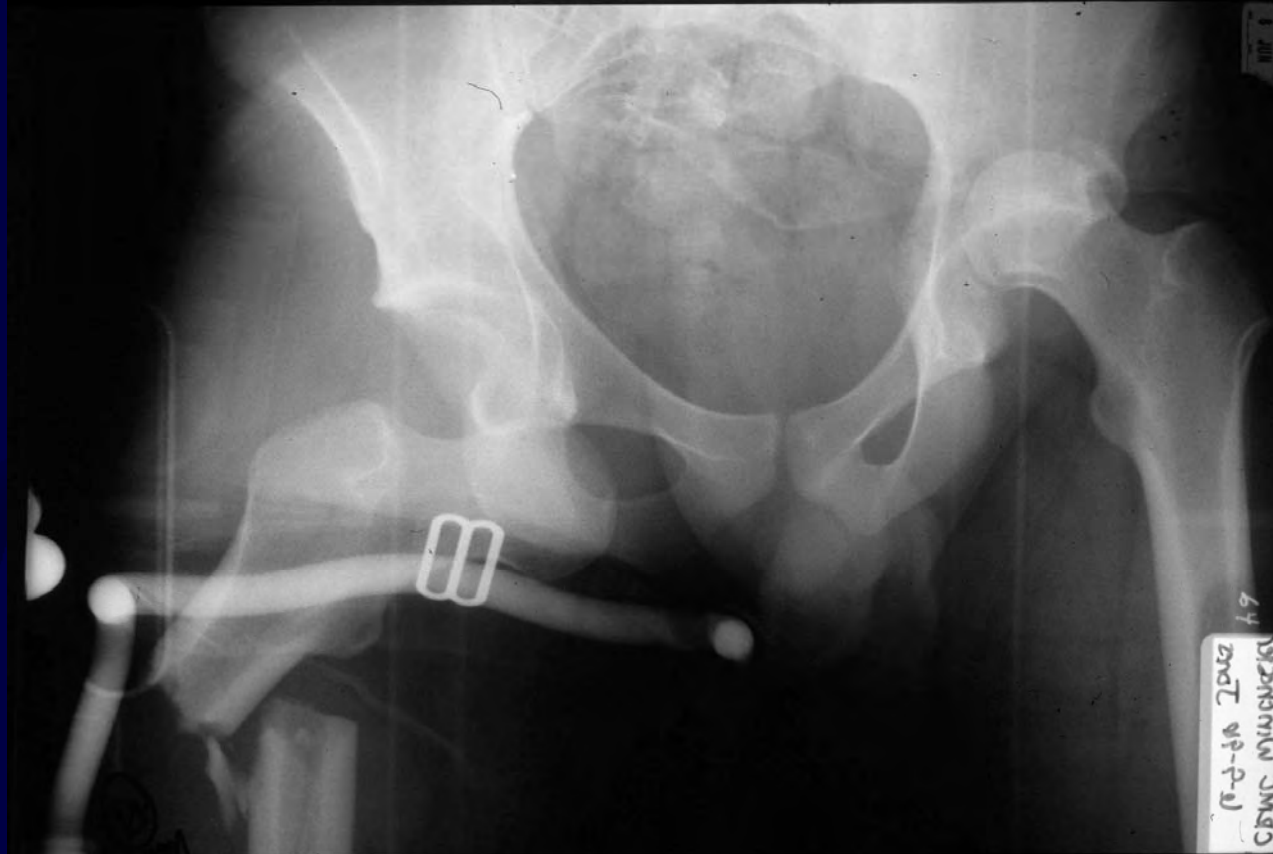
John T. Gorczyca, MD

University of Rochester Medical Center

Created March 2004; First Revision January 2006

Second Revision July 2009

Introduction



Hip dislocations caused by significant force:

- Association with other fractures
- Damage to vascular supply to femoral head

Thus, high chance of complications

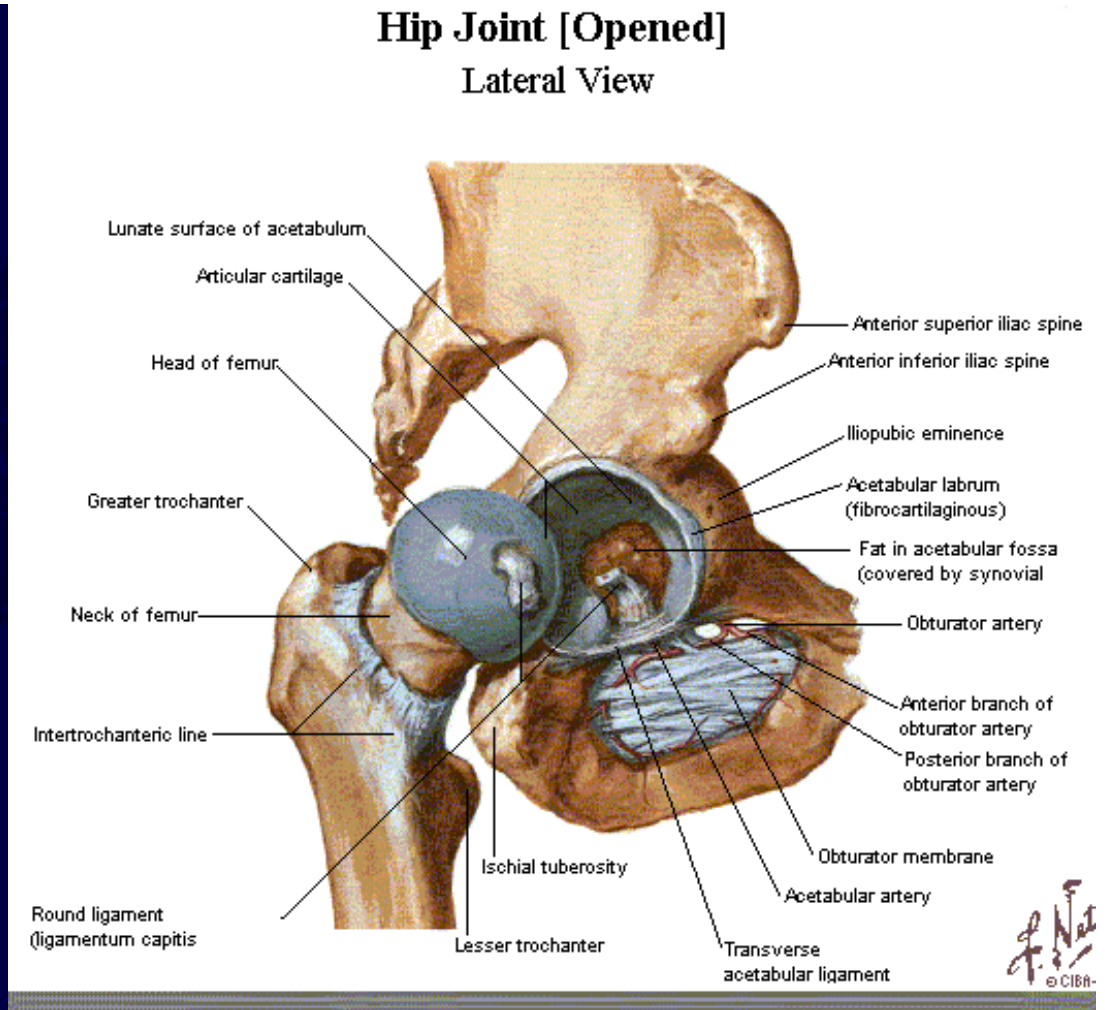
Anatomy: Hip Joint

Ball and socket joint.

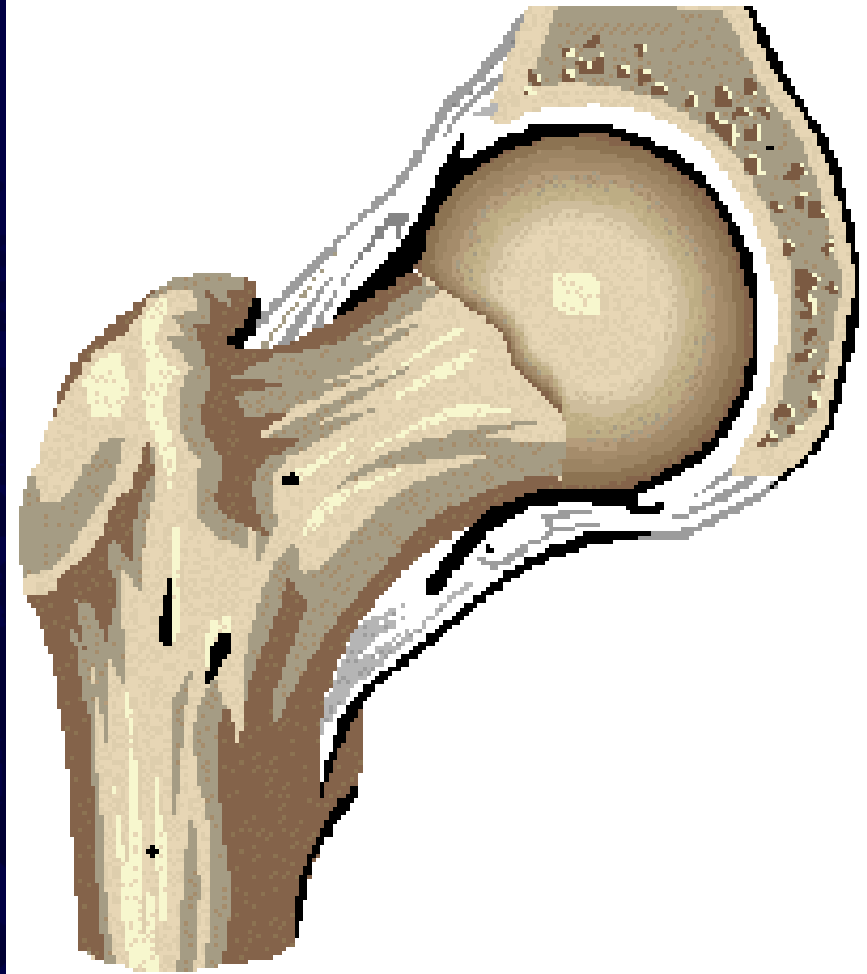Femoral head: slightly asymmetric, forms 2/3 sphere.

Acetabulum: inverted “U” shaped articular surface.

Ligamentum teres, with artery to femoral head, passes through middle of inverted “U”.



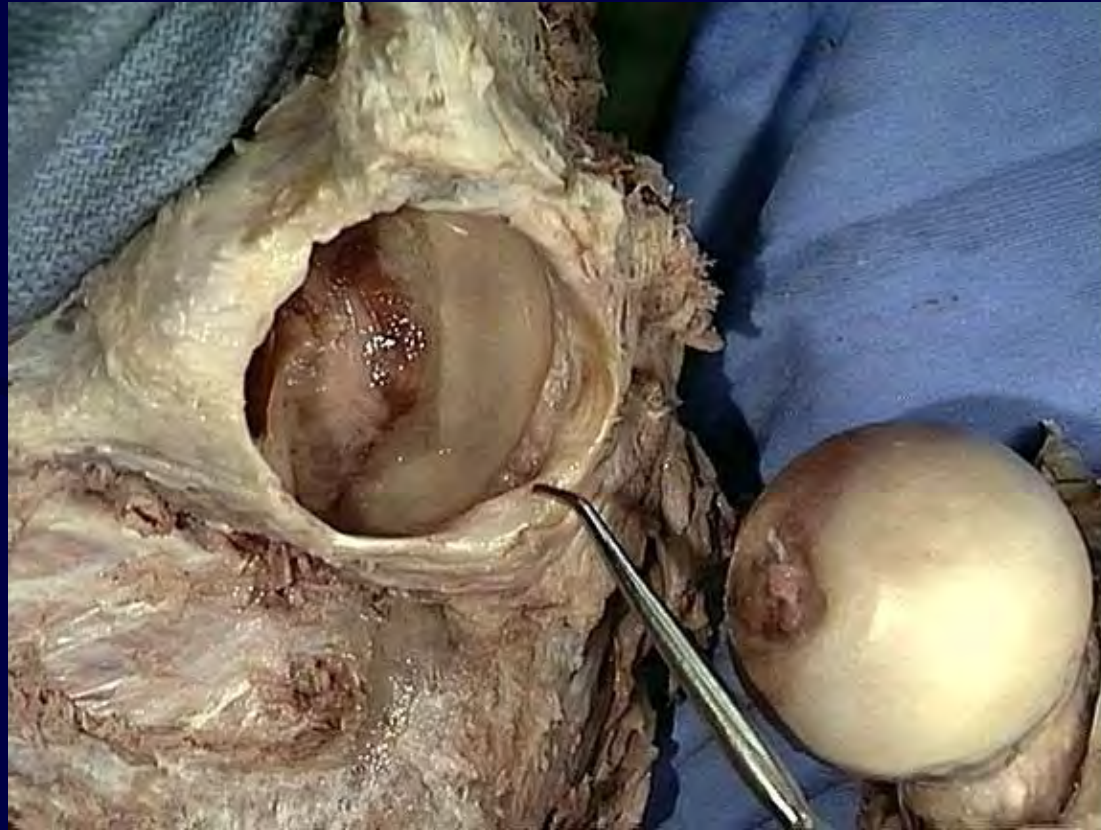Joint Contact Area



Throughout ROM:

- 40% of femoral head is in contact with acetabular articular cartilage.
- 10% of femoral head is in contact with labrum.

Acetabular Labrum



Strong fibrous ring

Increases femoral head coverage

Contributes to hip joint stability

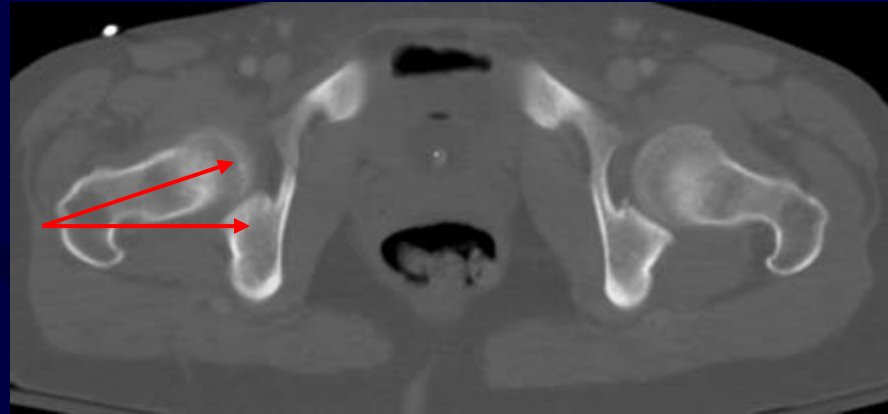
Hip Joint Capsule

- Extends from intertrochanteric ridge of proximal femur to bony perimeter of acetabulum
- Has several thick bands of fibrous tissue

Iliofemoral ligament

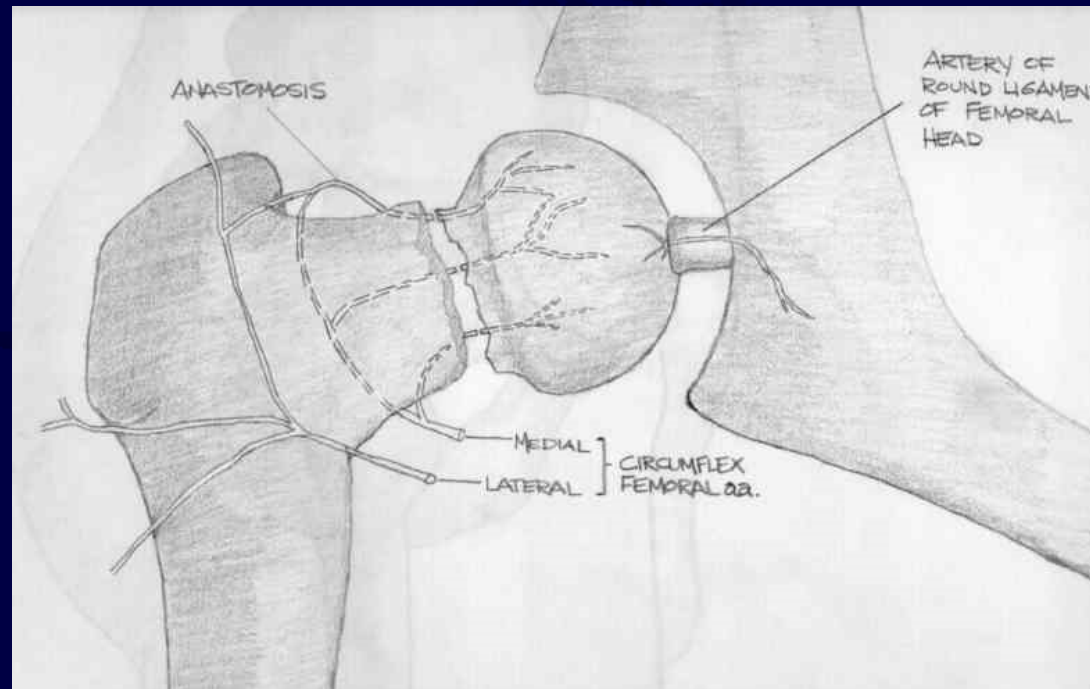
- Upside-down “Y”
- Blocks hip hyperextension
- Allows muscle relaxation with standing

Femoral Neck Anteversion



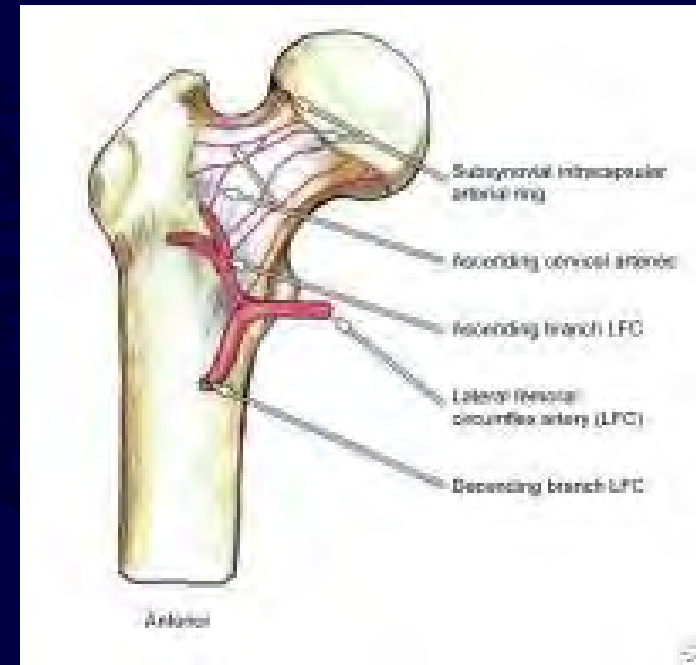- Averages 7° in Caucasian males.
- Slightly higher in females.
- Asian males and females have been noted to have anteversion of 14° and 16° respectively.

Blood Supply to Femoral Head



1. Artery of Ligamentum Teres
 - Most important in children.
 - Its contribution decreases with age, and is probably insignificant in elderly patients.

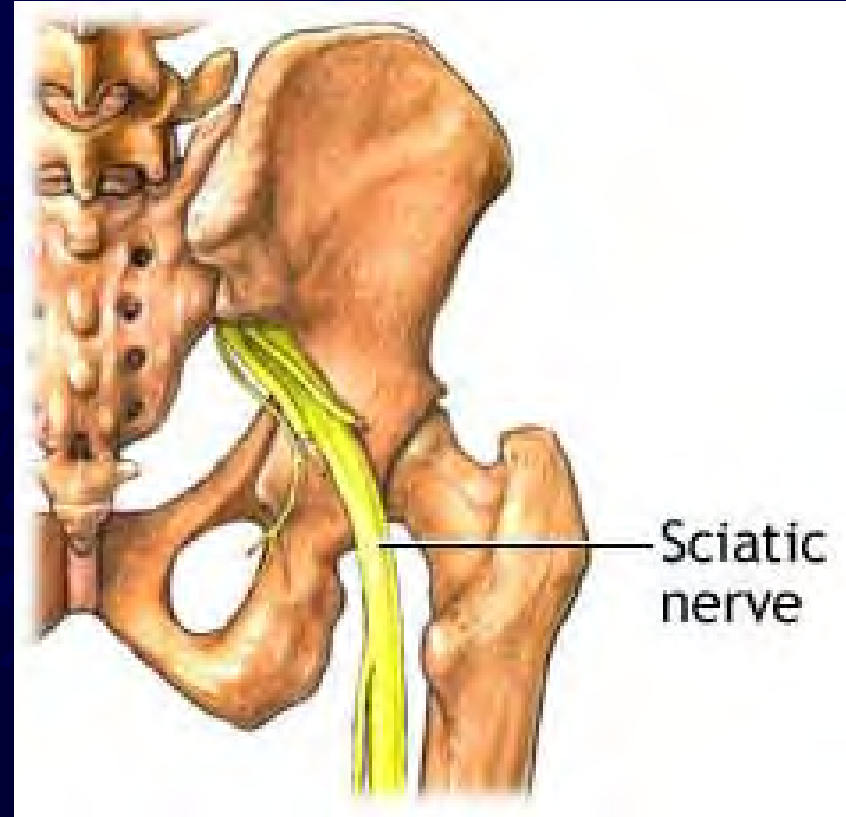
Blood Supply to Femoral Head



2. Ascending Cervical Branches

- Arise from ring at base of neck.
- Ring is formed by branches of medial and lateral circumflex femoral arteries.
- Penetrate capsule near its femoral attachment and ascend along neck.
- Perforate bone just distal to articular cartilage.
- Highly susceptible to injury with hip dislocation.

Sciatic Nerve



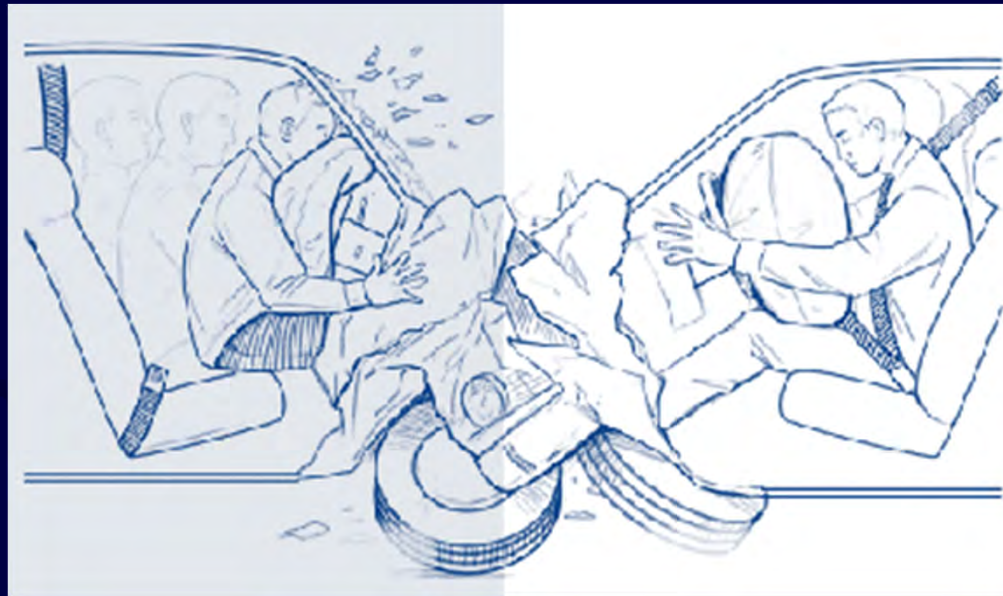Composed from roots of L4 to S3.

Peroneal and tibial components differentiate early, sometimes as proximal as in pelvis.

Passes posterior to posterior wall of acetabulum.

Generally passes inferior to piriformis muscle, but occasionally the piriformis will split the peroneal and tibial components

Posterior Hip Dislocation: Mechanism of Injury

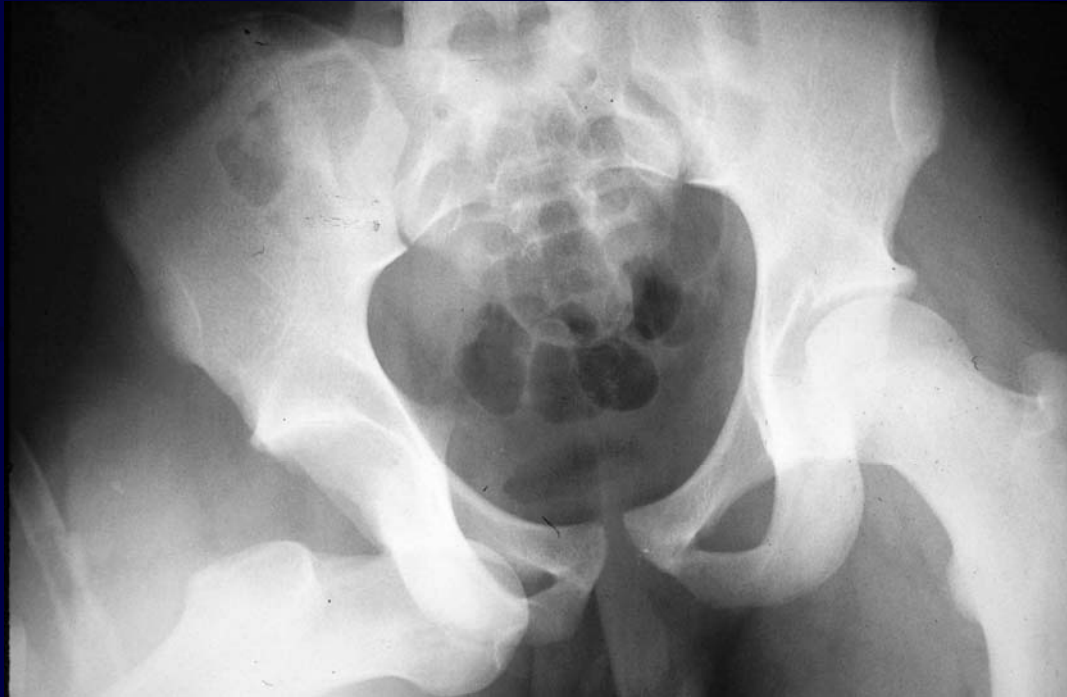

Almost always due to high-energy trauma.

Most commonly involve unrestrained occupants in MVAs.

Can also occur in pedestrian-MVAs, falls from heights, industrial accidents and sporting injuries.

Posterior Dislocation



- Generally results from axial load applied to femur, while hip is flexed.
- Most commonly caused by impact of dashboard on knee.

Type of Posterior Dislocation depends on:

Direction of applied force.

Position of hip.

Strength of patient's bone.



Hip Position vs. Type of Posterior Dislocation

In General,

Abduction: acetabulum fracture-dislocation

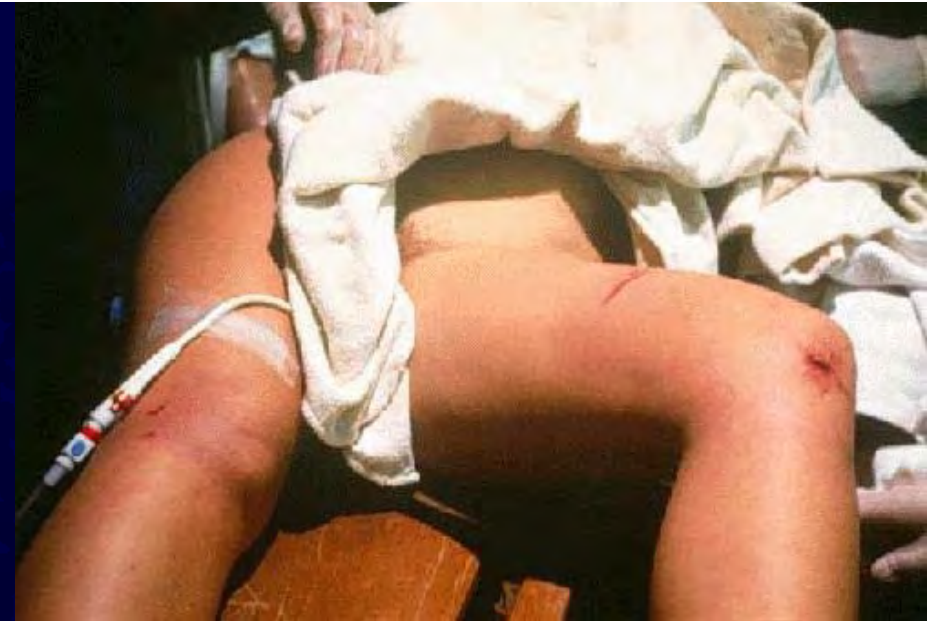Adduction: pure dislocation

Extension: femoral head fracture-dislocation

Flexion: pure dislocation

Anterior Dislocation

7-10% of hip dislocations



Mechanism:

- Forced abduction with external rotation of hip.
- Anterior hip capsule is torn or avulsed.
- Femoral head is levered out anteriorly.

Effect of Dislocation on Femoral Head Circulation

Posterior dislocation of cadaveric hips results in statistically significant filling defects in the common femoral and circumflex arteries on cine-fluoroscopic vessel examination.

- In some cases, collateral circulation maintained intraosseous blood flow.
- Posited that AVN results from immediate ischemia at time of injury and from progressive and delayed arterial damage.

Yue et al (*J Orthop Trauma* 1996)

Effect of Dislocation on Femoral Head Circulation

- Injury to ascending cervical branches associated with damage to capsule during dislocation.
- Dislocation disrupts artery of ligamentum teres.
- Dislocated hip may kink or compress ascending cervical branches until the hip is reduced.

Thus, early reduction of the dislocated hip can improve blood flow to femoral head.

Associated Injuries

Mechanism: high-energy, unrestrained vehicle occupants.

Sahin et al reported 71% associated injuries in patients with traumatic hip dislocations and fracture-dislocations.

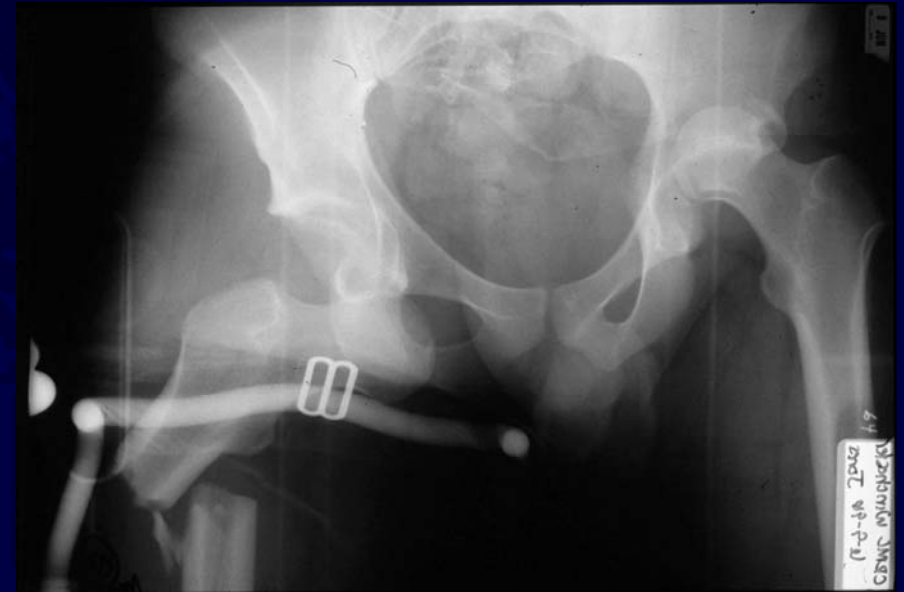
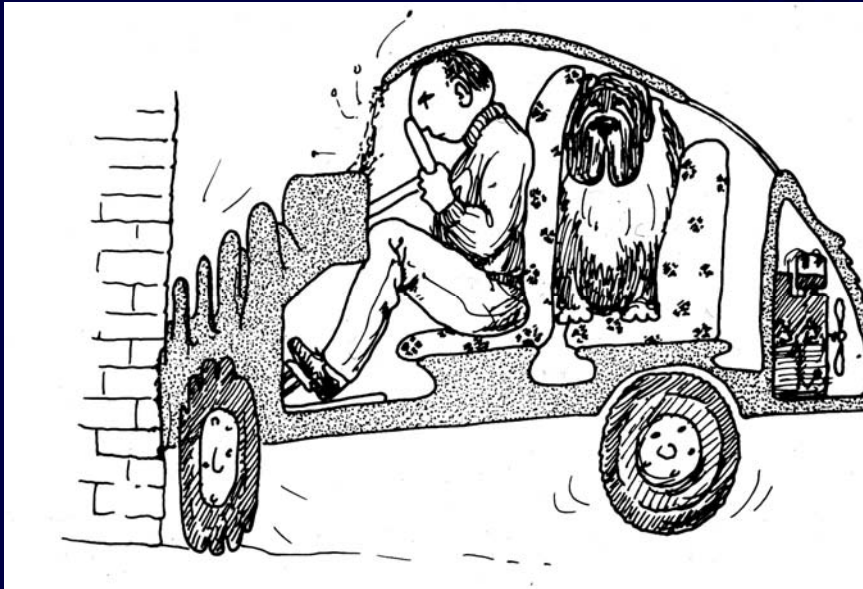(J Trauma 2003)

Hak and Goulet reported 95% associated injuries in patients with hip dislocations.

- Only 33% had isolated orthopaedic injuries.
- 24% head, 21% craniofacial, and 21% thoracic injuries.
- **General Surgery/Trauma evaluation warranted in all hip dislocation patients.**

(J Trauma 1999)

Associated Injuries



Mechanism: knee vs. dashboard

Contusions of distal femur

Patella fractures

Foot fractures, if knee extended

Associated Knee Injuries

25% (46 of 187) of hip injury patients had knee injury.

- 27 acetabulum fractures without dislocation, 10 pure hip dislocation, and 9 acetabulum fx-dislocations.
 - 85% had symptoms or clinical findings of knee injury.
 - 13 fractures (7 patella, 5 supracondylar femur or tibial plateau, 1 osteochondral), 9 ligamentous injury (2 knee dislocations, 1 MCL, 1 LCL, 5 combined), 1 patellar tendon tear, and multiple wounds and contusions
 - 75% had other injuries
- Underscores the need for vigilance in detecting these injuries.

Tabuenca and Truan (*CORR* 2000)

Associated Injuries

Sciatic nerve injuries occur in 10% of adult and 5% of pediatric hip dislocations.

Most commonly, these resolve with reduction of hip and passage of time.

Stretching or contusion most common.

Piercing or transection of nerve by bone can occur.

Classification

Multiple systems exist.

Many reflect outmoded evaluation and treatment methods.

Thompson and Epstein Classification of Hip Dislocations

(Most well-known)

- | | |
|----------|--|
| Type I | Pure dislocation with at most a small posterior wall fragment. |
| Type II | Dislocation with large posterior wall fragment. |
| Type III | Dislocation with comminuted posterior wall. |
| Type IV | Dislocation with “acetabular floor” fracture (probably transverse + post. wall acetabulum fracture-dislocation). |
| Type V | Dislocation with femoral head fracture. |

Thompson and Epstein, *J Bone and Joint Surg*, 1951

Epstein Classification of Anterior Hip Dislocations

Type I Superior (pubic and subspinous)

Type II Inferior (obturator and perineal)

A No associated fracture

B Associated fracture of the femoral head/neck

C Associated fracture of the acetabulum

i.e, Type IA, IIB, etc.

Epstein, *Clin Orthop Relat Res*, 1973.

AO/OTA Classification

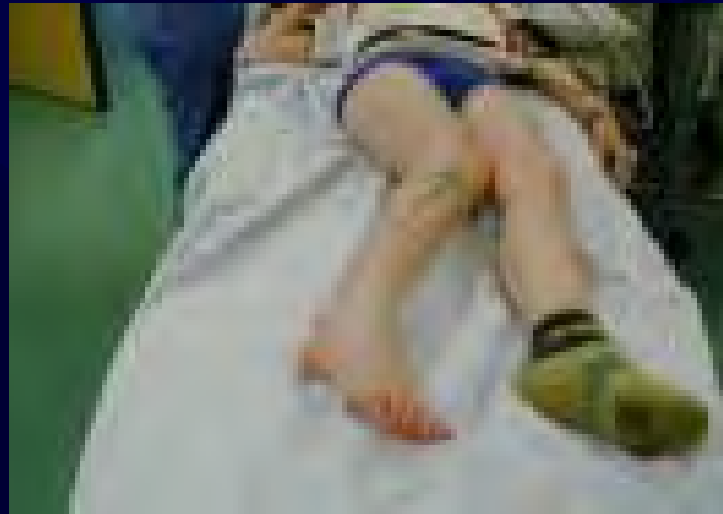- Most thorough.
- Best for reporting data, to allow comparison of patients from different studies.
- 30-D10 Anterior Hip Dislocation
- 30-D11 Posterior Hip Dislocation
- 30-D30 Obturator (Anterior-Inferior)
 Hip Dislocation

Evaluation: History

Significant trauma, usually MVA.

Awake, alert patients have severe pain in hip region.

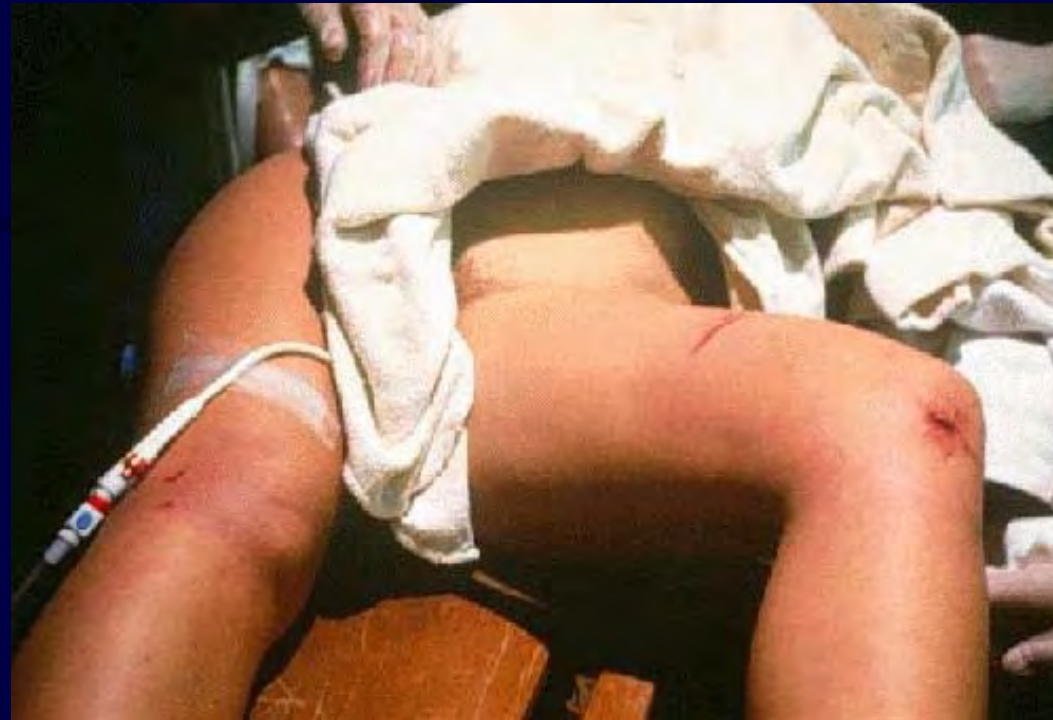Physical Examination: Classical Appearance



Posterior Dislocation:

Hip flexed, internally rotated, adducted.

Physical Examination: Classical Appearance



Anterior Dislocation:

Extreme external rotation,
less-pronounced abduction
and flexion.

Unclassical presentation (posture) if:

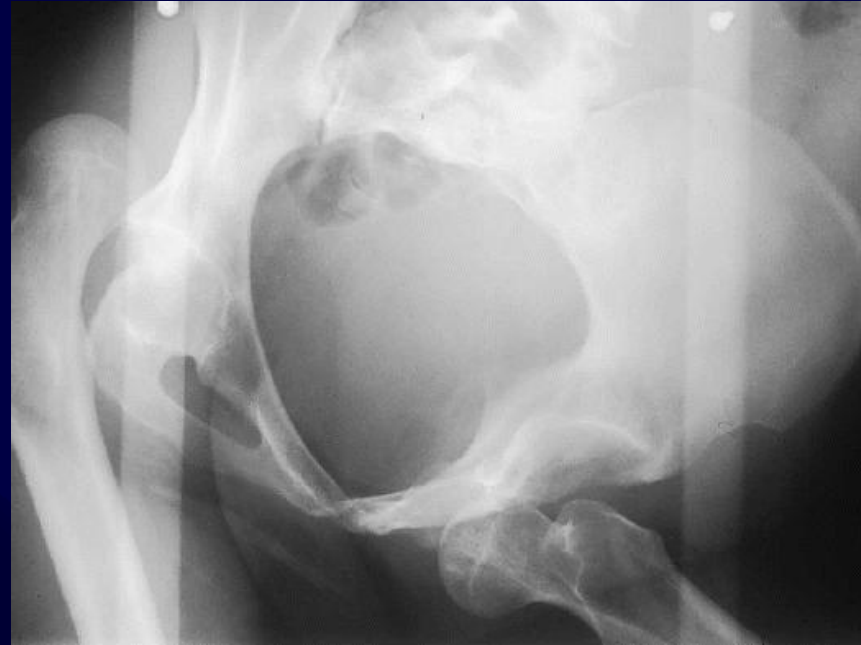- femoral head or neck fracture
- femoral shaft fracture
- obtunded patient

Physical Examination

- Pain to palpation of hip.
- Pain with attempted motion of hip.
- Possible neurological impairment:

Thorough exam essential!

Radiographs: AP Pelvis X-Ray

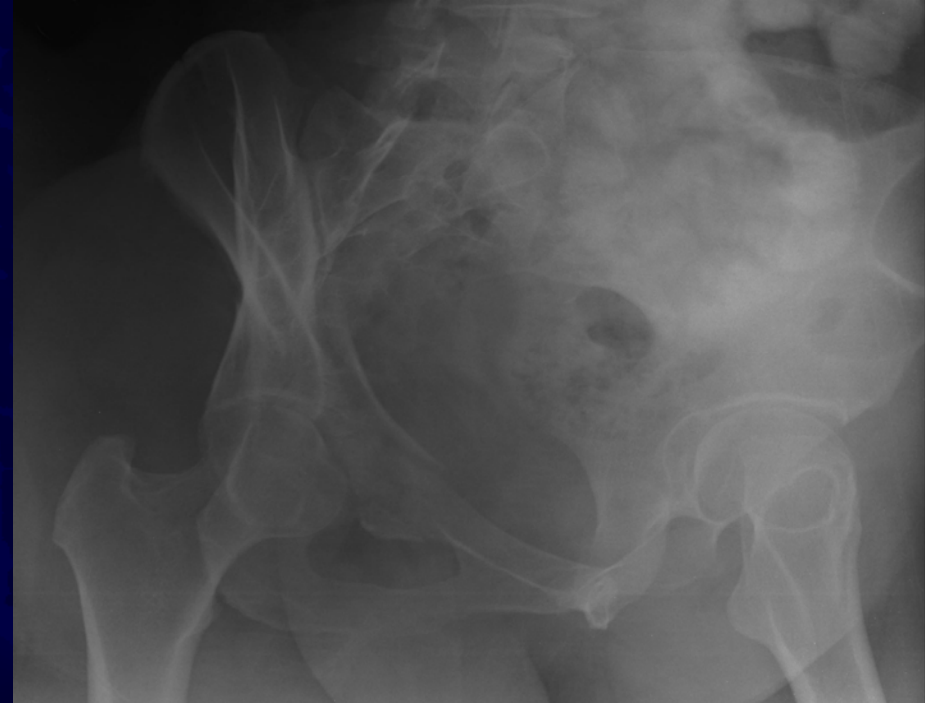
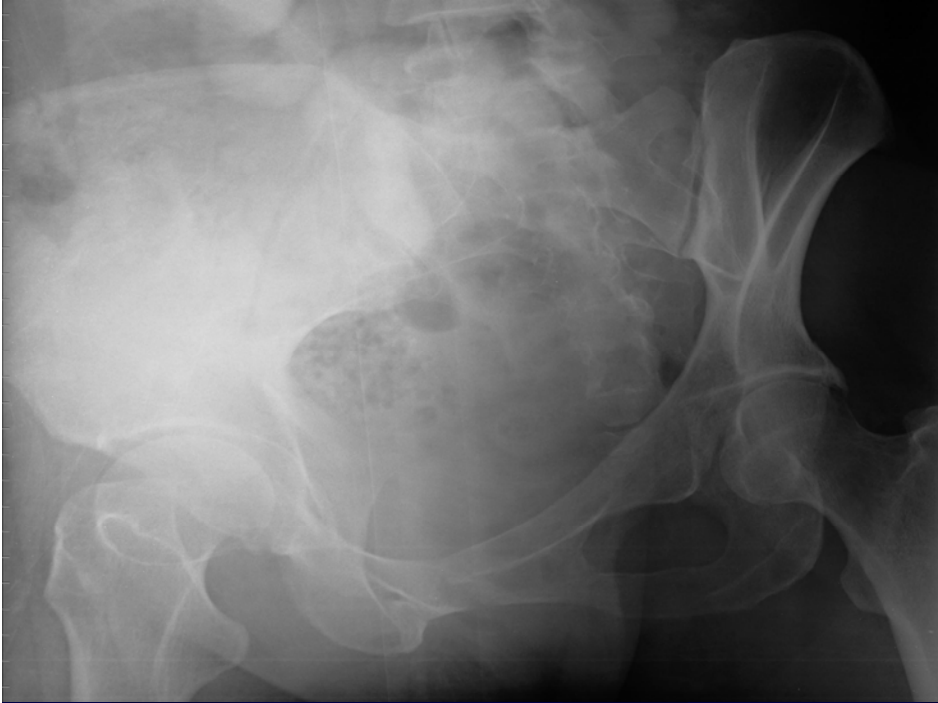
- In primary survey of ATLS Protocol.
- Should allow diagnosis and show direction of dislocation.
 - Femoral head not centered in acetabulum.
 - Femoral head appears larger (anterior) or smaller (posterior).
- Usually provides enough information to proceed with closed reduction.

Reasons to Obtain More X-Rays Before Hip Reduction

- View of femoral neck inadequate to rule out fracture.
- Patient requires CT scan of abdomen/pelvis for hemodynamic instability
 - and additional time to obtain 2-3 mm cuts through acetabulum + femoral head/neck would be minimal.

X-rays after Hip Reduction:



- AP pelvis, Lateral Hip x-ray.
- Judet views of pelvis.
- CT scan with 2-3 mm cuts.

CT Scan

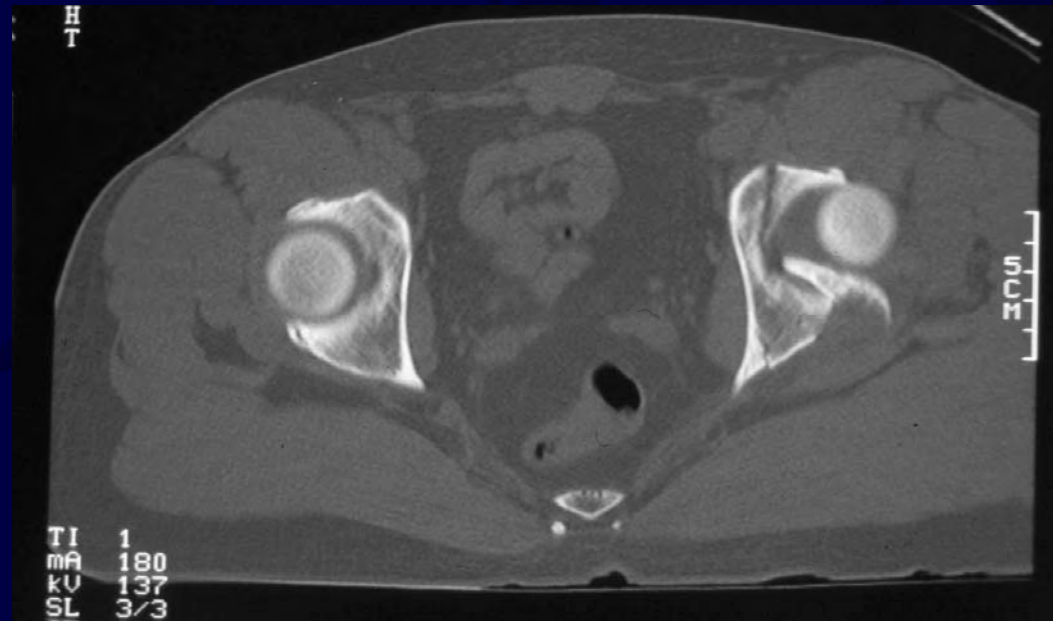
Most helpful after hip reduction.

Reveals: Non-displaced fractures.

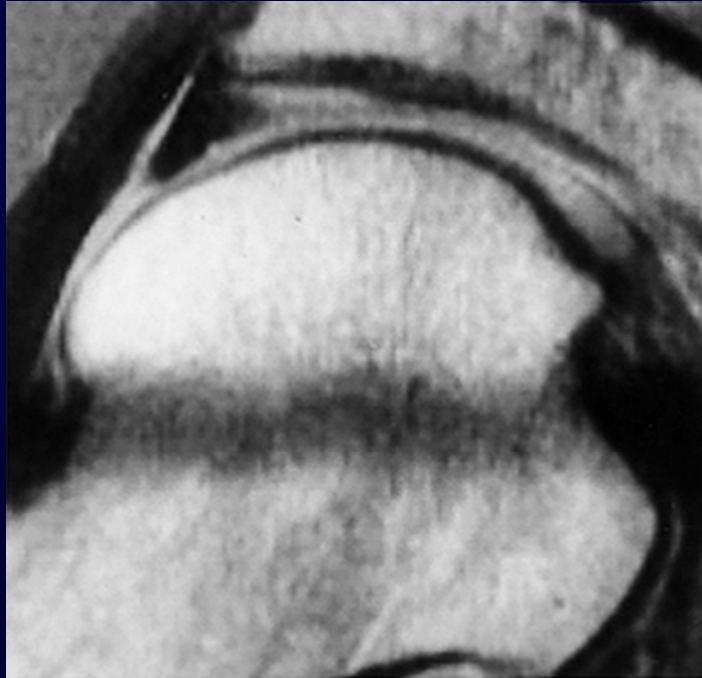
Congruity of reduction.

Intra-articular fragments.

Size of bony fragments.



MRI Scan



- Will reveal labral tear and soft-tissue anatomy.
- Has not been shown to be of benefit in acute evaluation and treatment of hip dislocations.

Clinical Management: Emergent Treatment

- Dislocated hip is an emergency.
- Goal is to reduce risk of AVN and DJD.
- Evaluation and treatment must be streamlined.

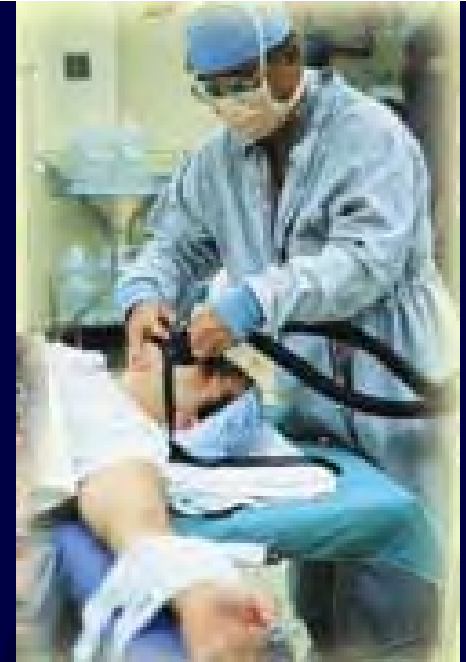Emergent Reduction

- Allows restoration of flow through occluded or compressed vessels.
- Requires proper anesthesia.
- Requires “team” (i.e. more than one person).

Time to reduction

- Controversy in the literature regarding appropriate timing to reduction
 - Marchetti, Steinberg, and Coumas (*J Orthop Trauma* 1996) found no statistically significant difference in outcomes in posterior fracture-dislocations when reduced greater or less than 6 hrs from time of injury
 - Mehlman et al (*CORR* 2000) demonstrated a 20X greater risk of AVN in pediatric traumatic hip dislocations if reduction delayed > 6 hrs
 - Sahin et al (*J Trauma* 2003) demonstrated better prognosis in hip dislocations and fracture-dislocations reduced within 12 hrs
- Universally agreed that the earlier the better

Anesthesia



- General anesthesia with muscle relaxation facilitates reduction, but is not necessary.
- Conscious sedation is acceptable.
- Attempts at reduction with inadequate analgesia/ sedation will cause unnecessary pain, create muscle spasm, and make subsequent attempts at reduction more difficult.

General Anesthesia if:

- Patient is to be intubated emergently in Emergency Room.
- Patient is being transported to Operating Room for emergent head, abdominal or chest surgery.
- Take advantage of opportunity.

Reduction Maneuvers

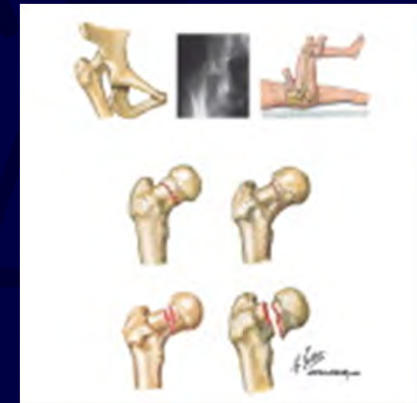
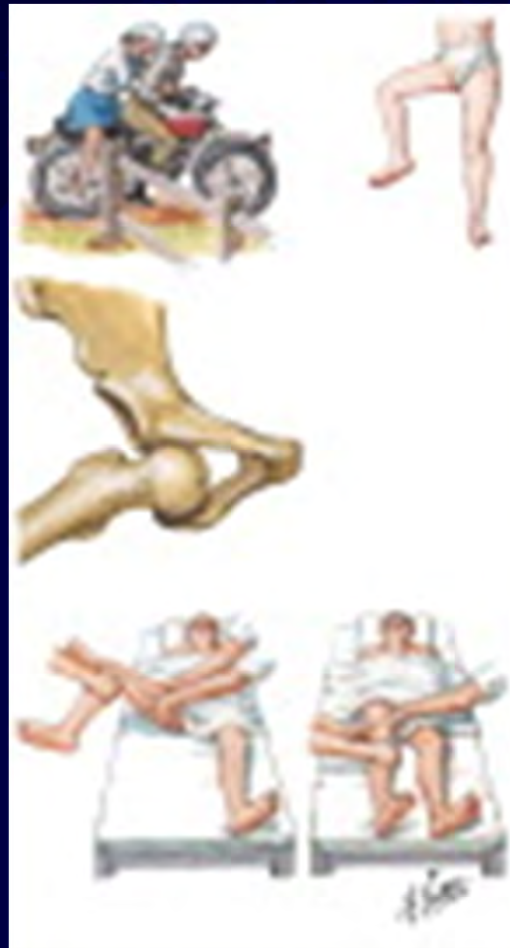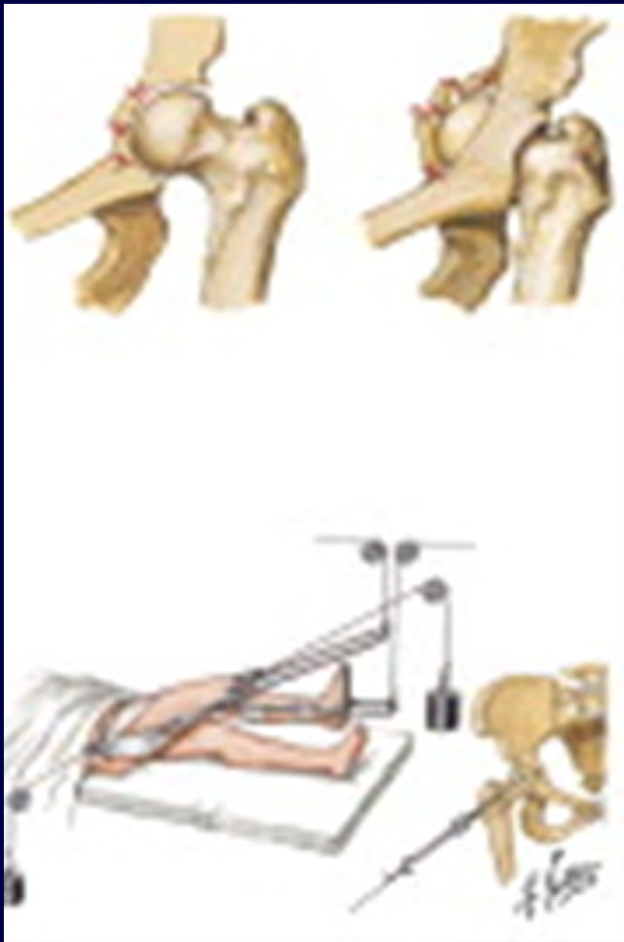
Allis: Patient supine.
Requires at least two people.

Stimson: Patient prone, hip flexed and leg off stretcher.
Requires one person.
Impractical in trauma (i.e. most patients).

Allis Maneuver

- Assistant: Stabilizes pelvis
 - Posterior-directed force on both ASIS's
- Surgeon: Stands on stretcher
- Gently flexes hip to 90⁰
- Applies progressively increasing traction to the extremity
- Applies adduction with internal rotation
- Reduction can often be seen and felt

Allis Maneuver



Reduced Hip

- Moves more freely
- Patient more comfortable
- Requires testing of stability
- Simply flexing hip to 90° does not sufficiently test stability

Stability Test

1. Hip flexed to 90°
2. If hip remains stable, apply internal rotation, adduction and posterior force.
3. The amount of flexion, adduction and internal rotation that is necessary to cause hip dislocation should be documented.
4. Caution!: Large posterior wall fractures may make appreciation of dislocation difficult.

Irreducible Hip

Requires emergent reduction in O.R.

Pre-op CT obtained if it will not cause delay.

One more attempt at closed reduction in O.R. with anesthesia.

- Repeated efforts not likely to be successful and may create harm to the neurovascular structures, articular cartilage, or even cause iatrogenic fracture.

Stannard et al, *Clin Orthop Relat Res*, 2000

Surgical approach from side of dislocation.

Hip Dislocation: Nonoperative Treatment

- If hip stable after reduction, and reduction congruent.
- Maintain patient comfort.
- ROM precautions (No Adduction, Internal Rotation).
- No flexion $> 60^{\circ}$.
- Early mobilization.
- Touch down weight-bearing for 4-6 weeks.
- Repeat x-rays before allowing weight-bearing.

Hip Dislocation: Indications for Operative Treatment

1. Irreducible hip dislocation
2. Hip dislocation with femoral neck fracture
3. Incarcerated fragment in joint
4. Incongruent reduction
5. Unstable hip after reduction

1. Irreducible Hip Dislocation: Anterior

Smith-Peterson approach

- Watson-Jones is an alternate approach

1. Allows visualization and retraction of interposed tissue.
2. Placement of Schanz pin in intertrochanteric region of femur will assist in manipulation of the proximal femur.
3. Repair capsule, if this can be accomplished without further dissection.

1. Irreducible Hip Dislocation: Posterior

1. Kocher-Langenbeck approach.

1. Remove interposed tissue, or release buttonhole.

1. Repair posterior wall of acetabulum if fractured and amenable to fixation.

Irreducible Posterior Dislocation with Large Femoral Head Fracture

Fortunately, these are rare.

Difficult to fix femoral head fracture from posterior approach without transecting ligamentum teres.

Three Options

1. Detach femoral head from ligamentum teres, repair femoral head fracture with hip dislocated, reduce hip.
2. Reduce hip through posterior incision, close posterior wound, fix femoral head fracture from anterior approach (either now or later).
3. Ganz trochanteric “flip” osteotomy.

Best option not known: Damage to blood supply from anterior capsulotomy vs. damage to blood supply from transecting ligamentum teres.

These will be discussed in detail in femoral head fracture section.

2. Hip Dislocation with Femoral Neck Fracture

Attempts at closed reduction potentiate chance of fracture displacement with consequent increased risk of AVN.

If femoral neck fracture is already displaced, then the ability to reduce the head by closed means is markedly compromised.

Thus, closed reduction should not be attempted.

2. Hip Dislocation with Femoral Neck Fracture

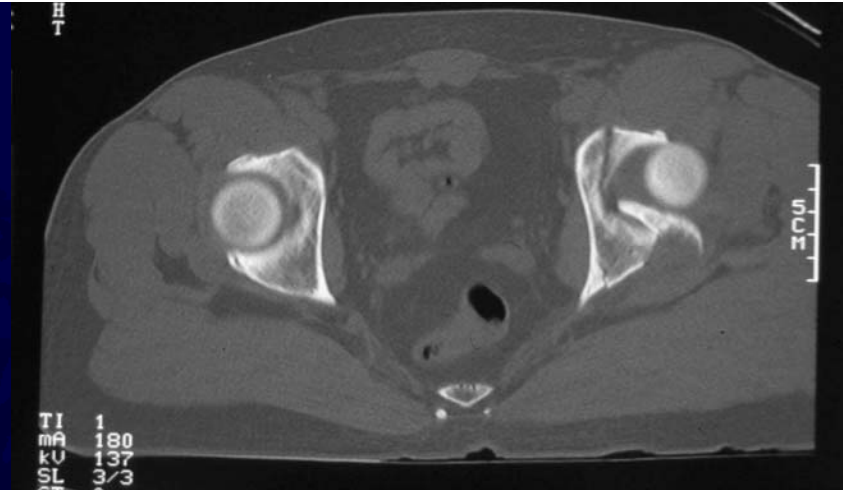
Usually the dislocation is posterior.

Thus, Kocher-Langenbeck approach.

If fracture is non-displaced, stabilize fracture with parallel lag screws first.

If fracture is displaced, open reduction of femoral head into acetabulum, reduction of femoral neck fracture, and stabilization of femoral neck fracture.

3. Incarcerated Fragment



Can be detected on x-ray or CT scan.

Surgical removal necessary to prevent abrasive wear of the articular cartilage.

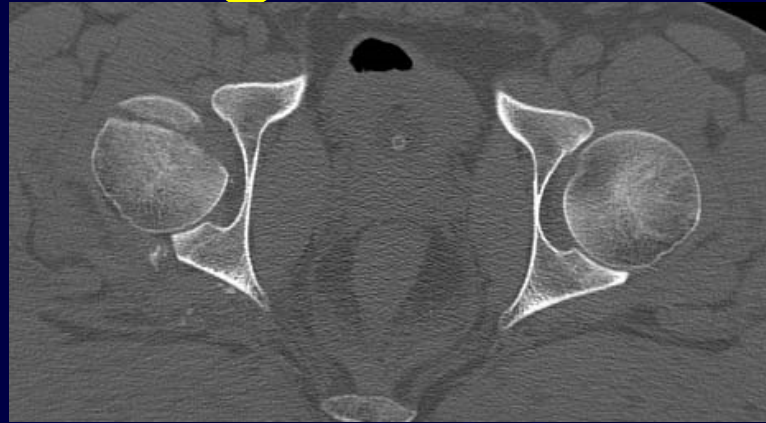Posterior approach allows best visualization of acetabulum (with distraction or intra-op dislocation).

Anterior approach only if:

dislocation was anterior and,

fragment is readily accessible anteriorly.

4. Incongruent Reduction



Caused By:

- Acetabulum Fracture (weight-bearing portion).
- Femoral Head Fracture (any portion).
- Interposed tissue.

Goal: achieve congruence by removing interposed tissue and/or reducing and stabilizing fracture.

Incongruent Reduction: Interposed Tissue

- 25% (9/35) of pediatric patients with traumatic hip dislocation required surgery to remove interposed soft tissue and/or osteochondral fragments to achieve congruent hip reduction.
Vialle et al, *J Pediatric Orthop* 2005
- 92% (33/36) of adults had loose bodies detected arthroscopically.
- 21% (7/33) had normal x-rays and CT.
 - Clinical significance of soft-tissue interposition is not clear if joint congruent.
 - ? Benefit of routine arthroscopy.Mullis and Dahner, *J Orthop Trauma*, 2006

5. Unstable Hip after Reduction

- Due to posterior wall and/or femoral head fracture.
- Requires reduction and stabilization fracture.
- Labral detachment or tear
 - Highly uncommon cause of instability.
 - Its presence in the unstable hip would justify surgical repair.
 - MRI may be helpful in establishing diagnosis.

Results of Treatment

- Large range: from normal to severe pain and degeneration.
- In general, dislocations with associated femoral head or acetabulum fractures fare worse.
- Dislocations with fractures of both the femoral head and the acetabulum have a strong association with poor results.
- Irreducible hip dislocations have a strong association with poor results.
 - 13/23 (61%) poor and 3/23 (13%) fair results.

McKee, Garay, Schemitsch, Kreder, Stephen. Irreducible fracture-dislocation of the hip: a severe injury with a poor prognosis. *J Orthop Trauma*. 1998.

Complications of Hip Dislocation

- Avascular Necrosis (AVN): 1-20%
 - Several authors have shown a positive correlation between duration of dislocation and rate of AVN.
 - Results are best if hip reduced within six hours.
 - Mehlman et al (CORR 2000) demonstrated a 20X greater risk of AVN in pediatric traumatic hip dislocations if reduction delayed > 6 hrs
 - Also demonstrated that bone scan results can be misleading, and thus routine screening is not recommended

Post-traumatic Osteoarthritis

- Can occur with or without AVN
- May be unavoidable in cases with severe cartilaginous injury.
- Incidence increases with associated femoral head or acetabulum fractures.
 - 16% osteoarthritis in uncomplicated hip dislocations and up to 88% in dislocations associated with severe acetabular fractures
 - Upudhyay et al, *J Bone Joint Surg. (Br.)*, 1983.
- Efforts to minimize osteoarthritis are best directed at achieving anatomic reduction of injury and preventing abrasive wear between articular cartilage and sharp bone edges.

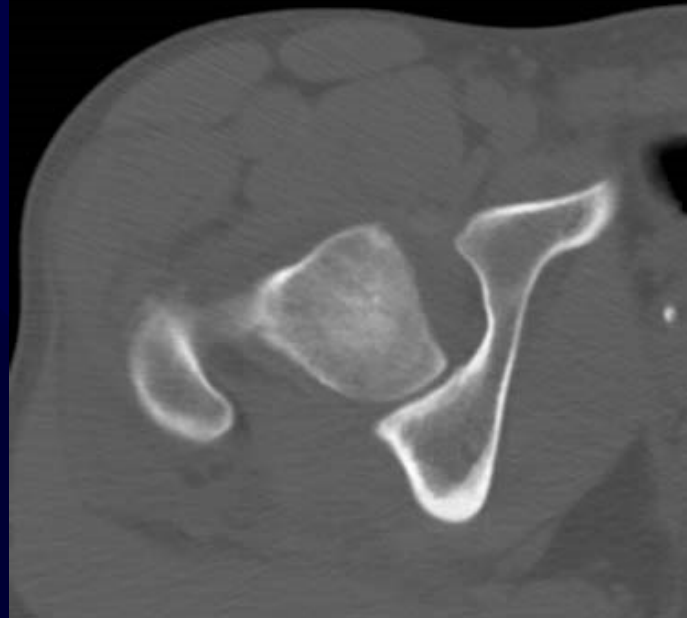
Recurrent Dislocation

Rare, unless an underlying bony instability has not been surgically corrected (e.g. excision of large posterior wall fragment instead of ORIF).

Some cases involve pure dislocation with inadequate soft-tissue healing – may benefit from surgical imbrication (rare).

Can occur from detached labrum, which would benefit from repair (rare).

Recurrent Dislocation Caused by Defect in Posterior Wall and/or Femoral Head



Can occur after excision of fractured fragment.

Pelvic and/or intertrochanteric osteotomy could
alter the alignment of the hip to improve stability.

Bony block could also provide stability.

Delayed Diagnosis of Hip Dislocation

Increased incidence in multiple trauma patients.

More common if patient has altered sensorium.

Results in: more difficult closed reduction.
 higher incidence of AVN.

In NO Case should a hip dislocation be treated
without reduction.

Sciatic Nerve Injury

Occurs in up to 20% of adult and 5% of pediatric patients with hip dislocation.

Peroneal nerve affected more commonly than tibial

Nerve stretched, compressed or transected.

With reduction:	40% complete resolution
	25-35% partial resolution

Sciatic Nerve Palsy: If No Improvement after 3–4 Weeks

EMG and Nerve Conduction Studies for
baseline information and for prognosis.

Allows localization of injury in the event that
surgery is required.

Foot Drop

Splinting (i.e. ankle-foot-orthosis):

- Improves gait
- Prevents contracture

Infection

Incidence 1-5%

Lowest with prophylactic antibiotics and limited surgical approaches

Infection: Treatment Principles

Maintenance of joint stability.

Debridement of devitalized tissue.

Intravenous antibiotics.

Hardware removed only when fracture healed.

Iatrogenic Sciatic Nerve Injury

Most common with posterior approach to hip.

Results from prolonged retraction on nerve.

Iatrogenic Sciatic Nerve Injury

Prevention:

Maintain hip in full extension

Maintain knee in flexion

Avoid retractors in lesser sciatic notch

? Intra-operative nerve monitoring (SSEP, motor monitoring)

Thromboembolism

Hip dislocation = high risk patient.

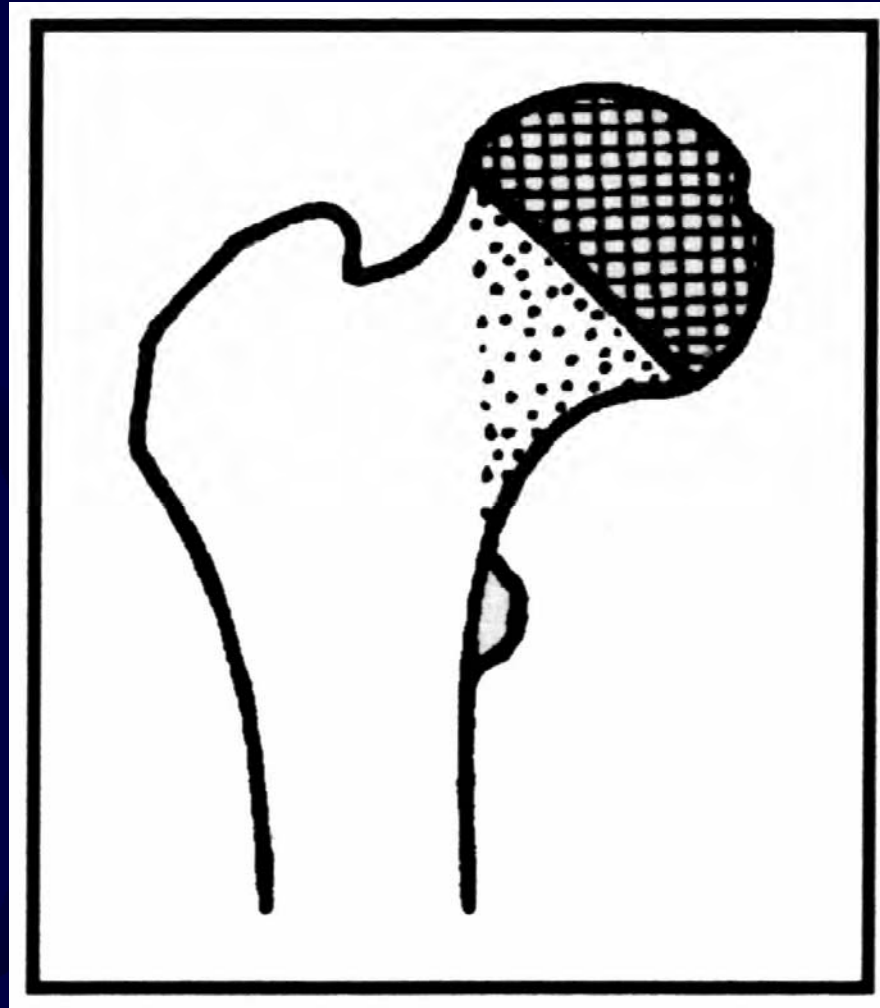
Prophylactic treatment with:

- low molecular weight heparin, or
- coumadin

Early postoperative mobilization.

Discontinue prophylaxis after 2-6 weeks (if patient mobile).

Femoral Head Fractures



Treatment principles similar to those listed for hip dislocations.

Femoral Head Fractures – Mechanism

- Fracture occurs by shear as femoral head dislocates.
- With less hip flexion, femoral head fracture tends to be larger.

History and Physical Examination

Similar to patient with hip dislocation.

Patient posture may be less extreme due to femoral head fracture.

Classification of Femoral Head Fractures

Thompson and Epstein Type V

- Posterior hip dislocation with femoral head fracture

Epstein Type IB

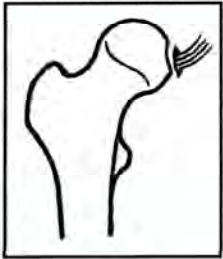- Anterosuperior dislocation with femoral head and/or neck fracture

Epstein Type IIB

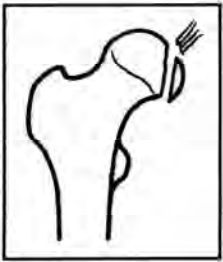- Anteroinferior dislocation with femoral head and/or neck fracture

Femur, proximal, head fracture,
split (31-C1).

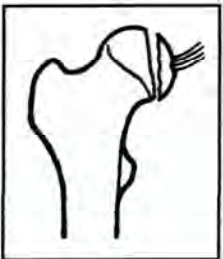1. Avulsion of ligamentum teres
(31-C1.1)



2. With rupture of ligamentum teres
(31-C1.2)



3. Large fragment (31-C1.3)

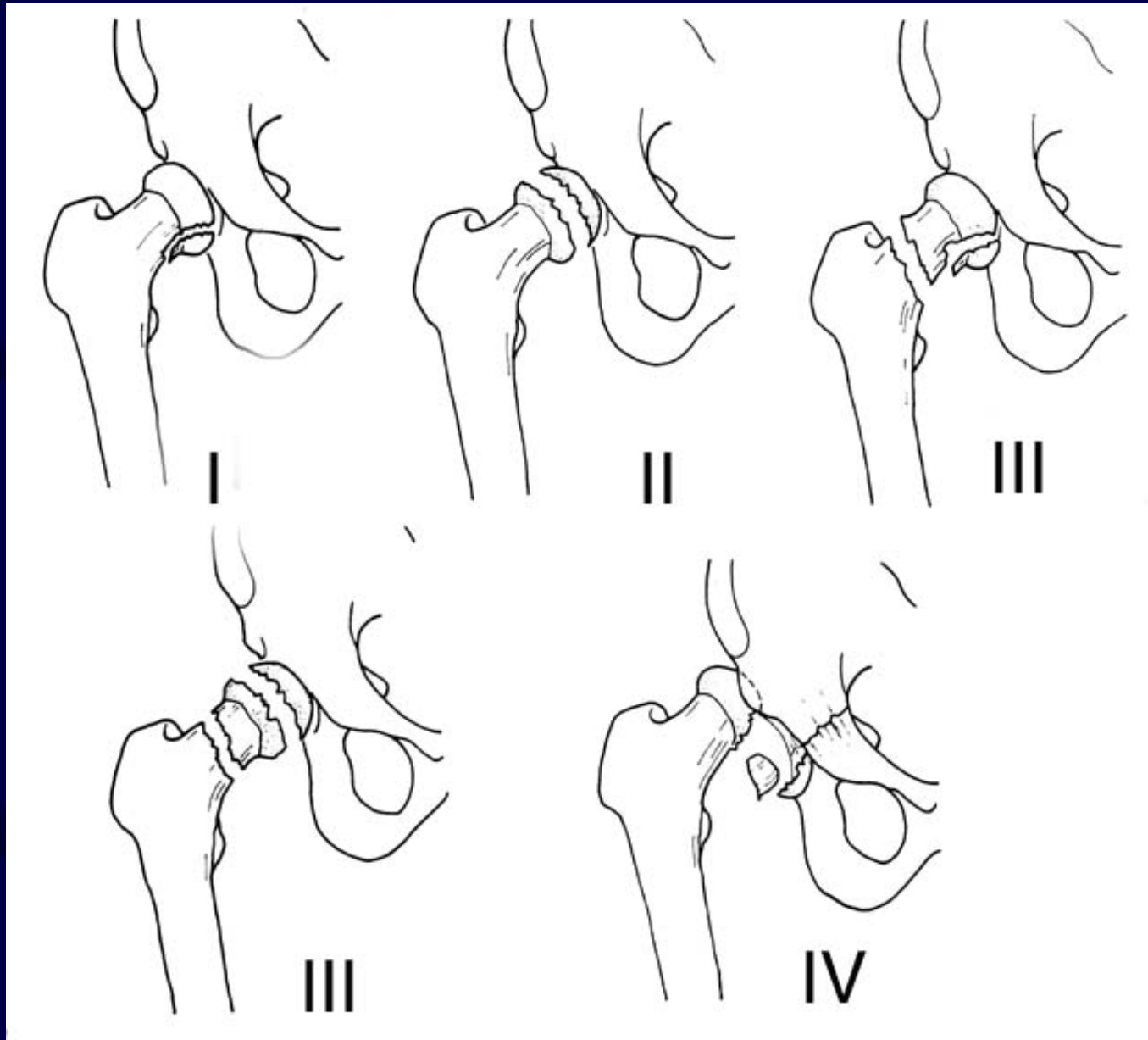


AO/OTA Classification

Pipkin Classification

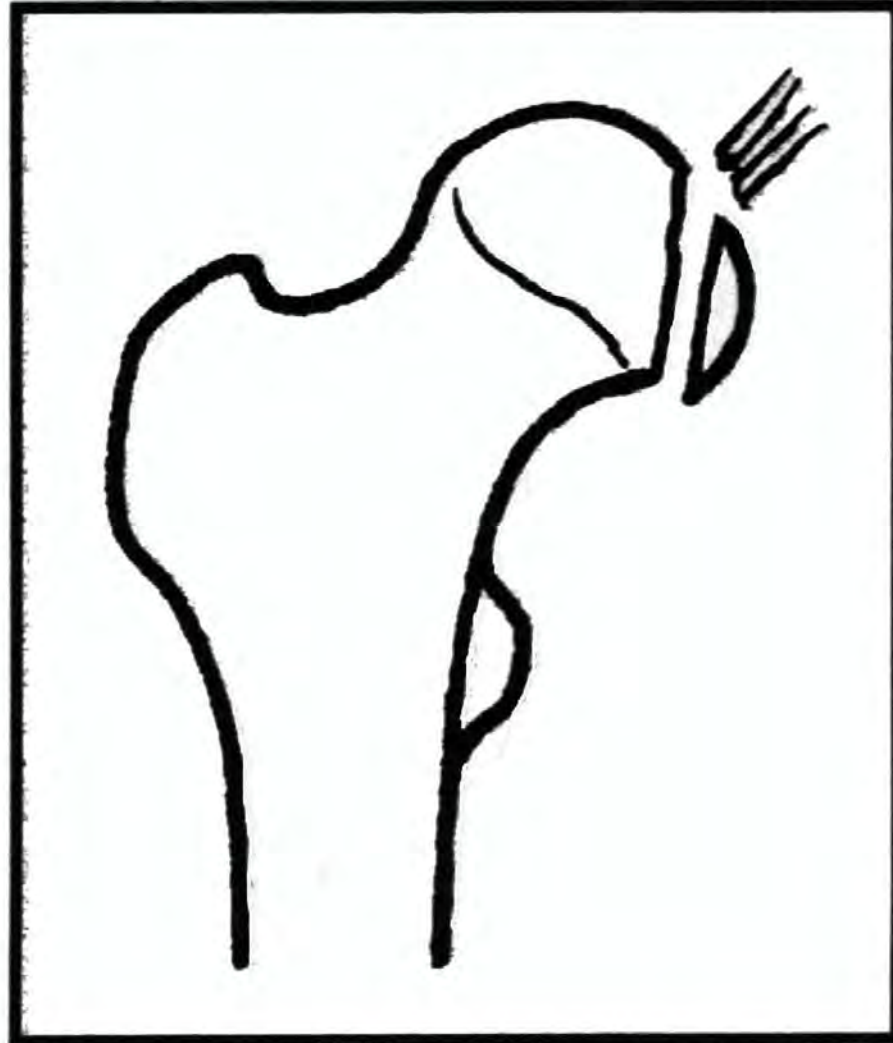
- I Fracture inferior to fovea
- II Fracture superior to fovea
- III Fracture of femoral head with fracture of femoral neck
- IV Fracture of femoral head with acetabulum fracture

Pipkin, *JBJS*, 1957



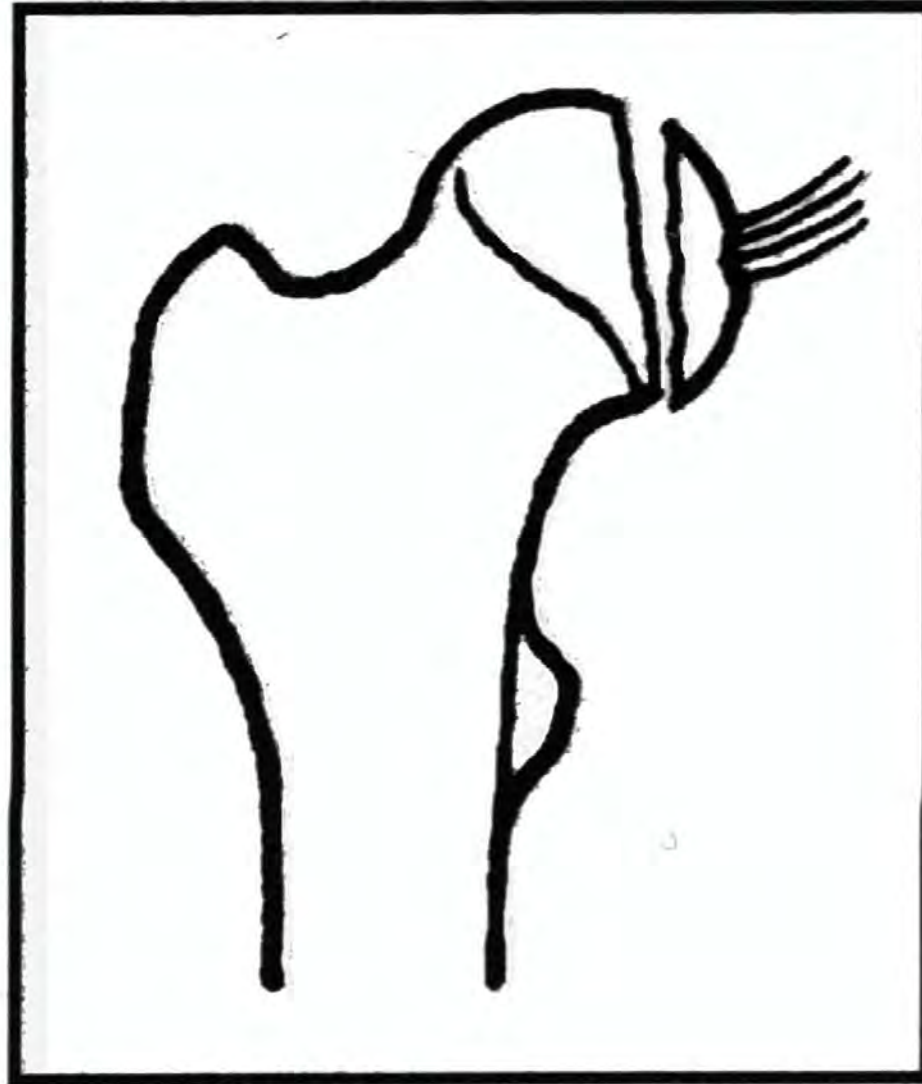
Pipkin I

AO/OTA 31-C1.2

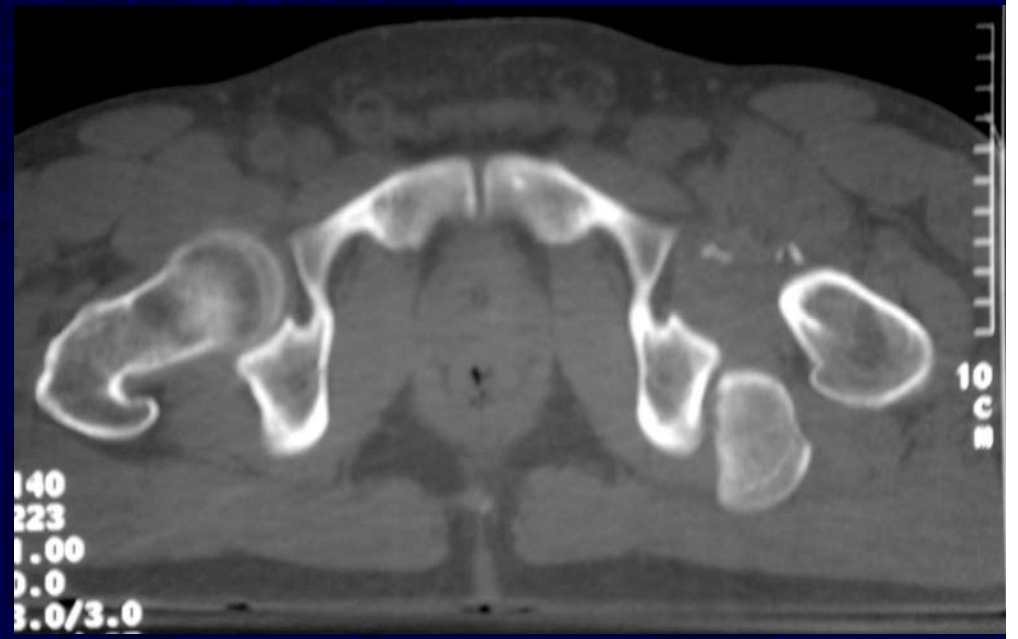
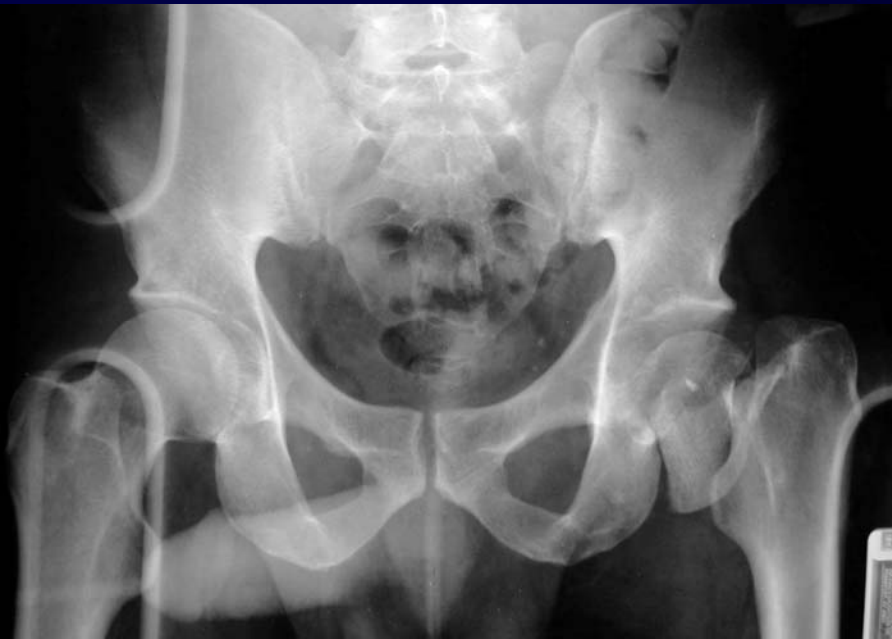

Pipkin II

AO/OTA 31-C1.3

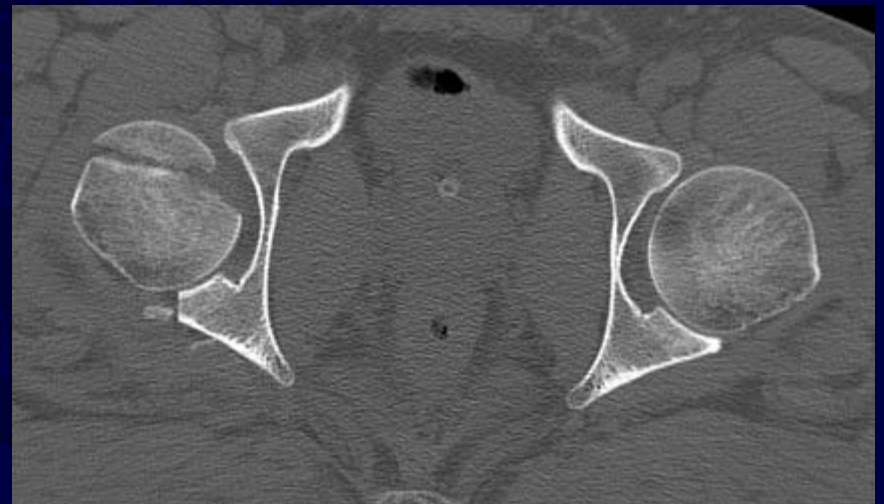
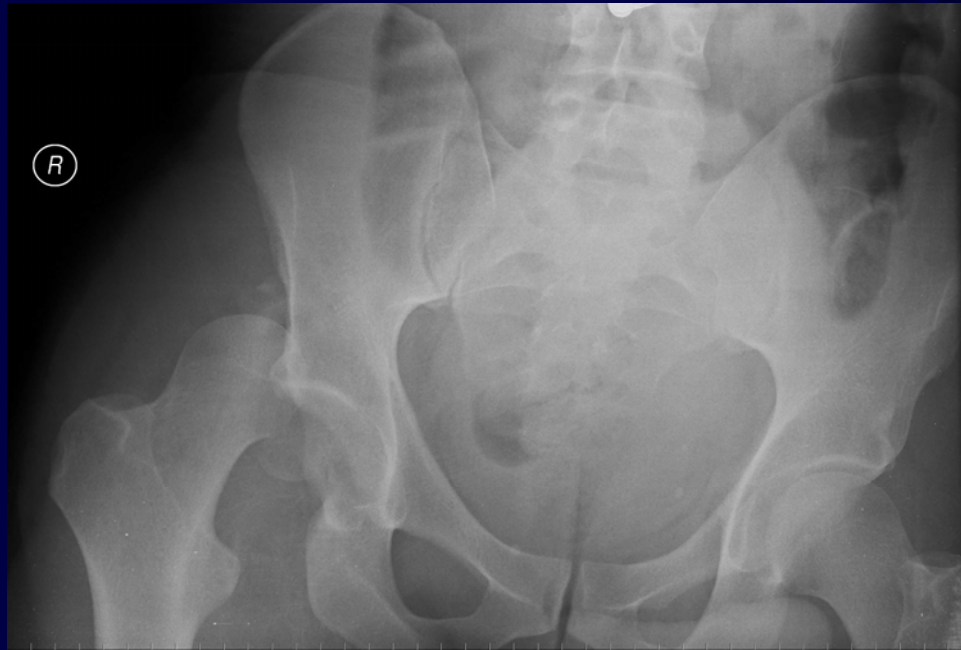


Pipkin III



- Femoral head fracture with femoral neck fracture.

Pipkin IV



- Femoral head fracture with acetabulum fracture.
- High incidence of post-traumatic AVN.

Pipkin Prognostic Value

- 33 patients with posterior fracture-dislocations of the hip.
- Pipkin Types I/II had statistically significant better outcomes than Types III/IV.

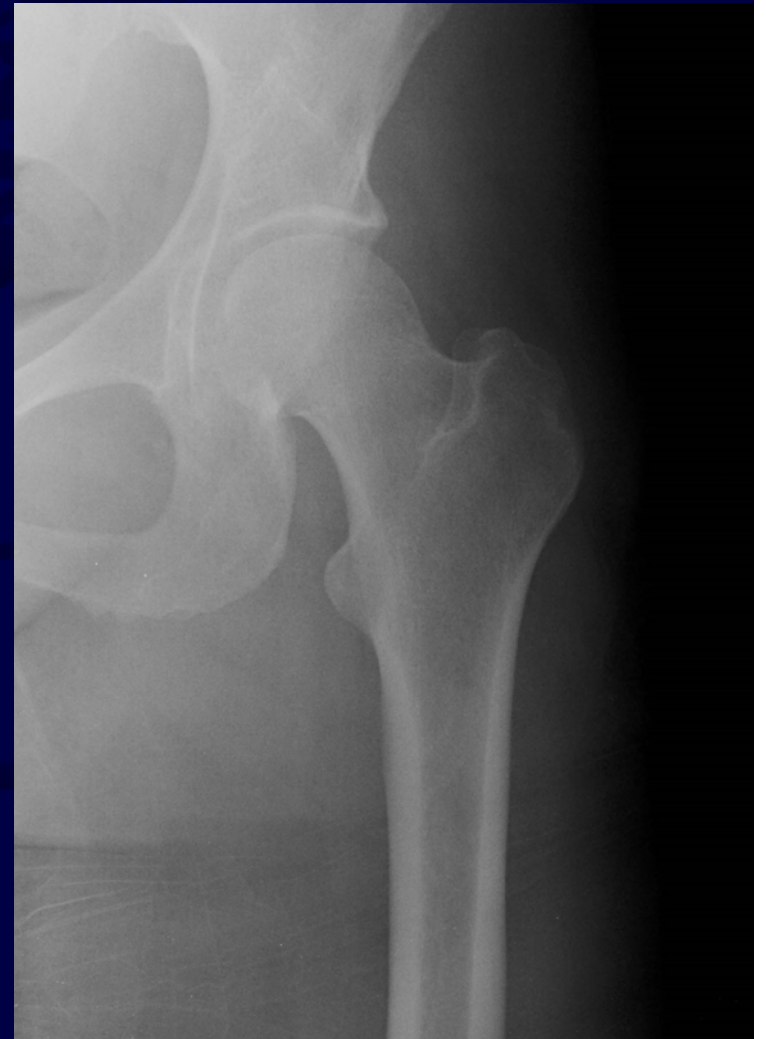Marchetti, Steinberg, and Coumas, *J Orthop Trauma*, 1996

- 46 patients
- Better outcomes in Pipkin Types I > II > **IV** > **III**

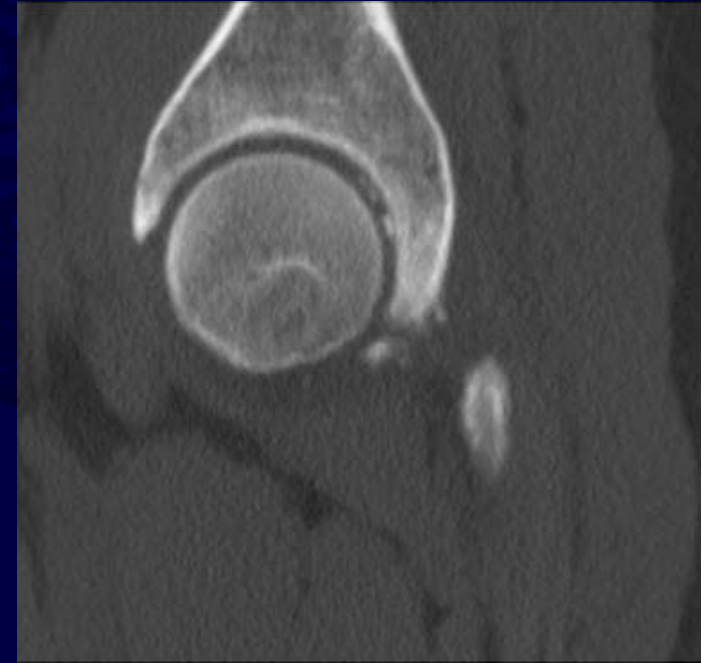
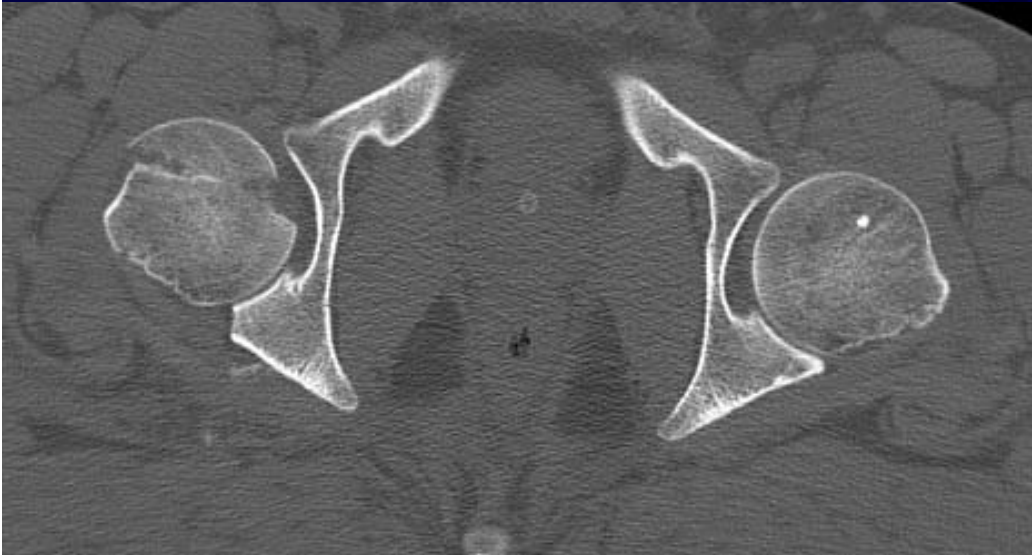
Lederer et al, *Unfallchirurg*, 2007

Femoral Head Fracture: Radiographic Evaluation

- AP Pelvis X-Ray
- Lateral Hip X-Ray
- Judet views
- Post-reduction CT Scan

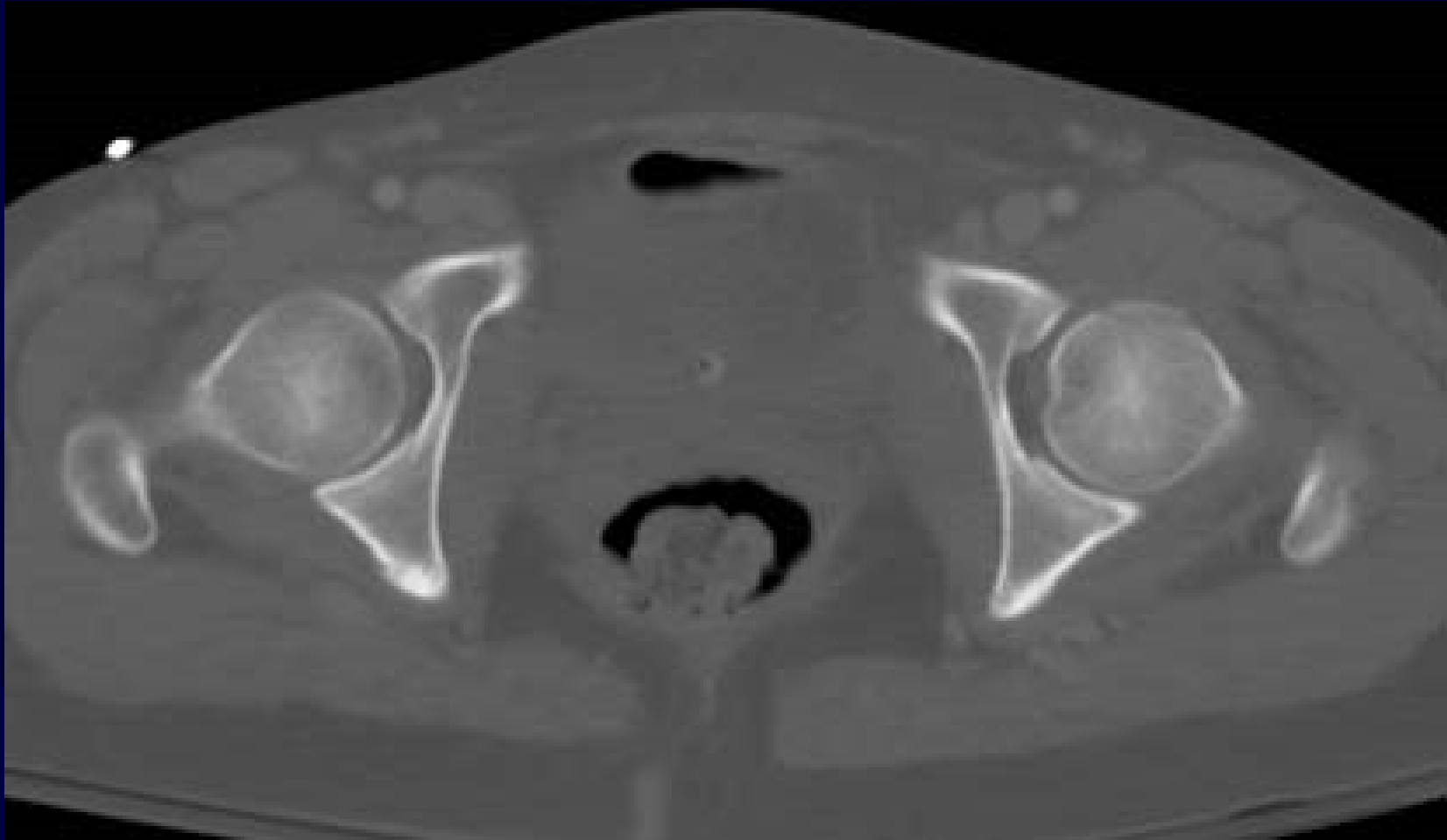


CT Scan



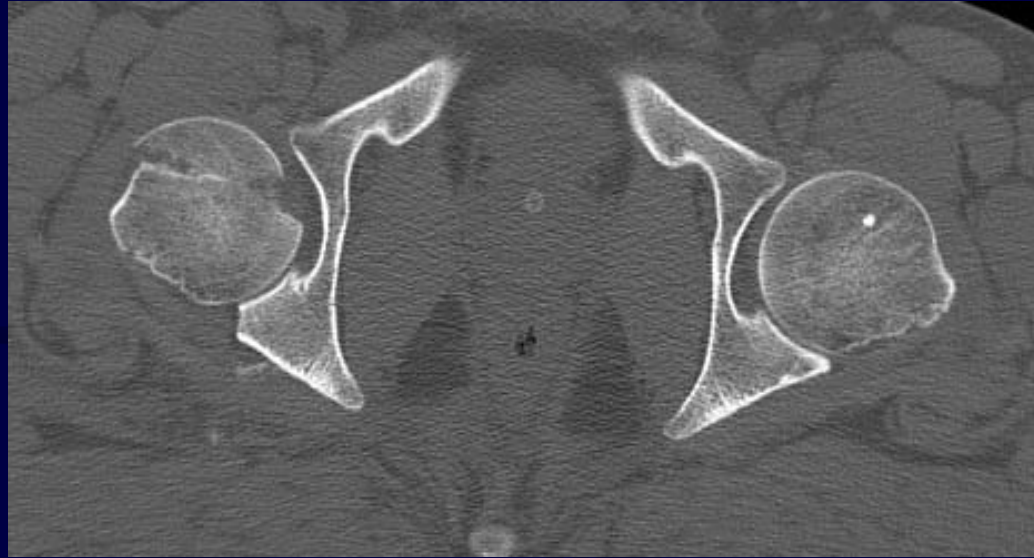
Essential to evaluate quality of reduction of femoral head fracture (congruence), as well as intra-articular fragments.

Nonoperative Treatment If:



Infra-foveal Fracture and Anatomically Reduced

Displaced Infra-foveal Fractures



Can be reduced and stabilized, or excised.

ORIF preferred if possible.

Anterior approach allows best visualization.

Posterior vs Anterior Approach

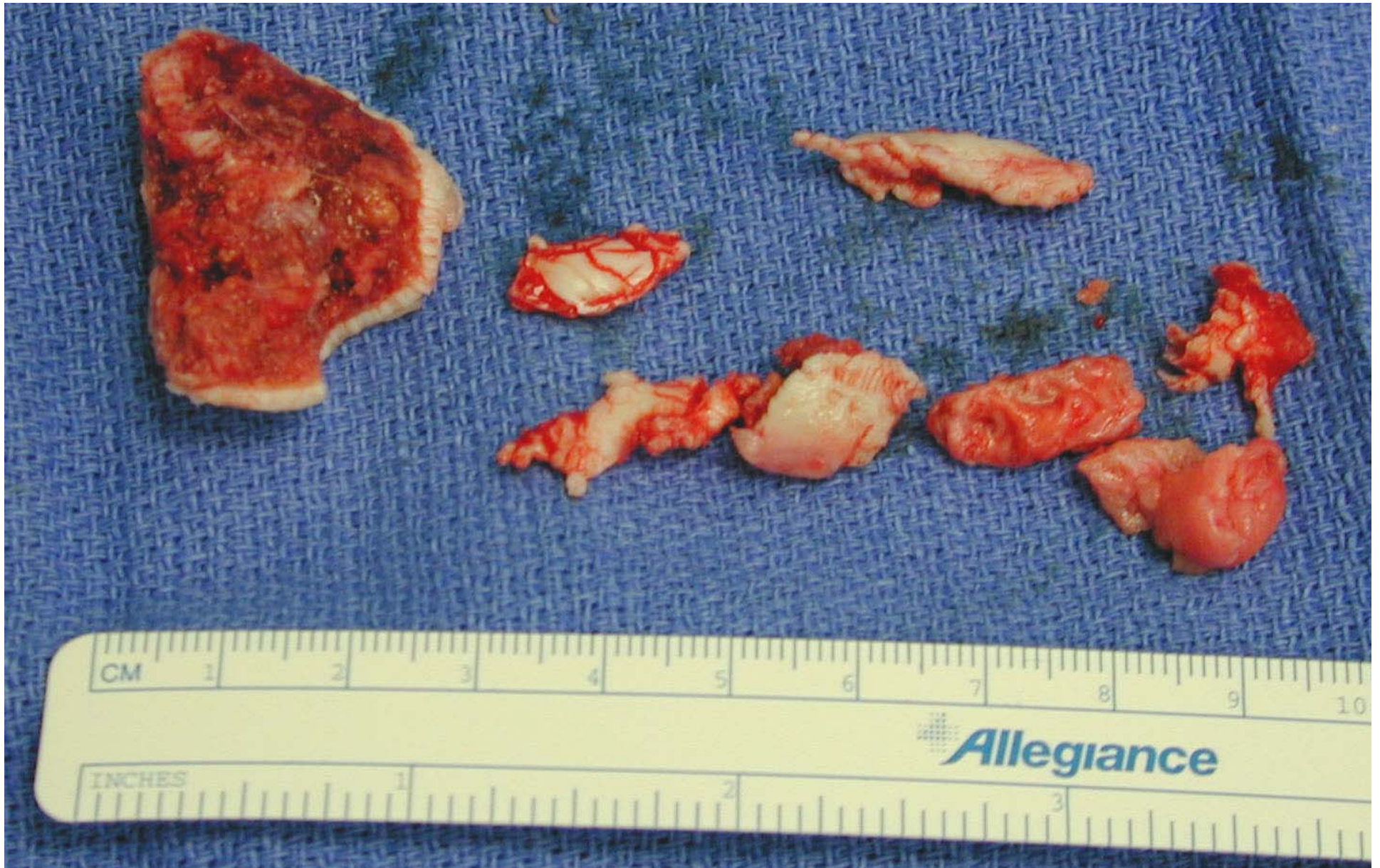
- Support for Posterior Approach
 - Sarmiento, CORR 1973
 - Epstein, JBJS 1974 (0 good results with ant. approach)
- Support for Anterior Approach
 - Swiontkowski, Thorpe, Seiler, Hansen, *J Orthop Trauma* 1992:
 - 12 anterior, 12 posterior.
 - Less blood loss and operative time with anterior approach.
 - Improved visualization anteriorly.
 - Increased H.O. anteriorly.
 - 67% good and excellent in each group.
 - Nork, Routt et al, OTA 2001: 21 cases, ? one AVN

Supra-foveal Fractures

ORIF through:

1. anterior approach.
2. posterior approach.
3. posterior approach with Ganz trochanteric “flip” osteotomy.

Excision of large fragment(s) will create instability, and thus is contraindicated.



Reconstruct Head Whenever Possible

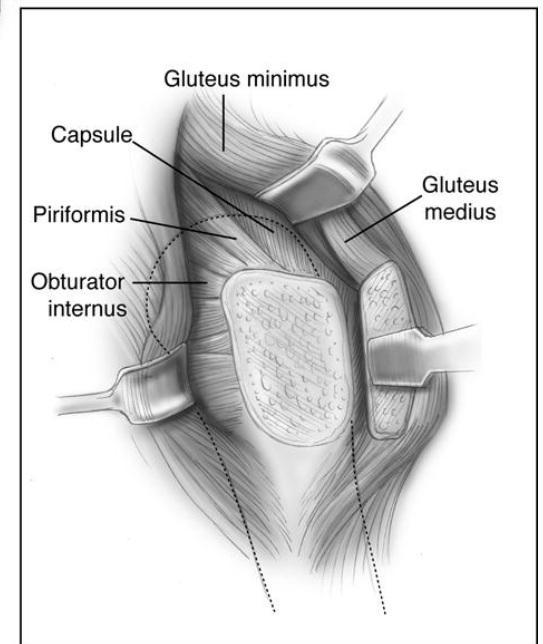
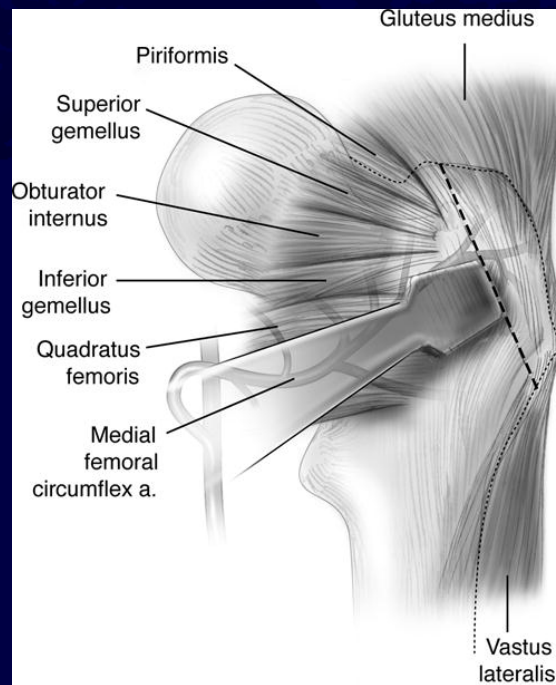
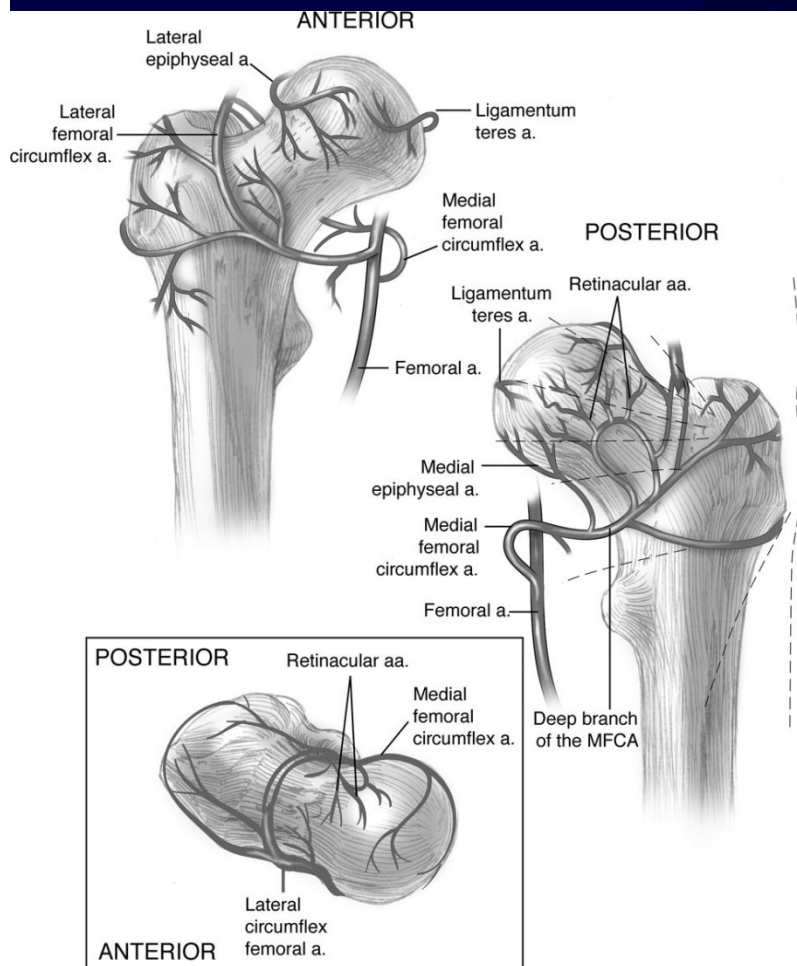
Biomechanical Consequences of Femoral Head Fragment Excision

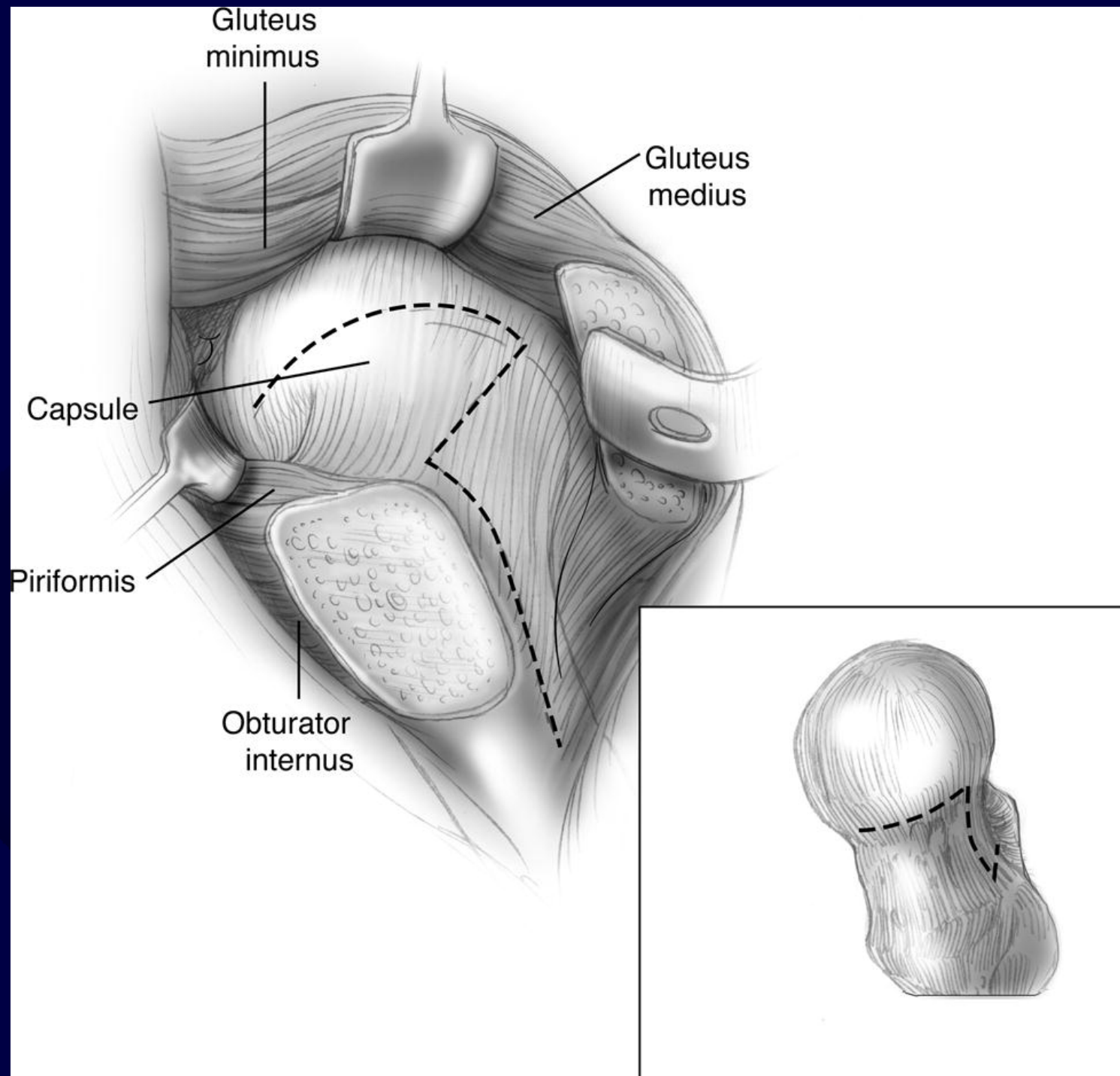
- Excision of Pipkin I fragments caused no significant change in joint contact area and pressures.
- Excision of Pipkin II fragment shifted loading patterns from periphery toward center of acetabulum, reduced joint contact area, and increased mean pressure on cartilage.
- Posited that this may contribute the poorer outcomes seen with excision of larger fragments.

Holmes et al, *presented at OTA*, 1999

Surgical Dislocation of the Hip for Fractures of the Femoral Head

Helfet, Lorich et al, *J Orthop Trauma*, 2005





Head

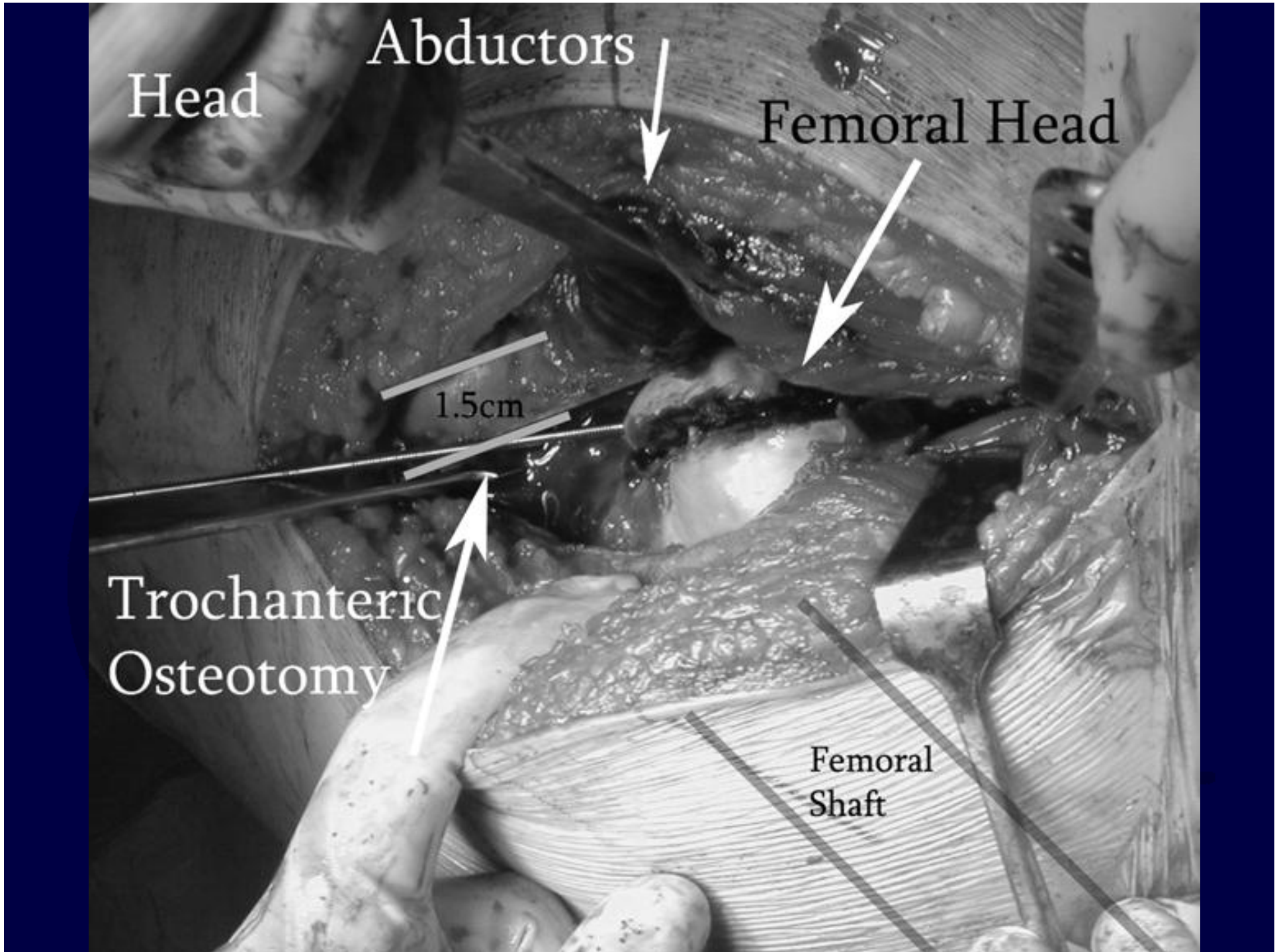
Abductors

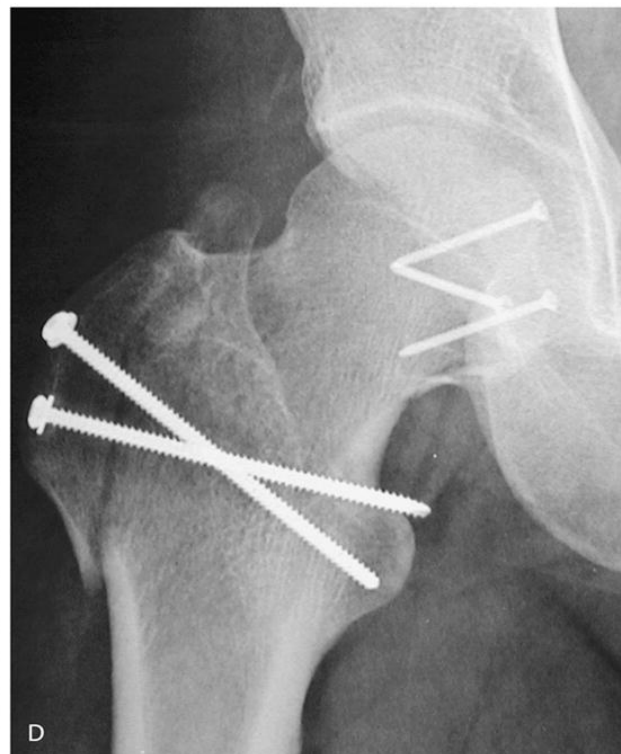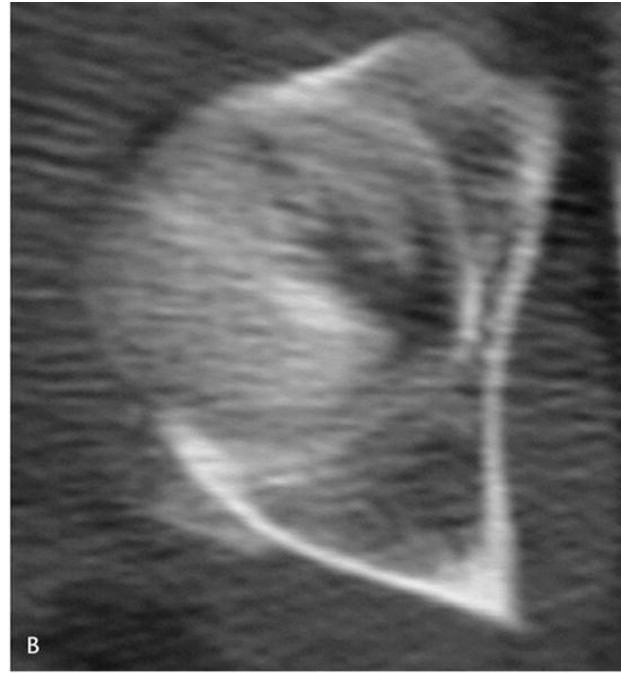
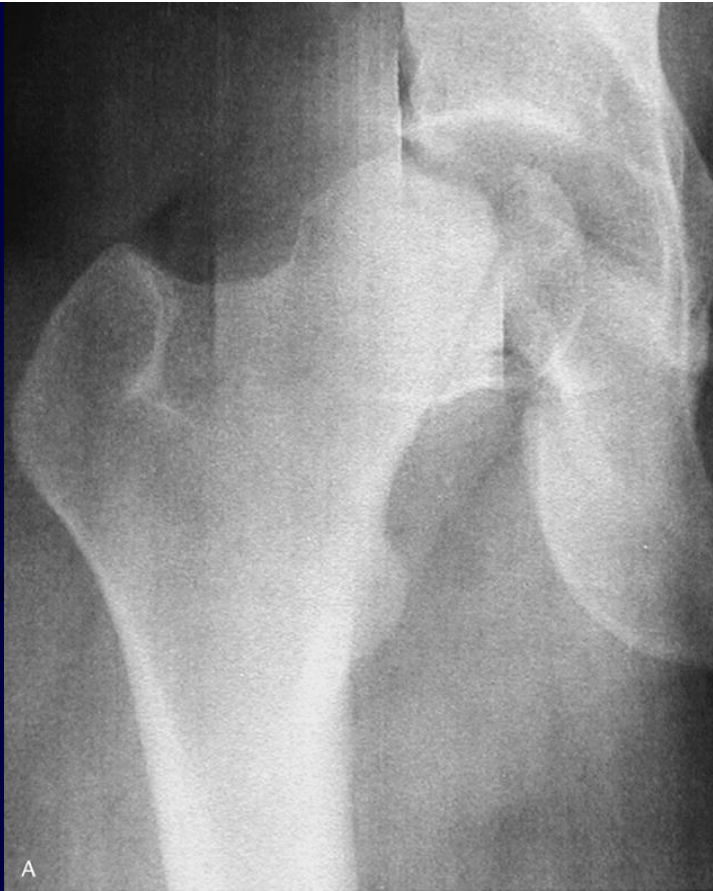Femoral Head

1.5cm

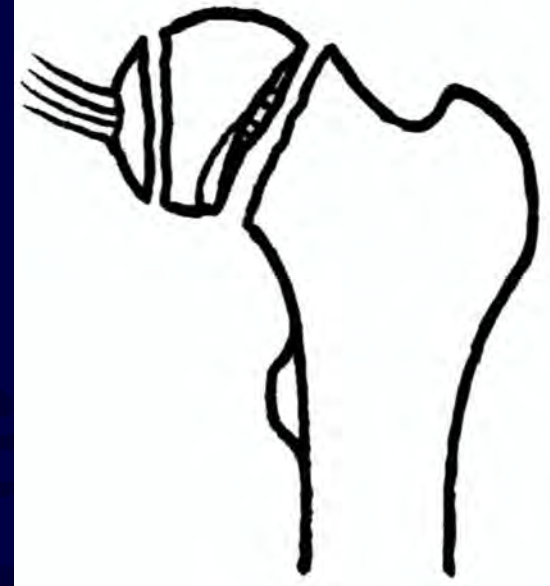
Trochanteric
Osteotomy

Femoral
Shaft





Pipkin III Fractures

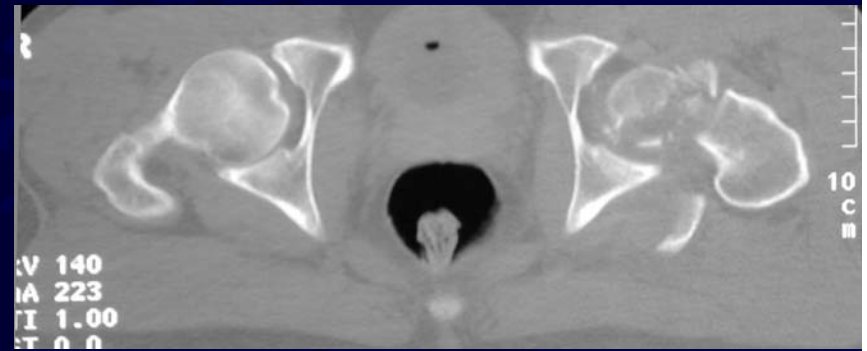
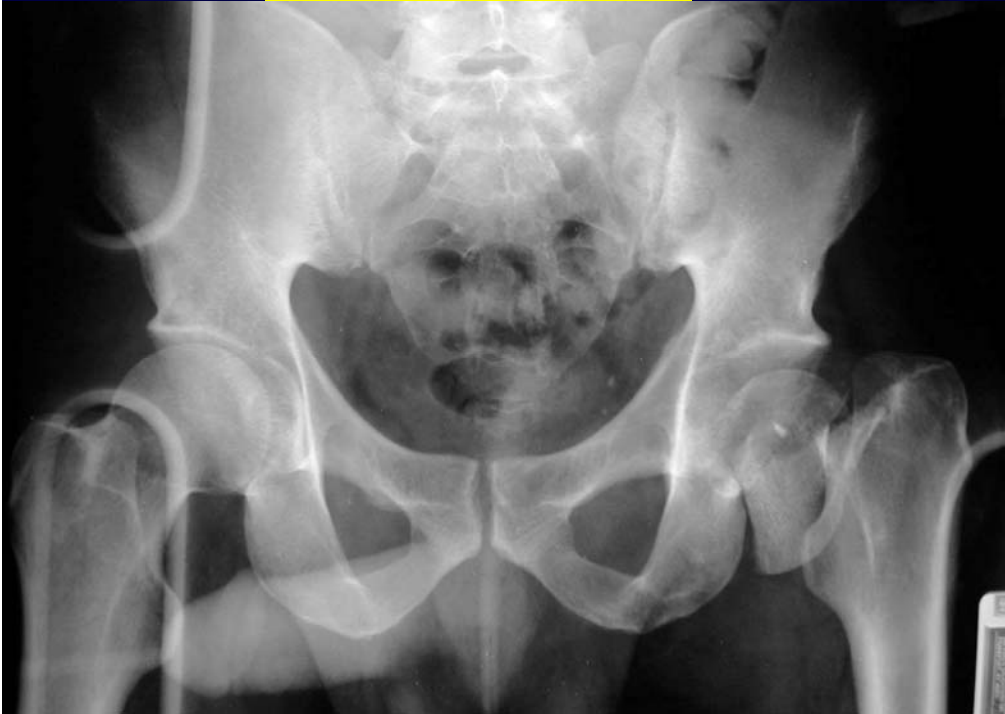

High incidence of AVN and degeneration with displaced fractures.

- Relative indication for hemiarthroplasty in older patient due to this risk
- Attempt at ORIF warranted in active, younger patients

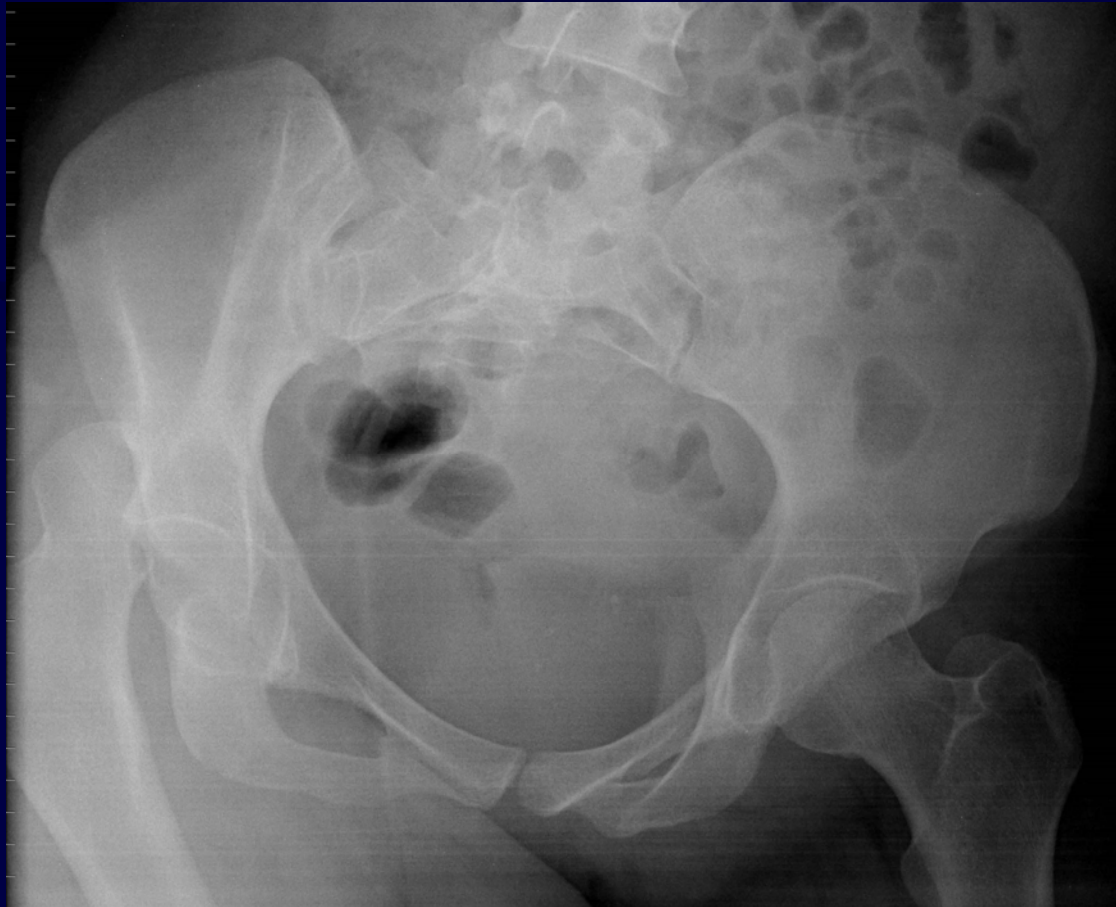If femoral neck fracture is non-displaced, do not attempt manipulative reduction of hip until femoral neck is stabilized.

Femoral Head Fracture-Dislocation with Displaced Femoral Neck Fracture



- Closed reduction attempts are futile.
- ORIF in young: open reduction of hip, then reduction and stabilization of femoral neck and head.
- Arthroplasty in middle-aged and elderly (No good results with ORIF reported in literature).

Femoral Head Fracture-Dislocation with Non-Displaced Femoral Neck Fracture

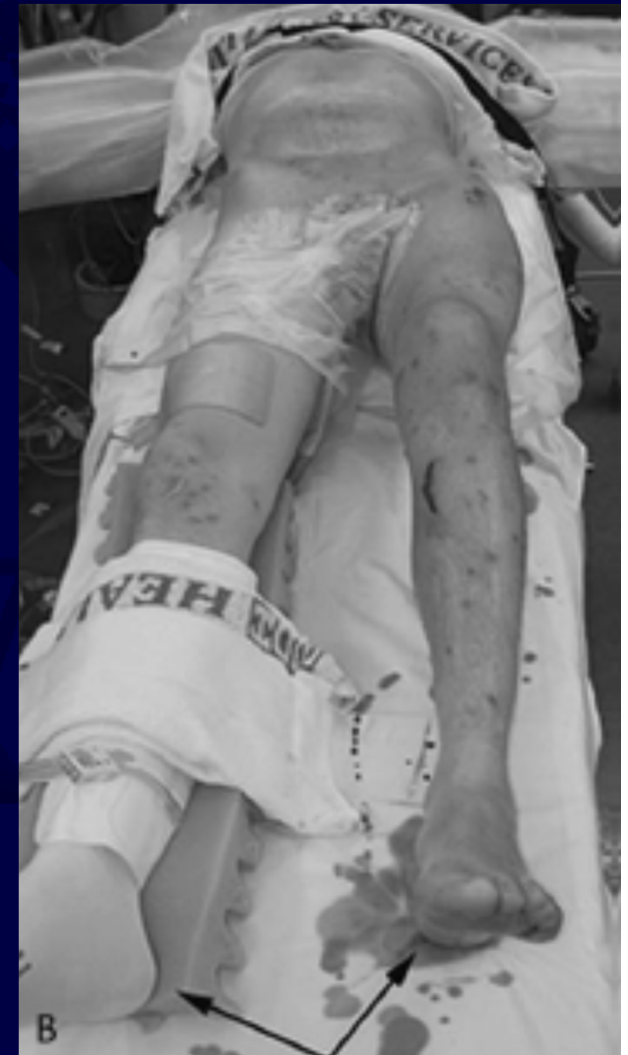

Must consider stabilizing femoral neck fracture before performing reduction of hip.

Irreducible Femoral Head Fracture- Dislocation without Posterior Wall Fracture

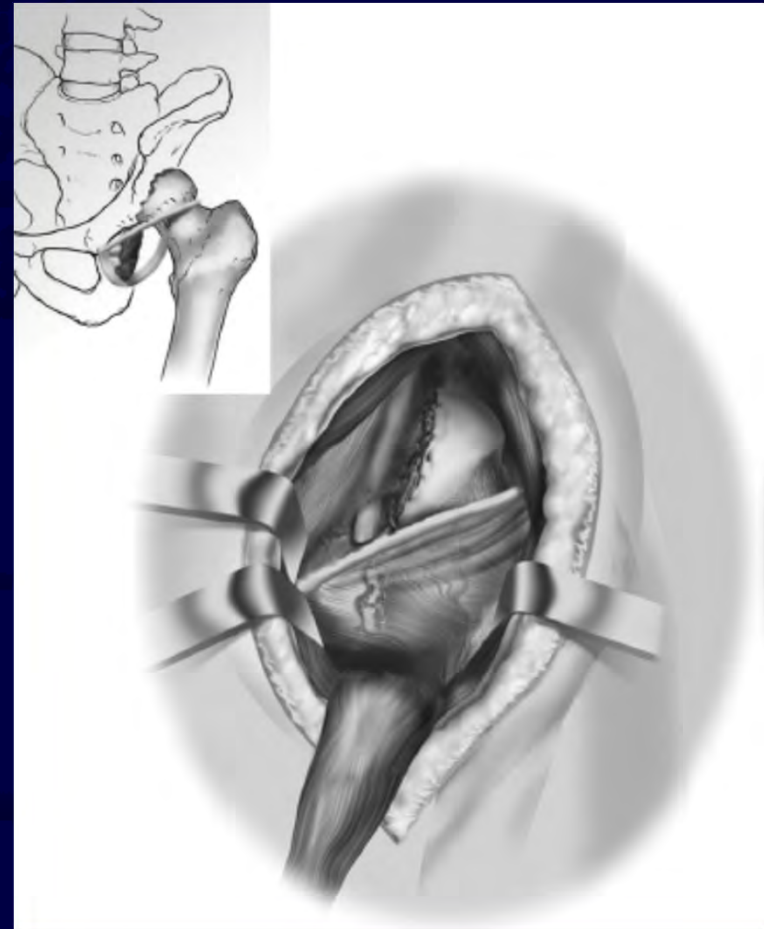
- 72 femoral head fractures treated in 6 years
- 7 (10%) failed routine closed reduction.
- Radiographic findings in these 7:
 - posterosuperior dislocations
 - sagittal plane femoral head fractures
 - intact posterior wall of acetabulum
 - close apposition of proximal femur to the supra-acetabular ilium.
- All had slight, but fixed hip flexion with knee flexion and leg length discrepancy.

Mehta and Routt, *J Orthop Trauma*, 2008

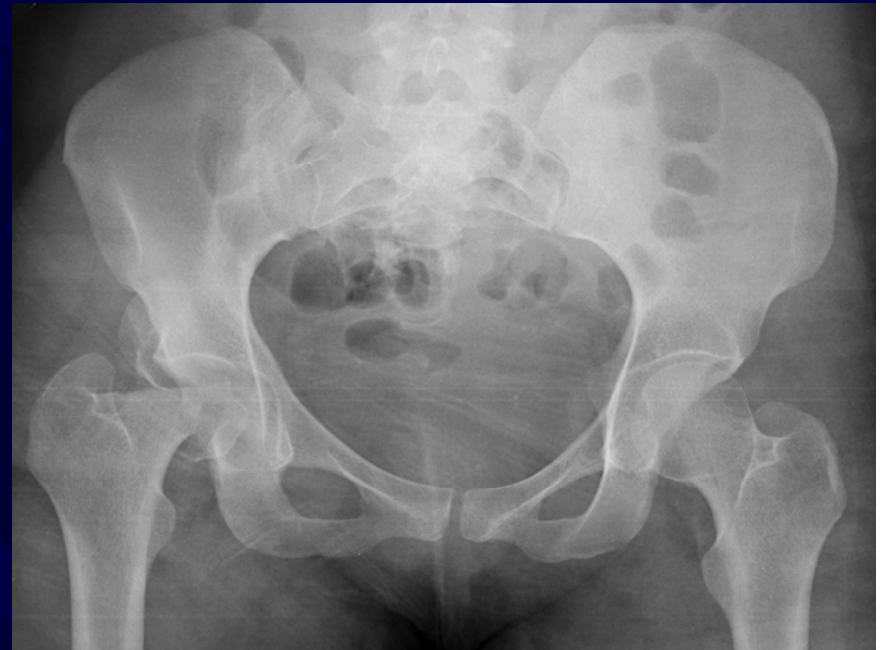
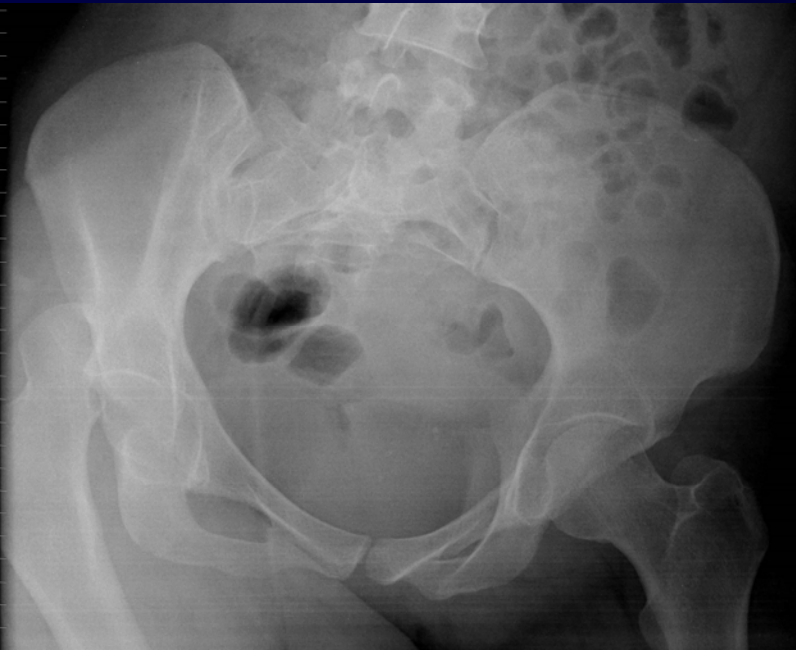
Irreducible Femoral Head Fracture- Dislocation without Posterior Wall Fracture

- One patient sustained iatrogenic femoral neck fracture.
- Two patients had AVN after delayed open reduction (14-32hrs).
- The authors recommend early identification based on clinical and radiographic findings, and emergent open reduction through anterior approach (i.e. DO NOT attempt at closed reduction)

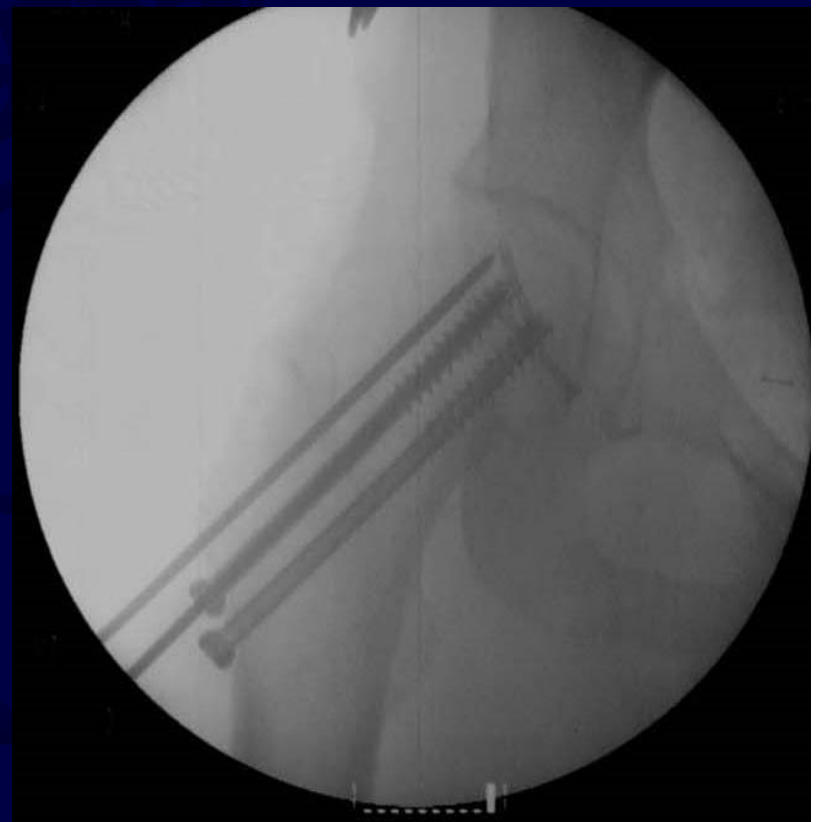


What if Reduction Maneuver Results in Displaced Femoral Neck Fracture?

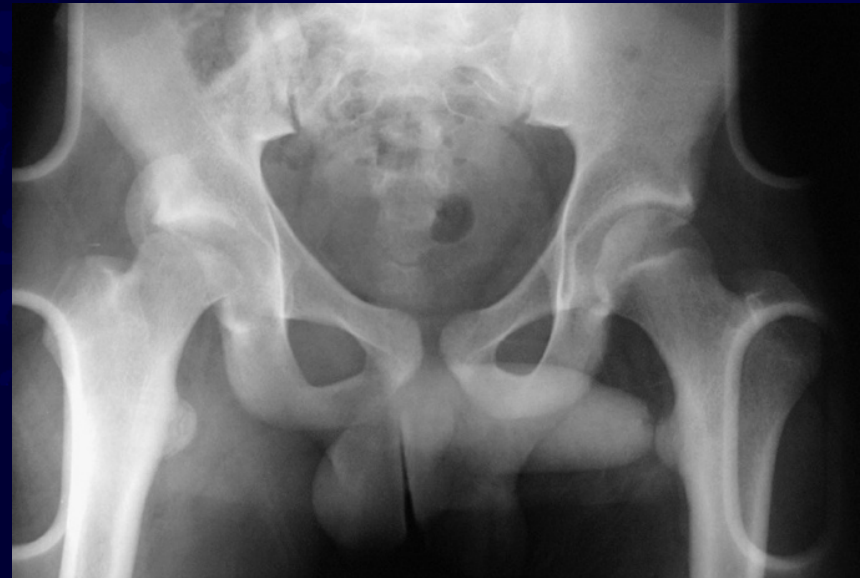
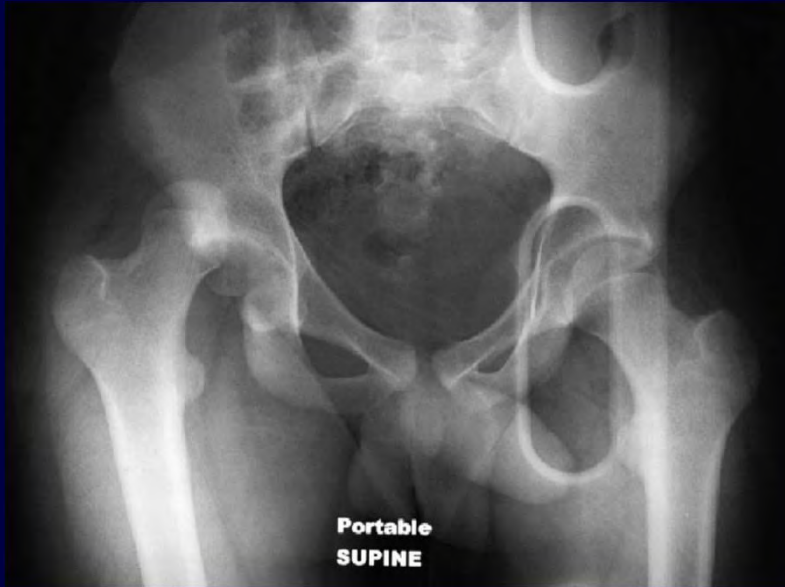
Reduction Maneuver Results in Displaced Femoral Neck Fracture

- Emergent open reduction of hip from side of dislocation.
- Reduction and stabilization of femoral neck fracture.
- Assessment of femoral head fracture for surgical indications.
- In elderly, perform arthroplasty.



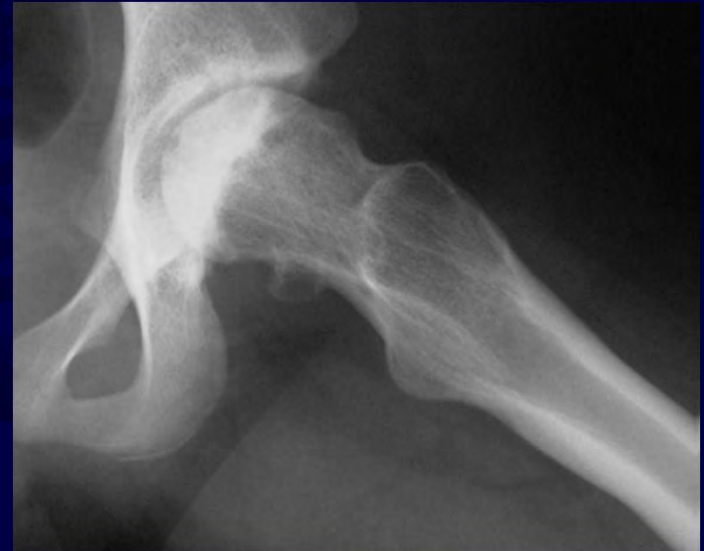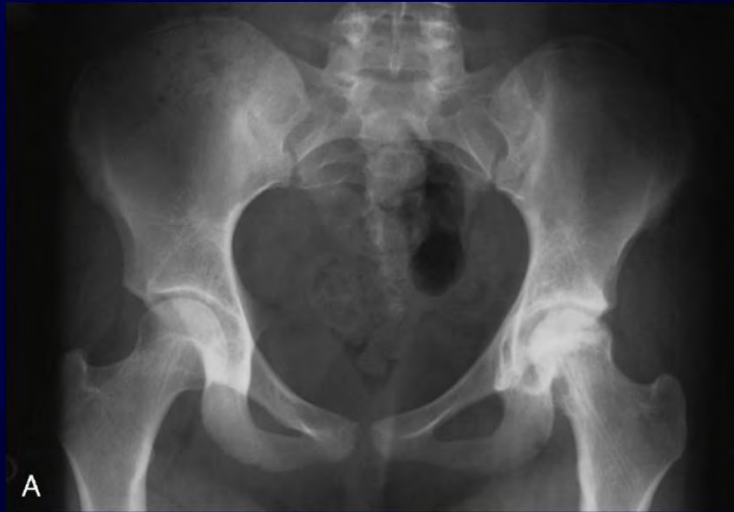Proximal Femoral Epiphysiolysis During Reduction of Adolescent Hip Dislocation



- 5 patients sustained proximal femoral epiphysiolysis during closed reduction of hip dislocation under conscious sedation
- Age 12-16 years

Herrera-Soto et al, *J Pediatr Orthop* 2006

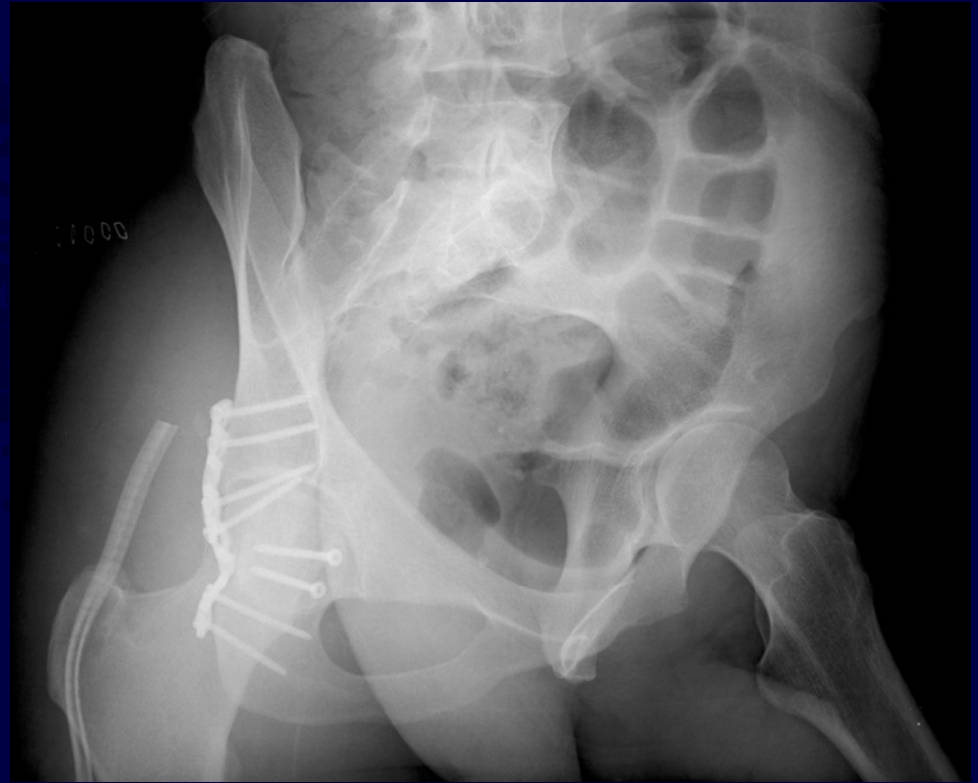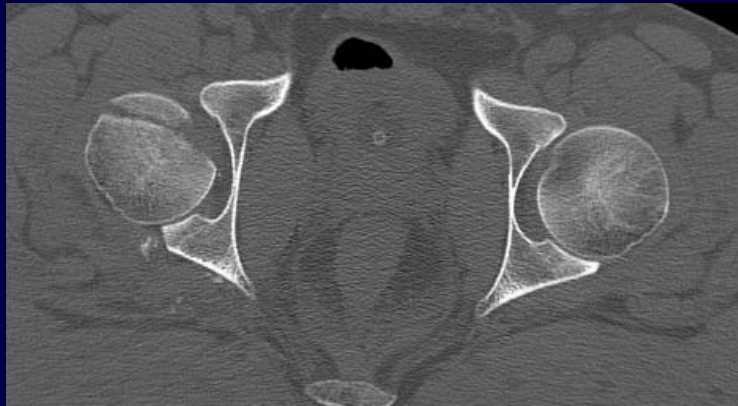
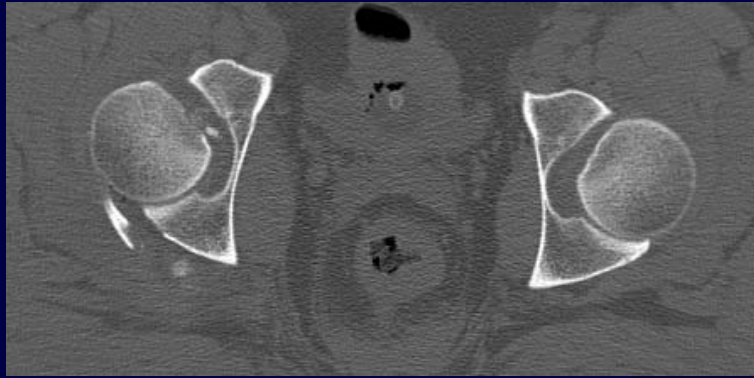
Proximal Femoral Epiphysiolysis During Reduction of Adolescent Hip Dislocation



- 100% developed AVN
- Recommend **gentle reduction**, with **general anesthesia** and manipulation under fluoroscopy, if available
- Any indication of physeal injury should prompt reduction and pinning of the physeal injury prior to hip reduction

Herrera-Soto et al, *J Pediatr Orthop* 2006

Pipkin IV Fractures

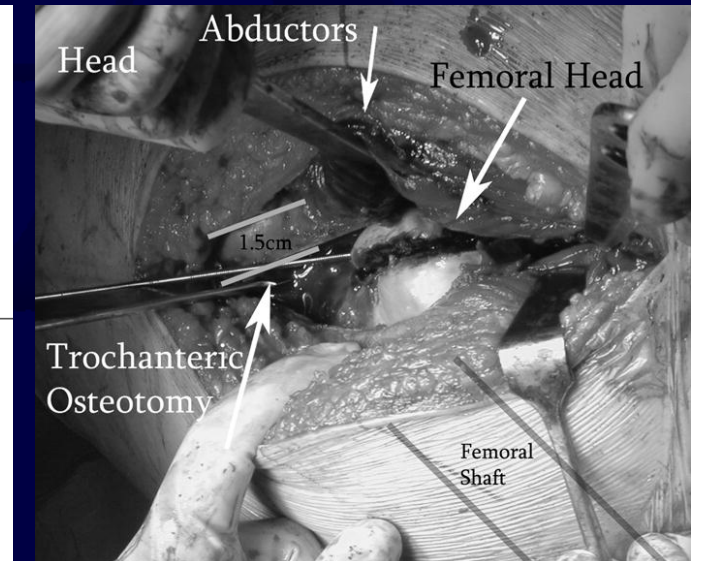
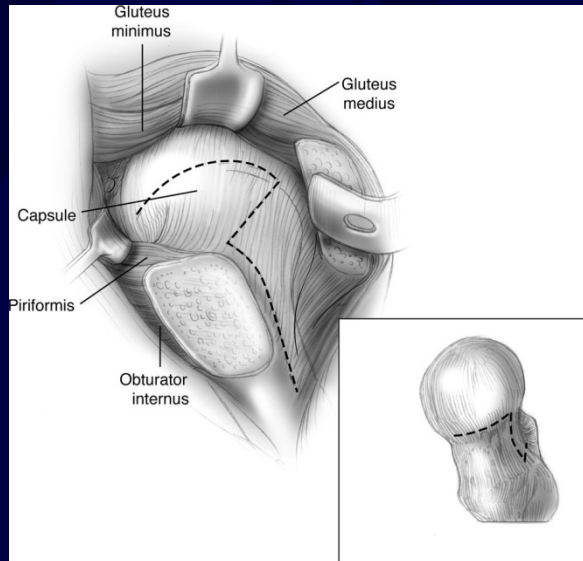
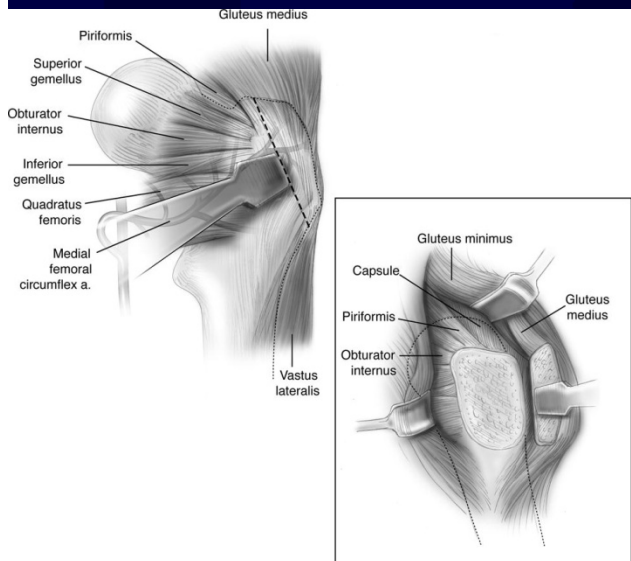
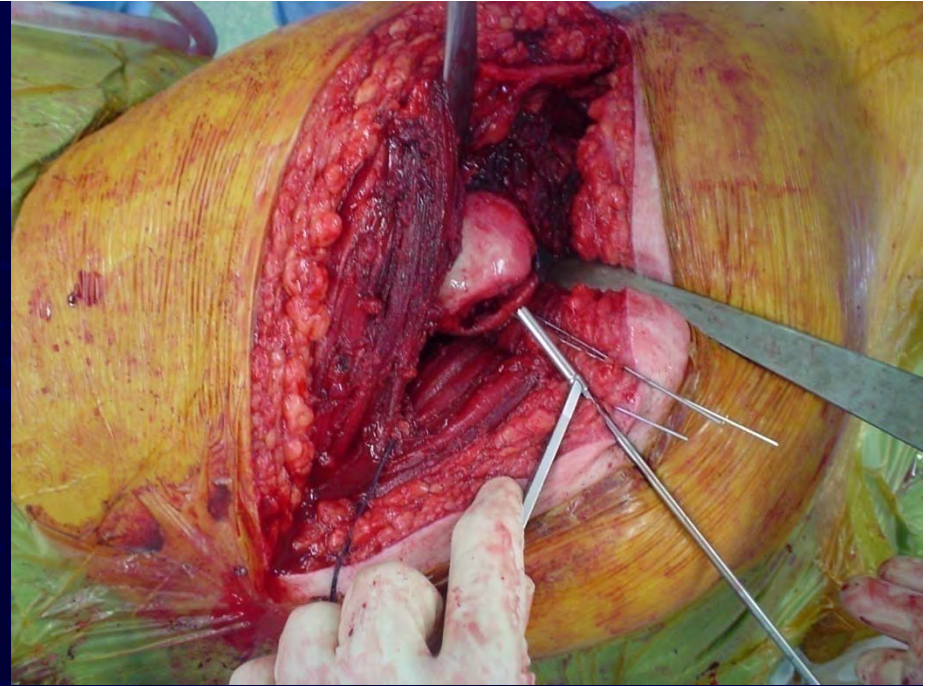


Require appropriate treatment of femoral head and acetabulum fractures.

Combination of fractures necessitates critical assessment of stability.

Have high incidence of post-traumatic osteoarthritis.

Many Options for Approach:



Femoral Head Fracture with Acetabulum Fractures

Kregor, AAOS, 2004

- 10 cases followed 28 months
- All had ORIF of both femoral head and acetabulum
- 6 Ganz trochanteric flip osteotomy, 3 anterior + posterior, 1 posterior.
- Results: 3 excellent, 6 good, 1 poor.
- “The Ganz Trochanteric Flip Osteotomy combined with surgical dislocation of the hip allows for optimal visualization and fixation of both injuries, controlled reduction of the hip, and thorough debridement of the hip joint.”

Questions?

If you would like to volunteer as an author for the Resident Slide Project or recommend updates to any of the following slides, please send an e-mail to ota@ota.org

[Return to
Lower Extremity
Index](#)

