


What is the Problem and
is There a Consensus?

OUTLINE
OTA 2013 Annual Meeting,
October 11, 2013

Michael D. McKee, MD, FRCS(C)
Professor, Division of Orthopaedics,
St. Michael's Hospital,
University of Toronto, Toronto, Canada.



Introduction


- Introduction – what is the problem?
- Additional imaging studies – CT, MRI, US
- Objective scores – are there any?
- How do we improve?

Problem

- There is no gold standard for the definition of fracture healing
- Inter- and intra- observer reliability with most measurements is low
- There is considerable variation in scores, methods and technique
- Union, time to union are critical to success or failure

Current Assessment

- Corrales LA et al “Variability in the assessment of fracture healing in orthopaedic trauma studies” JBJS(A) 2008
- 12 different clinical criteria
- 11 different radiographic criteria
- Bridging at fracture site most common criterion
- Only 2 studies assessed xray reliability quantitatively
- “Lack of consensus”
- “ad hoc defn’s of plain x-rays”



Reliability


- McClelland et. al. “Fracture healing assessment comparing stiffness measurements using radiographs” CORR 2007
- Correlated radiographic assessment with stiffness measurements of fractures
- General appearance / cortical bridging (2 or 3 cortices)
- “All groups performed poorly”

Reliability of fracture assessment

- Miric D et al, “Radiographic signs of scaphoid union after bone grafting: analysis of inter- and intra- observer reproducibility” 2005
- 15 sets (four views) of scaphoid nonunion post ORIF with bone grafting
- 7 surgeons of varying experience graded films as “yes / no” - are trabeculae crossing fracture site
- Inter-observer K: 0.46, intra-observer K: 0.54
- “Radiographic assessment not reliable or reproducible in this setting”

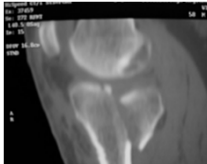
Prospective trial

- “Low-intensity ultrasound accelerates healing of scaphoid fractures” Mayr E et. al. AAOS 2000
- RCT of stable scaphoid fractures treated with cast versus cast + ultrasound
- 30 patients, all healed clinically and by xray
- Mean time to union 6.2 weeks in US group, 8.8 weeks in control
- CT every 2 weeks



CT scan

- “Bhattacharyya T et. al. “The accuracy of computed tomography for the diagnosis of tibial nonunion” JBJS(A) 2002
- 35 patients with equivocal findings
- “gold standard” – OR findings or observation
- Scans assessed by 2 radiologists, 1 surgeon
- K value 0.89, sensitivity 100%
- Accuracy 90%, specificity 62%
- 3 “nonunions” found to have been healed at OR



Radiographic outcomes

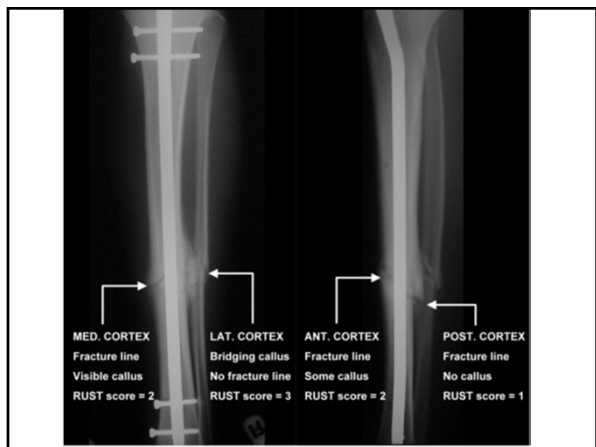
- Whelan et. al. “Interobserver and intraobserver variation in the assessment of the healing of tibial fractures after intramedullary fixation” JBJS(B) 2002
- 30 tibial fractures Rx with IM nail assessed by 4 orthopaedic surgeons at 2 separate times

<u>value</u>	<u>kappa</u>	
• Number of cortices bridged by callus:	0.75	0.89
• Number of cortices with visible fracture line:	0.70	0.82
• Extent of callus:	0.57	0.83
• Overall impression of healing:	0.67	0.82

- “Number of cortices bridged by callus a reliable

Radiographic Union Score for Tibial fractures

- Whelan et. al. "Development of the RUST score for the assessment of tibial fracture healing after intramedullary fixation" J Trauma (in press)
- Score of 1, 2 or 3 for each of four cortices (ant, post, med, lateral)
- No callus, fracture line = 1
- Callus, fracture line = 2
- Callus, no fracture line = 3
- Kappa values 0.80 – 0.85
- Reliable and reproducible score



Consensus opinion

- Objective scoring systems
- Union an important outcome
- Adjudication committee examines radiographs

