


OTA Speciality Day 2018- New Orleans
Subtle Syndesmotic Injuries: How I diagnose them and How to Fix

Kenneth A Egol MD

1. Due to their inherent instability, it is well established that syndesmotic fixation should be performed as part of standard care for rotational ankle fractures when indicated.
2. Evidence that this pattern of injury is associated with more pain and poorer function at one year compared to operative fractures without an associated syndesmotic injury
3. In many cases, the presence of syndesmotic disruption is identified pre-operatively and may be planned for.
 - a. Obvious widening
 - b. fracture pattern
 - c. dislocation
4. In other cases, intraoperative decision to proceed with syndesmotic stabilization is usually confirmed based on
 - a. Preop MRI
 - b. a fluoroscopic syndesmotic stress views, following malleolar fracture stabilization
5. The current standard of care for intraoperative assessment of the syndesmotic articulation is performed utilizing intraoperative two-dimensional (2D) fluoroscopy
 - a. Syndesmosis malreduction rate of up to 16%
6. A number of CT based measurement methods have been proposed at the level of the syndesmosis to evaluate the articulation and possible malreduction (Gardner, Marmor, Davidovitch)
7. Open Reduction with Direct visualization now favored by many
 - a. Fixation with screws or suture
 - b. Controversy still exists

REFERENCES

1. Mukhopadhyay, S., et al., *Malreduction of syndesmosis-Are we considering the anatomical variation?* Injury, 2011.
2. Zalavras, C. and D. Thordarson, *Ankle syndesmotic injury*. The Journal of the American Academy of Orthopaedic Surgeons, 2007. **15**(6): p. 330-9.
3. Egol, K.A., et al., *Outcome after unstable ankle fracture: effect of syndesmotic stabilization*. Journal of orthopaedic trauma, 2010. **24**(1): p. 7-11
4. Hovis, W.D., et al., *Treatment of syndesmotic disruptions of the ankle with bioabsorbable screw fixation*. The Journal of bone and joint surgery. American volume, 2002. **84-A**(1): p. 26-31.
5. Weening, B. and M. Bhandari, *Predictors of functional outcome following transsyndesmotic screw fixation of ankle fractures*. Journal of orthopaedic trauma, 2005. **19**(2): p. 102-8.
6. Chissell, H.R. and J. Jones, *The influence of a diastasis screw on the outcome of Weber type-C ankle fractures*. The Journal of bone and joint surgery. British volume, 1995. **77**(3): p. 435-8.
7. Elgafy, H., et al., *Computed tomography of normal distal tibiofibular syndesmosis*. Skeletal radiology, 2010. **39**(6): p. 559-64.
8. Marmor, M., et al., *Limitations of standard fluoroscopy in detecting rotational malreduction of the syndesmosis in an ankle fracture model*. Foot & ankle international / American Orthopaedic Foot and Ankle Society [and] Swiss Foot and Ankle Society, 2011. **32**(6): p. 616-22.
9. Gardner, M.J., et al., *Malreduction of the tibiofibular syndesmosis in ankle fractures*. Foot & ankle international / American Orthopaedic Foot and Ankle Society [and] Swiss Foot and Ankle Society, 2006. **27**(10): p. 788-92.



Syndesmosis II: Reduction tips (clamp orientation and force)

David E. Asprinio M.D.
3/10/2018

Syndesmotoc reduction

- Possible displacements
 - Coronal plane translation
 - Axial plane rotation
 - Sagittal plane translation (A-P)
 - Axial plane translation (M-L)
- Reduction modalities
 - Open versus closed
 - Direct ligament repair (via fracture reduction)
 - Clamp versus manual
- Clinical considerations
 - Clamp type
 - Clamp orientation
 - Force

The importance of fibular clamp position on syndesmotoc reduction

Hak & Judkins OTA 2011

- Hypothesized anterior and posterior clamp placement on fibula would malrotate the fibula
- 20 fresh frozen cadaver
- Medial - pointed tenaculum mid tibia
- Lateral -
 - Mid axis fibula
 - 5 mm anterior to mid axis
 - 5 mm posterior to mid axis
- Posterior placement resulted in external rotation

Iatrogenic syndesmotoc malreduction via clamp and screw placement

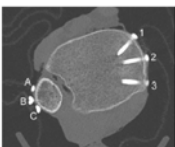
Miller et al JOT 2012

- 14 cadaveric specimen
 - All ligaments disrupted
 - Clamp placement at 0°, 15°, and 30°
- Results
 - 15° and 30°
 - fibula external rotation
 - over compression
- Screw placement also significant

Forceps reduction of the syndesmotoc in rotational ankle fractures: A cadaveric study

Phisitkul et al JBJS 2012

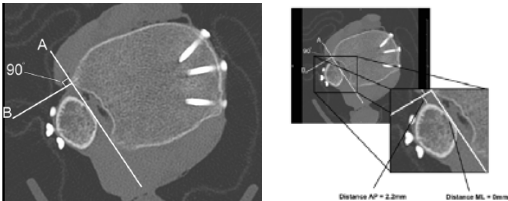
- 10 cadaveric specimen
- CT evaluation following serial destabilization and clamp placement at various angles
 - Lateral (A, B, C)
 - 5mm anterior, at and 5mm posterior to lateral malleolar ridge
 - Medial (C, A, B)
 - 10mm posterior, 10mm anterior, and at mid medial surface



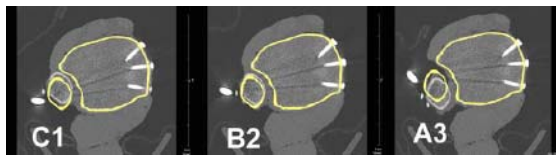
Forceps reduction of the syndesmotoc in rotational ankle fractures: A cadaveric study

Phisitkul et al JBJS 2012

- Described reproducible method to assess sagittal plane displacement and medialization of fibula



Forceps reduction of the syndesmosis in rotational ankle fractures: A cadaveric study



- Both obliquely oriented clamp placement consistently cause fibula medial displacement in the sagittal plane
- Clamp placement in the neutral anatomic axis most accurately reduced syndesmosis albeit with slight over compression

Phisitkul et al JBJS 2012

Simulating clamp placement across the trans-syndesmotc angle of the ankle to minimize malreduction: A radiological study

Sara M. Putnam^{1,2}, Michael S. Linn^{3,1}, Amanda Spraggs-Hughes^{3,1}, Christopher M. McAndrew⁴, William M. Ricci¹, Michael J. Gardner^{1,2,4}

¹Washington University School of Medicine, Department of Orthopaedic Surgery, 660 South Euclid Avenue, Campus Box 8233, St. Louis, MO 63110, United States
²SMH - Department of Orthopaedic Surgery, 301 East Main Street, Bay Shore, NY 11706, United States
³Stanford University School of Medicine, Department of Orthopaedic Surgery, 400 Broadways, MC 6342, Redwood City, CA 94063, United States

Injury 2017

- Axis distal tibia and fibula joint identified on CT uninjured ankle
- Optimal clamp tine positioning presumed perpendicular to joint axis
Trans-syndesmotc angle (TSA)
- Medial tine position identified on three-dimensional reconstruction
Typically anterior third on lateral projection

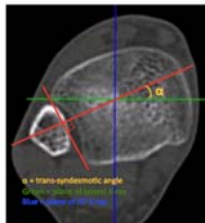


Fig. 4. The trans-syndesmotc angle (TSA) was measured by drawing a line perpendicular to the joint axis on an axial CT at 1 cm proximal to the distal phalanx, referenced from the plane of a 3 mm-diam. dorsal view of the ankle joint.

Medial clamp tine position may affect reduction accuracy during syndesmotc reduction

Cosgrove et al JOT 2017

- Prospective cohort 72 patients (3 surgeons)
- Obtained:
 - #1 Fluoroscopic talar dome lateral projection documenting tine position
 - #2 Postoperative CT scan

Medial clamp tine position may affect reduction accuracy during syndesmotc reduction

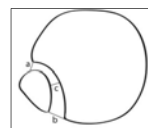
Cosgrove et al JOT 2017

- Tine placement (fluoroscopic image)

– Anterior third	18 (33.3%)	} nsd
– Central third	31 (57.4%)	
– Posterior third	5 (9.3%)	
- Malreduction >2 mm (CT scan)
- **Measurement a**
 - 0% anterior third
 - 19.4% middle third
 - 60% posterior third

} P = 0.006
- **Measurement b**
 - 11.1% anterior third
 - 16.1% middle third
 - 60% posterior third

} P = 0.062



Increased Reduction Clamp Force Associated With Syndesmotc Overcompression

- Purpose - to quantify and evaluate the effect of clamp force on oblique coronal plane fibula reduction
- 21 prospectively identified patients
 - 9 Weber B
 - 12 Weber C
- Reduction achieved using modified periarticular reduction forceps with load cell

Haynes et al Foot Ankle Int. 2016

Increased Reduction Clamp Force Associated With Syndesmotc Overcompression

- Reduction maintained with 1 or 2 3.5 mm trans-syndesmotc quadricortical position screws
- Clamp reduction force recorded (surgeon blinded to result)
- CT scan obtained postoperatively
 - Overcompression >1 mm fibula medialization
 - Under compression >1mm fibula lateralization

Haynes et al Foot Ankle Int. 2016

Increased Reduction Clamp Force Associated With Syndesmotic Overcompression

Haynes et al Foot Ankle Int. 2016

- Clamp force was highly variable between surgeons
- Although compression force was different between groups there was significant overlap
- Additional limitation: Utilized single type of reduction clamp

Impact of clamp placement on reduction of the ankle syndesmosis

Bunch et al ORS 2015

- Purpose - to assess the effect of clamp placement with respect to orientation and location above the plafond
- 13 fresh frozen human cadaver
- Deltoid ligaments and syndesmosis divided
- Clamps placed at neutral and 30° in coronal plane at 1, 2, 3, 4, and 5 cm proximal to plafond

Impact of clamp placement on reduction of the ankle syndesmosis

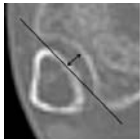
Bunch et al ORS 2015

- Coronal axis clamp placement significantly displaced fibula posteriorly at all levels
- Coronal axis clamp placement significantly displaced fibula laterally as a group

Incisura Morphology as a Risk Factor for Syndesmotic Malreduction

Cherney et al Foot Ankle Int. 2016


- 35 prospectively enrolled patients
- Postoperative CT to assess incisura depth and syndesmotic reduction
- Contralateral (normal) control
- "Shallow" (≤ 2.5 mm)
- "Non deep" (2.6-4.4 mm)
- "Deep" (≥ 4.5 mm)



Incisura Morphology as a Risk Factor for Syndesmotic Malreduction

Cherney et al Foot Ankle Int. 2016

- "Shallow" (≤ 2.5 mm)
 - 6/8 anteriorly malreduced ($p < 0.001$)
- "Non deep" (2.6-4.4 mm)
- "Deep" (≥ 4.5 mm)
 - 5/9 posteriorly malreduced ($p < 0.02$)
 - Malrotation more likely



Comparison of clamp reduction and manual reduction of syndesmosis and rotational ankle fractures: A prospective randomized trial

Park et al, J Foot Ankle Surg 2017

- Prospective randomized
- 85 acute rotational fractures with syndesmotic injury
- Forceps versus manual reduction
- Postop assessment
 - Tibiofibular clear space
 - Tibiofibular overlap
 - Medial clear space
 - Ankle ROM
 - VAS
 - Olerud-Molander score
 - Complications

($p < 0.5$)

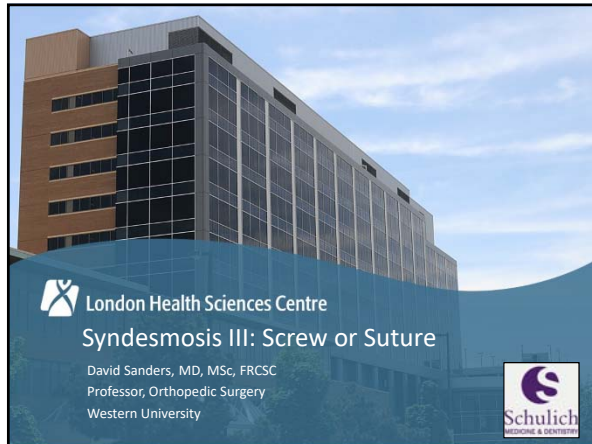
($p > 0.5$)

Intraoperative radiographic evaluation

- Fluoroscopy/plain film radiographs
 - Tibiofibular clear space
 - Tibiofibular overlap
 - Medial clear space
 - Talar tilt angle
 - Talocrural angle
 - Trilateral intervals
 - Shenton's line
 - Dime sign
 - Talar dome lateral
- 3-D fluoroscopy
- Intraoperative CT scan

Take home:

- Consistent anatomic reduction of the distal tibiofibular joint remains elusive
- Keys to success
 - Understanding planes of deformity
 - Anatomic fracture reduction
 - (esp. fibula and posterior malleolus)
 - Open visualization of joint
 - Judicious use of reduction clamps
 - Proper clamp orientation and force application
 - Understanding incisura morphology
 - Fastidious radiographic evaluation



Disclosures

- Consulting
 - Smith and Nephew
 - Stryker
- Grant funding
 - OTA / Arthrex
 - Smith and Nephew
 - BURST
 - AMOSO
 - CIHR

London Health Sciences Centre Schulich logo

Syndesmosis controversies

➤ What is the best fixation for the tibio-fibular syndesmosis – screw or suture?

- Reduction quality
- Clinical outcomes
- Cost concerns

London Health Sciences Centre Schulich logo

Syndesmosis Reduction

- Gardner Foot Ankle Int 2006
- Malreduction
 - 24 % Xray
 - 52 % CT
- Sensitivity of Xray is 31 %

London Health Sciences Centre Schulich logo

What's the difference between techniques?

London Health Sciences Centre Schulich logo

Reduction with Tightrope


- “iatrogenic malreduction” with clamp and screw placement

Miller et al. JOT 2013; Cosgrove et al. JOT 2017

London Health Sciences Centre Schulich logo


Best evidence for reduction and outcomes

- 1 good quality cohort study
- **5 RCT's**
 - 4 good quality



Reduction quality


- CT based findings:
 - Naqvi 22 % diastasis in screw group
 - Kortekangas (2 yr) (p=0.33) 3 malreductions in screw group
1 malreduction in suture group
 - Andersen (2 yrs) (p=0.009) 20/40 malreductions in screw group
8/ 40 in suture group
 - COTS (3 mo) 39 % malreduction in screw group



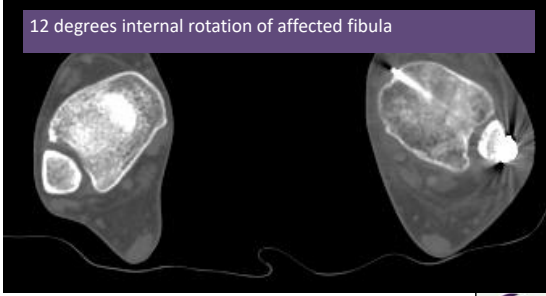

Malreduction rate based on CT

Study / author	Screw malreduction rate	Suture malreduction rate
Naqvi (p<0.05)	21 %	0 %
Kortekangas (2 yr) P=0.33	14 %	5 %
Andersen (2 yr) P=0.009	50 %	20 %
COTS (3 mo) P=0.03	39 %	15 %

- Fibular rotation, fibular translation, compression / distraction




12 degrees internal rotation of affected fibula

Radiographic results


- CT results (COTS study):

Measurement	Tightrope	Screw	P value
Syndesmosis distance			
Anterior	5.4 ± 1.8	4.6 ± 1.5	0.04
Posterior	9.8 ± 2.3	10.0 ± 2.1	0.65
Mid	4.1 ± 1.2	3.8 ± 1.4	0.18
Fibular translation			
Anterior	10.2 ± 1.7	10.6 ± 2.2	0.42
Posterior	7.3 ± 1.9	7.2 ± 2.0	0.89
Medial compression	1.0 ± 1.8	0.3 ± 1.8	0.05
Fibular rotation angle	12.1 ± 6.4	13.0 ± 7.2	0.54
Articular rotation angle	11.4 ± 4.9	10.2 ± 5.9	0.28




Functional outcomes

- Naqvi AmJSportMed 2012
 - N=46; No significant difference in outcome scores (AOFAS, Foot and Ankle Disability Index (FADI))
- Kortekangas Injury 2015
 - n=40; No difference in outcome
- Laffamme JOT 2015
 - N=70
 - Outcomes:
 - Slightly improved Olerud Molander (93.3 vs 87.6 at 12 months) in tightrope group
 - Slight improvements in plantar flexion in tightrope group



Functional outcomes cont'd


- **Andersen JBJS 2018 (n=97)**
 - 2yr outcomes better in suture group (AOFAS, p=0.001; OM, p<0.001)
 - Less pain with walking in suture group
- **COTS OTA 2017 (n=103)**
 - NO difference in EQ5D, FADI, OM, WPAI



Summary of Evidence


- Compared to screw fixation, the tightrope device is....

Study	Reduction	Outcomes
Coetzee et al	=	=
Kortekangas	=	=
Naqvi	+	=
Laflamme	+	+
Andersen	+	+
COTS	+	=




Cost considerations

- **Implant cost**
 - Suture 550 – 1200 \$ / implant
 - Screw 8 – 25 \$ / implant
- **Hardware removal**
 - May offset the increased cost of the hardware
 - Reoperation rate (COTS):
 - Suture 4 %
 - Screw 30 %




Direct cost comparisons

- Neary, Mormino, Wang (AJSM, 2016)
- Total cost including hardware removal –
 - Two cortical screws \$20,836 \$3564/QALY
 - (20% Removal)
 - Suture button \$19,354 \$3294/QALY
 - (4% Removal)




Summary


- Improved reduction using Suture button compared to Screw fixation
- Probable improvement in clinical outcomes
- Cost issues equivocal



Screw or Suture?



Thank you!



References

Outcome studies

- Naqvi AJSM 2012 (cohort)
- Coetzee SA Orthop J 2012 (small RCT)
- Kortekangas Injury 2015 (n=43)
- Laflamme JOT 2015 (n=70)
- Andersen JBJS 2018 (n=97)
- COTS JOT 2018 (submitted, n=103)



Specialty Day

New Orleans, LA

March 10, 2018

ANKLE FRACTURE CONTROVERIES: HARWARE REMOVAL - IF AND WHEN?

Eric D. Farrell, M.D.

Assistant Professor, Orthopaedic Surgery

UCLA School of Medicine

I. INTRODUCTION

- REMOVAL OF HARDWARE (ROH)– ONE MOST COMMON SURGICAL PROCEDURES -\$\$\$
- CONTROVERSY IN THE LITERATURE RE: RISKS AND BENEFITS
- CONTROVERST IN THE LITERATURE ON “WHEN”
- THERE IS LITERATURE TO SUPPORT MANY DIFFERENT TREATMENT PLANS
- CONCLUSION OF MOST STUDIES – “FURTHER INVESTIGATION/STUDY INTOIS NEEDED”

II. RISKS

- IT’S A SURGICAL PROCEDURE.....
- BAD THINGS CAN HAPPEN IN THE HOSPITAL
- INFECTION
- NEUROVASCULAR INJURY
- REFRACTURE/LOSS REDUCTION
- OPPORTUNITY COST
- COMPLICATION RATE OF 22.4% REPORTED FOLLOWING REMOVAL SYNDESMOTIC SCREWS (SCHEPERS ET AL., 2011)

III. INFECTION

- POST OP WOUND INFECTION (POWI) IS NOT INSIGNIFICANT
- RATE AS HIGH AS 11.6% (BACKES ET AL. 2015)
- POWI FOLLOWING REMOVAL SYNDESMOTIC SCREW = 9.2% - (SCHEPERS ET AL, 2011)

IV. SYNDESMOTIC SCREW REMOVAL

- LITERATURE BROAD
- LOSS OF REDUCTION IF SCREWS REMOVED TO EARLY (PRIOR TO HEALING)
- LITERATURE TO SUPPORT MINIMUM OF 3 MONTHS BEFORE ROH
- BROKEN SCREW(S) MAY NOT NECESSITATE ROH – STUDIES -> PATIENTS SHOW IMPROVED FUCNTION WITH BROKEN, LOOSENED OR REMOVED SCREWS (MANJOO ET AL. 2010)
- RECENT LITERATURE TO SUPPORT REMOVAL AT 3 MONTHS – IMPROVED SUBJECTIVE AND OBJECTIVE FUNCTION (MILLER ET AL, 2010)

V. LATERAL PLATE REMOVAL

- NOT DIFFERENCE IN SYMPTOMATIC HARWARE BETWEEN LATERAL AND POSTERIOR PLATING
- RECENT STUDY SUGGESTS INCREASE RATE OF REMOVAL OF CONTOURED LOCKED FIBULAR PLATES VS STANDARD 1/3 TUBULAR PLATE (MOSS ET AL, SCIENTIFIC POSTER 2016 OTA)
- LITERATURE TO SUPPORT IMPROVED SYMPTOMS/FUNCTION S/P REMOVAL OF SYMPTOMATIC LATERAL PLATES
- FRATURES MUST BE HEALED BEFORE ROH

VI. REMOVAL OF IMPLANTS IN SETTING OF INFECTION

- LITERATURE (FEW ARTICLES) TO SUPPORT MAITENANCE OF IMPLANTS/SUPPRESSION OF INFECTION UNTIL UNION IS ACHIEVED (WHEN POSSIBLE)
- MULTI-SPECIALTY APPROACH (PLASTIC SURGERY, ID, MEDICINE,ETC)
- MORE STUDY IS NEEDED
- (OVASKA ET AL. : INJURY, 2013), (P BONNEVIALLE: ORTHOPAEDICS AND TRAUMATOLOGY: SURGERY AND RESEARCH, 2017), (BERKES ET AL.: JBJS, 2010)

VII. CONCLUSIONS

- LITERATURE CAN BE HIGHLY VARIABLE REGARDING SOME ASPECTS OF ROH
- FURTHER RESEARCH- PROSPECTIVE RANDOMIZED STUDIES BENEFICIAL
- PREMATURE ROH INCREASES RISK FOR FAILURE/COMPLICATION
- ROH IS NOT WITHOUT RISK – PHSYCIANS KNOW THEIR PATIENTS BEST -> WEIGH BENEFITS VS POTENTIAL COMPLICATIONS
- BROKEN SYNDESMOTIC SCREWS MAY NOT HAVE TO BE REMOVED
- SYMPTOMATIC IMPLANTS MAY IMPROVE FUNCTON/SX – (HOWEVER YOU CAN'T GUARANTEE.)
- DON'T DISCOUNT THE PHYSCOLOGICAL EFFECT (MUST WEIGH AGAINST RISKS)
- BE PREPARED FOR UNEXPECTED INTRA-OP FINDINGS (NONUNION/LOSS OF REDUCTION) AND HAVE A PLAN.