

OTA Tip-of-the-Month – October 2011

Use of AO Distractor for Proximal Humerus

M. Bradford Henley MD, MBA - OTA President 2000-2001, Professor, Department of Orthopaedic Surgery and Sports Medicine, University of Washington

Anna N. Miller MD - Assistant Professor, Orthopaedic Surgery, Wake Forest University School of Medicine

Displaced and comminuted proximal humeral fractures are commonly treated using an open approach. Obtaining fracture reduction can be challenging, especially in younger, muscular individuals with shortening, bayonet apposition and/or impaction. (Figure 1) The humeral shaft may be completely separated at the surgical neck from the remaining humeral head and metaphyseal fragments. The multiple muscular attachments to the humerus can pull the diaphysis or metaphyseal fragments proximally, medially, and anteriorly, resulting in further fracture displacement; this also interferes with visualization and reduction. We present a technique to assist in the restoration of limb length and fracture reduction by using a distractor. The technique uses an AO universal distractor with placement of 4.0 mm, terminally threaded Schanz pins in the base of the coracoid process and in the anterior humeral shaft. Alternatively, the proximal pin may be placed into the humeral head, from anterior to posterior at the level of the lesser tuberosity. It is important that the surgeon place the humeral diaphyseal pin to avoid interference with planned placement of final fixation. This pin is usually placed in the sagittal plane, lateral to the biceps and in the proximal humeral diaphysis. The coracoid (or proximal humeral) pin is placed in the same anterior to posterior plane, with the arm abducted between 60 and 90 degrees. Both pin trajectories are first predrilled with 2.5 mm drill bits, and fluoroscopic imaging is used to confirm these trajectories, as well as depth of insertion. Figure 2 shows an intraoperative antero-posterior radiographic view with the universal distractor in place.

We suggest that a lateral plate should be of sufficient length to extend beyond the distal 4.0 mm distractor pin site, to protect this potential stress-riser.

Finally, the universal distractor should be placed so that it does not interfere with intraoperative fluoroscopic imaging. Figure 3 shows an intraoperative axillary view with the I distractor in place.

Figure 1

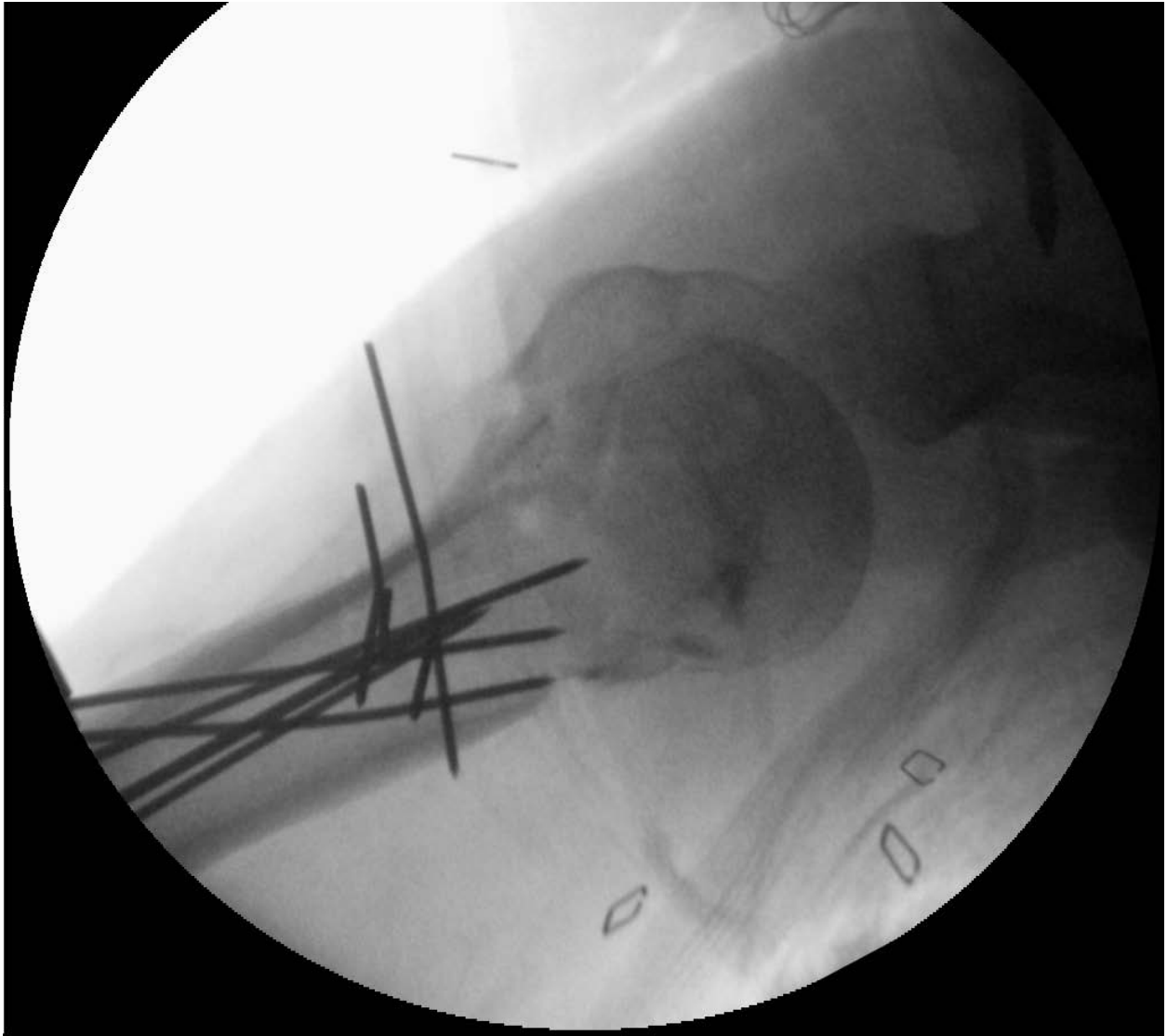

Figure 1: UNSATISFACTORY REDUCTION: This axillary lateral of a comminuted proximal humerus fracture was made after K-wire fixation of the meta-diaphysis. Note that the humeral head appears to be reduced to the metaphysis, however, the lesser tuberosity fragment remains unreduced, since humeral length has not been restored, and there is insufficient room for this fragment between the head and the humeral meta-diaphysis.

Figure 2

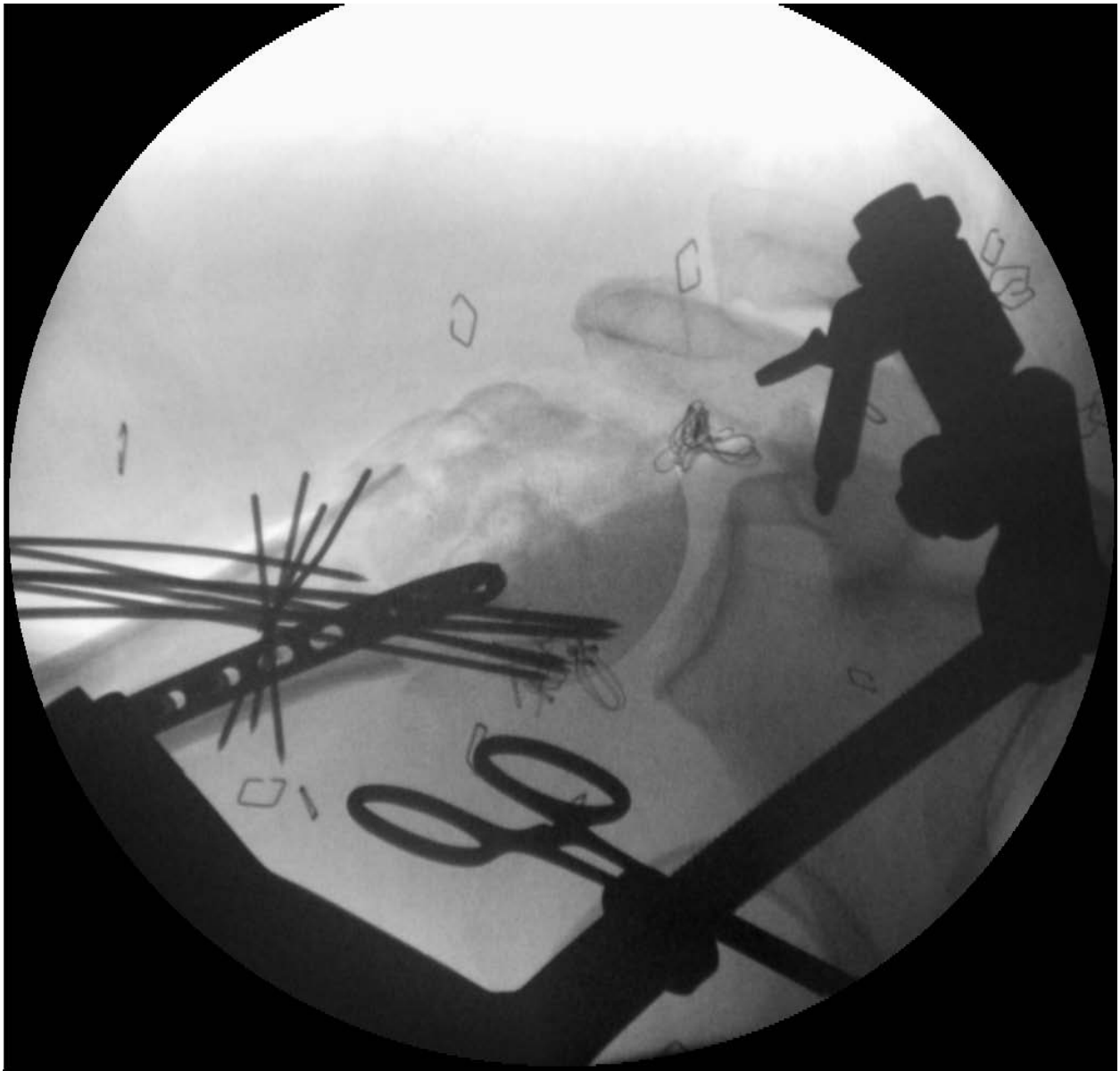

Figure 2: AP view after application of an anterior distractor. Additional distraction allows reduction of the lesser tuberosity, which has been stabilized provisionally with an anterior 2.7mm plate.

Figure 3

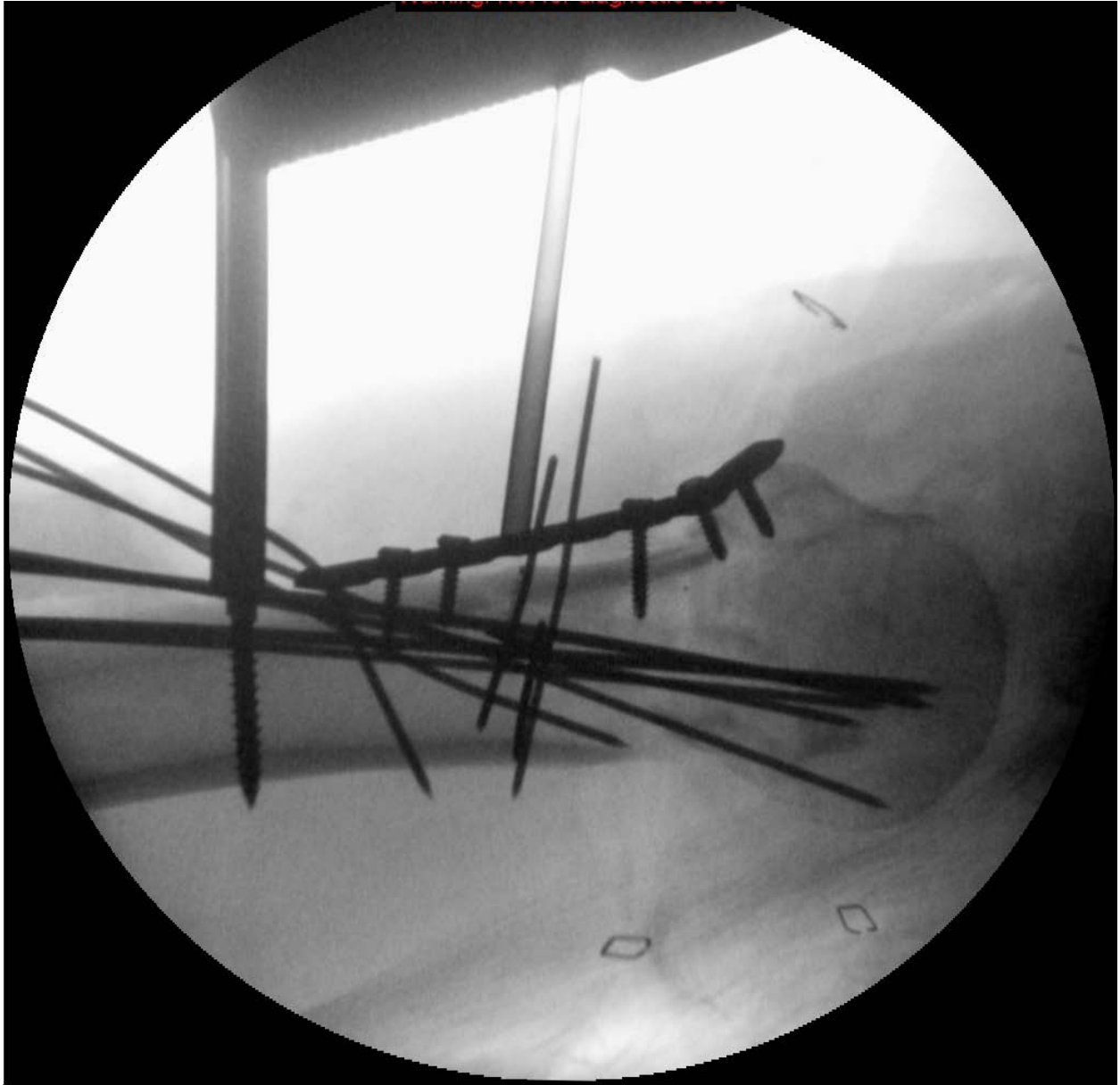


Figure 3: Axillary lateral radiograph, after distraction and provisional fixation. Next, a lateral proximal humeral locking plate was applied. Then the provisional unicortical screws were replaced with bicortical screws in the shaft segment and locking screws in the humeral head.