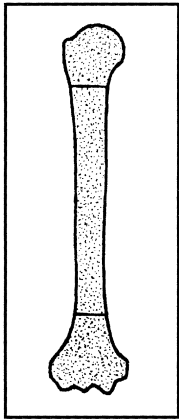
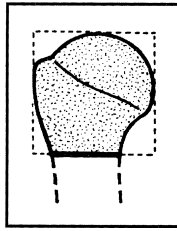


# HUMERUS

**BONE: HUMERUS (1)**

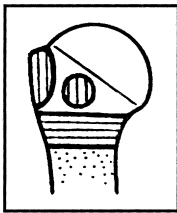


**Location: Proximal segment (11)**

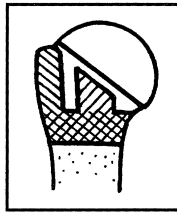


**Types:**

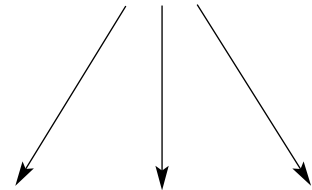
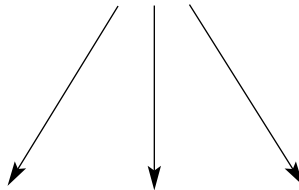
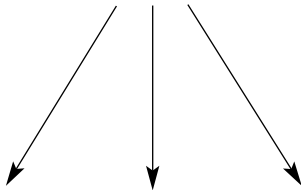
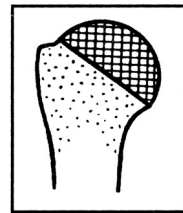
**A. Extra-articular, unifocal fracture (11-A)**



**B. Extra-articular, bifocal fracture (11-B)**



**C. Articular fractures (11-C)**



**Groups:**

Humerus proximal segment, extra-articular unifocal (11-A)

**1. Avulsion of tuberosity (11-A1)**

**2. Impacted metaphysis (11-A2)**

**3. Non-impacted metaphysis fracture (11-A3)**

Humerus, proximal segment, extra-articular bifocal (11-B)

**1. With metaphyseal impaction (11-B1)**

**2. Without metaphyseal impaction (11-B2)**

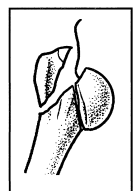
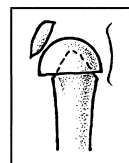
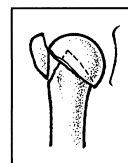
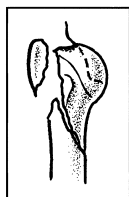
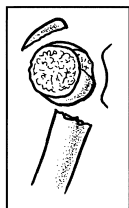
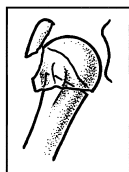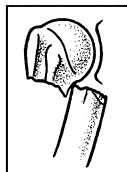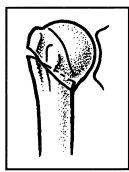
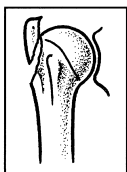
**3. With glenohumeral dislocation (11-B3)**

Humerus, proximal segment, articular fractures (11-C)

**1. Articular fracture with slight displacement impacted valgus fracture (11-C1)**

**2. Articular fracture impacted with marked displacement (11-C2)**

**3. Articular fracture with glenohumeral dislocation (11-C3)**



These fractures represent three part fractures, or fracture dislocations by the Neer classification.



Humerus, proximal, extra-articular, bifocal, with metaphyseal impaction (11-B1)

**1. Lateral plus greater tuberosity**  
(11-B1.1)

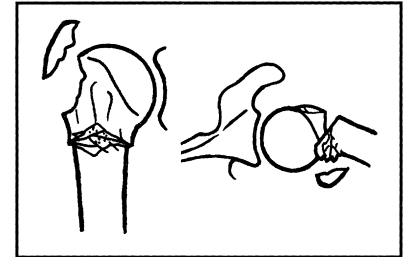
- (1) pure lateral impaction
- (2) posterior and lateral impaction
- (3) anterior and lateral impaction

**2. Medial plus lesser tuberosity**  
(11-B1.2)

- (1) pure lateral impaction
- (2) posterior and lateral impaction
- (3) anterior and lateral impaction

**3. Posterior plus greater tuberosity**  
(11-B1.3)

**B1**



Humerus, proximal, extra-articular, bifocal, without metaphyseal impaction (11-B2)

**1. Without rotatory displacement of the epiphyseal fracture fragment**  
(11-B2.1)

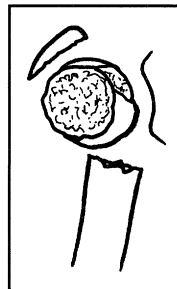
**2. With rotatory displacement of the epiphyseal fracture fragment** (11-B2.2)

- (1) greater tuberosity separated
- (2) lesser tuberosity separated

**3. Multifragmentary metaphysis plus one of the tuberosities** (11-B2.3)

- (1) lesser tuberosity
- (2) greater tuberosity

**B2**



Humerus, proximal, extra-articular, bifocal with glenohumeral dislocation (11-B3)

**1. "Vertical" cervical line plus greater tuberosity intact plus anterior medial dislocation** (11-B3.1)

**2. "Vertical" cervical line plus greater tuberosity fracture plus anterior medial dislocation** (11-B3.2)

**3. Lesser tuberosity fracture plus posterior dislocation** (11-B3.3)

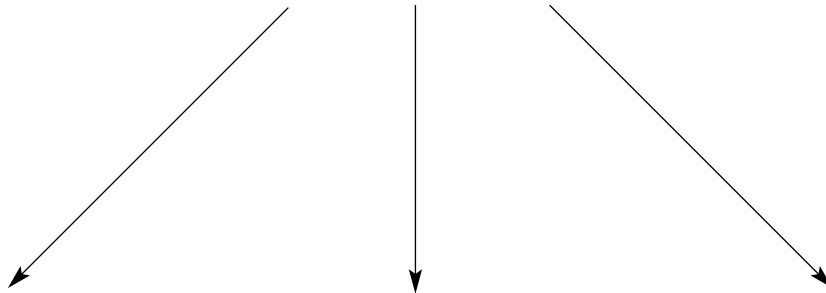
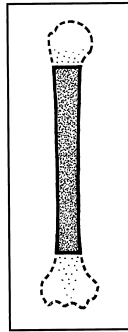
- (1) without anterior cephalic notch
- (2) with anterior cephalic notch

**B3**



**BONE: HUMERUS (1)**

**Location: Diaphyseal segment (12)**

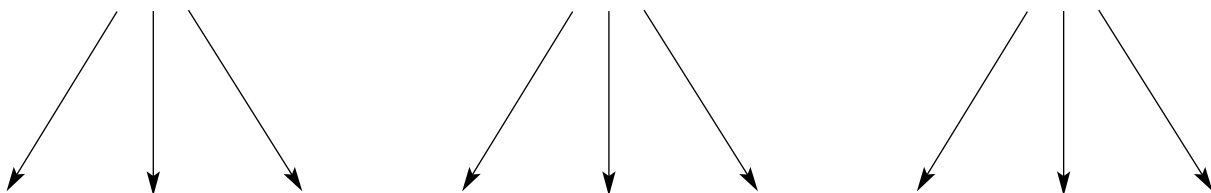
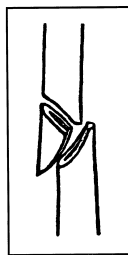


**Types:**

**A. Simple fracture (12-A)**

**B. Wedge fracture (12-B)**

**C. Complex fracture (12-C)**



**Groups:**

Humerus diaphyseal, simple (12-A)

**1. Spiral**  
(12-A1)

**2. Oblique**  
( $\geq 30^\circ$ ) (12-A2)

**3. Transverse**  
( $< 30^\circ$ ) (12-A3)

Humerus diaphyseal, wedge (12-B)

**1. Spiral wedge**  
(12-B1)

**2. Bending wedge**  
(12-B2)

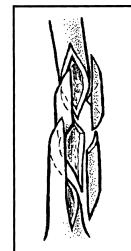
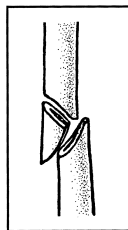
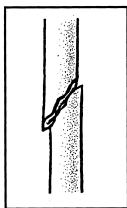
**3. Fragmented wedge**  
(12-B3)

Humerus diaphyseal, complex (12-C)

**1. Spiral**  
(12-C1)

**2. Segmental**  
(12-C2)

**3. Irregular**  
(12-C3)



**Subgroups and Qualifications:**


Humerus diaphyseal, simple, spiral (12-A1)

1. Proximal zone (12-A1.1)

2. Middle zone (12-A1.2)

3. Distal zone (12-A1.3)

**A1**




Humerus diaphyseal, simple, oblique ( $\geq 30^\circ$ ) (12-A2)

1. Proximal zone (12-A2.1)

2. Middle zone (12-A2.2)

3. Distal zone (12-A2.3)

**A2**



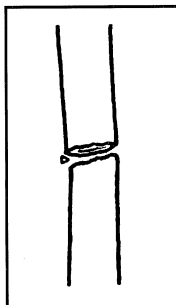
Humerus diaphyseal, simple, transverse ( $< 30^\circ$ ) (12-A3)

1. Proximal zone (12-A3.1)

2. Middle zone (12-A3.2)

3. Distal zone (12-A3.3)

**A3**



Humerus diaphyseal, wedge, spiral (12-B1)

1. Proximal zone (12-B1.1)

2. Middle zone (12-B1.2)

3. Distal zone (12-B1.3)

**B1**

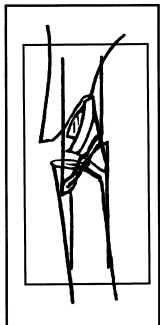
Humerus diaphyseal, wedge, bending (12-B2)

1. Proximal zone (12-B2.1)

2. Middle zone (12-B2.2)

3. Distal zone (12-B2.3)

**B2**



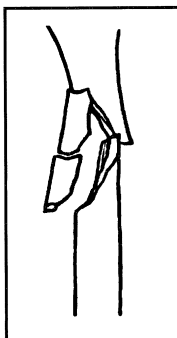Humerus diaphyseal, wedge, fragmented (12-B3)

1. Proximal zone (12-B3.1)

2. Middle zone (12-B3.2)

3. Distal zone (12-B3.3)

**B3**



Humerus diaphyseal, complex, spiral (12-C1)

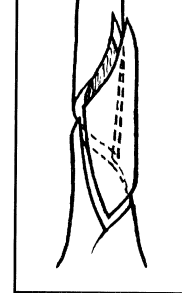
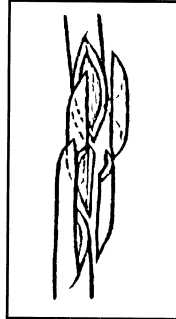
- (1) pure diaphyseal
- (2) proximal diaphysio-metaphyseal
- (3) distal diaphysio-metaphyseal

**1. With 2 intermediate fragments**  
(12-C1.1)

**2. With 3 intermediate fragments**  
(12-C1.2)

**3. With more than 3 intermediate fragments**  
(12-C1.3)

**C1**



Humerus, diaphyseal, complex segmental (12-C2)

**1. With 1 intermediate segmental fragment**  
(12-C2.1)

- (1) pure diaphyseal
- (2) proximal diaphysio-metaphyseal
- (3) distal diaphysio-metaphyseal
- (4) oblique lines
- (5) transverse and oblique lines

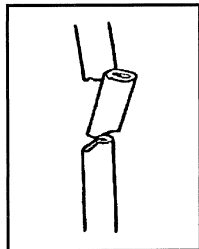
**2. With 1 intermediate segmental and additional wedge fragments**  
(12-C2.2)

- (1) pure diaphyseal
- (2) proximal diaphysio-metaphyseal
- (3) distal diaphysio-metaphyseal
- (4) distal wedge
- (5) 2 wedges, proximal and distal

**3. With 2 intermediate segmental fragments**  
(12-C2.3)

- (1) pure diaphyseal
- (2) proximal diaphysio-metaphyseal
- (3) distal diaphysio-metaphyseal

**C2**



Humerus, diaphyseal, complex irregular (12-C3)

**1. With 2 or 3 intermediate fragments**  
(12-C3.1)

- (1) 2 main intermediate fragments
- (2) 3 main intermediate fragments

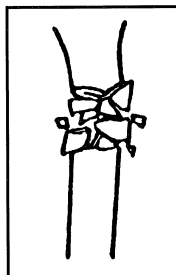
**2. With limited shattering (<4cm)**  
(12-C3.2)

- (1) proximal zone
- (2) middle zone
- (3) distal zone

**3. With extensive shattering (>4cm)**  
(12-C3.3)

- (1) pure diaphyseal
- (2) proximal diaphysio-metaphyseal
- (3) distal diaphysio-metaphyseal

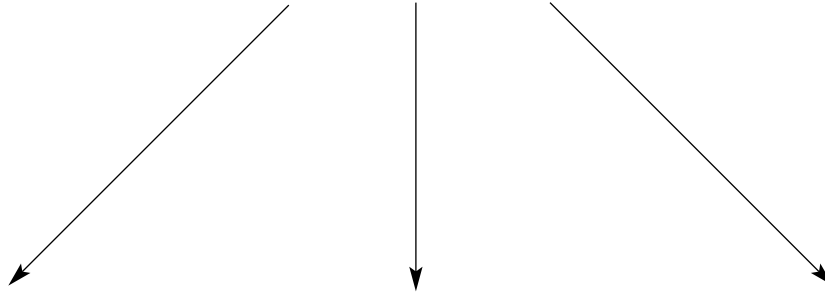
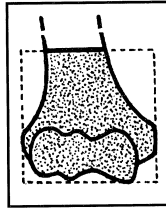
**C3**





**BONE: HUMERUS (1)**

**Location: Distal segment (13)**

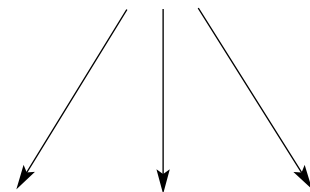
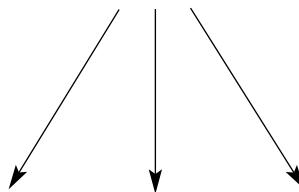
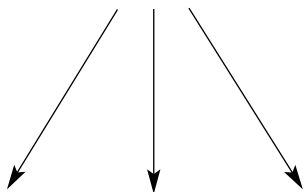
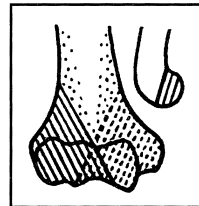


**Types:**

**A. Extra-articular fracture (13-A)**

**B. Partial articular fracture (13-B)**

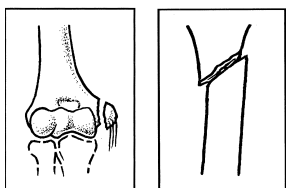
**C. Complete articular fracture (13-C)**



**Groups:**

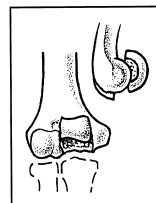
Humerus distal segment, extra-articular (13-A)

- 1. Apophyseal avulsion (13-A1)
- 2. Meta-physeal simple (13-A2)
- 3. Meta-physeal multi-fragmentary (13-A3)



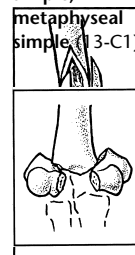
Humerus distal segment, partial articular (13-B)

- 1. Lateral sagittal (13-B1)
- 2. Medial sagittal (13-B2)
- 3. Frontal (13-B3)



Humerus distal segment, complete articular (13-C)

- 1. Articular simple, metaphyseal simple (13-C1)
- 2. Articular simple, meta-physeal multi-fragmentary (13-C2)
- 3. Articular, metaphyseal multifragmen-tary (13-C3)



**Subgroups and Qualifications:**

Humerus, distal, extra-articular apophyseal avulsion (13-A1)

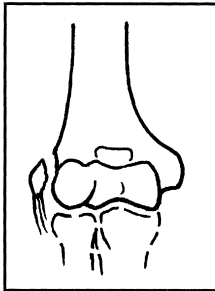
**1. Lateral epicondyle (13-A1.1)**

**2. Medial epicondyle, non-incarcerated (13-A1.2)**

- (1) non-displaced
- (2) displaced
- (3) fragmented

**3. Medial epicondyle, incarcerated (13-A1.3)**

**A1**



Humerus, distal, extra-articular metaphyseal simple (13-A2)

**1. Oblique downwards and inwards (13-A2.1)**

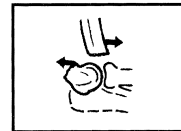
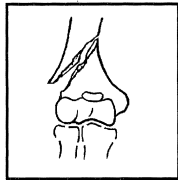
**2. Oblique downwards and outwards (13-A2.2)**

**3. Transverse (13-A2.3)**

(2) juxta-epiphyseal with posterior displacement (Kocher I)

(3) juxta-epiphyseal with anterior displacement (Kocher II)

**A2**



Humerus, distal, extra-articular metaphyseal multifragmentary (13-A3)

**1. With intact wedge (13-A3.1)**


- (1) lateral
- (2) medial

**2. With fragmented wedge (13-A3.2)**

- (1) lateral
- (2) medial

**3. Complex (13-A3.3)**

**A3**



Humerus, distal, partial articular lateral sagittal (13-B1)

**1. Capitellum (13-B1.1)**

- (1) through the capitellum (Milch I)
- (2) between capitellum and trochlea

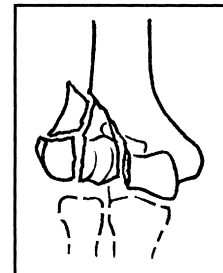
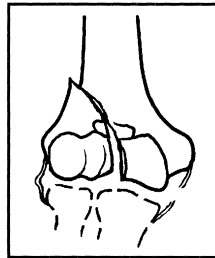
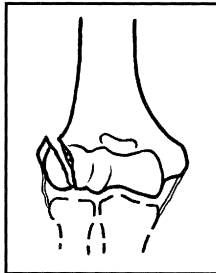
**2. Transtrochlear simple (13-B1.2)**

- (1) medial collateral ligament intact
- (2) medial collateral ligament ruptured
- (3) metaphyseal simple (classic Milch II) lateral condyle
- (4) metaphyseal wedge
- (5) metaphysio-diaphyseal

**3. Transtrochlear multifragmentary (13-B1.3)**

- (1) epiphysio-metaphyseal
- (2) epiphysio-metaphyseal-diaphyseal

**B1**



Humerus, distal, partial articular, medial sagittal (13-B2)

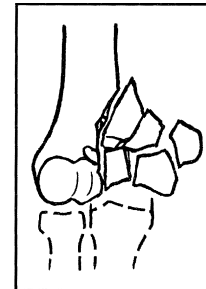
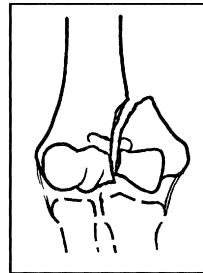
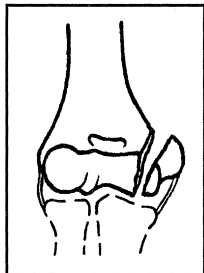
**1. Transtrochlear simple, through medial side (Milch I) (13-B2.1)**

**2. Transtrochlear simple, through the groove (13-B2.2)**

**3. Transtrochlear multifragmentary (13-B2.3)**

- (1) epiphysio-metaphyseal
- (2) epiphysio-metaphyseal-diaphyseal

**B2**



Humerus, distal, partial articular, frontal (13-B3)

**1. Capitellum (13-B3.1)**

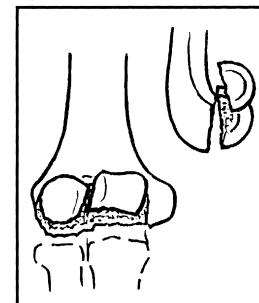
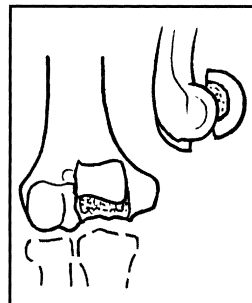
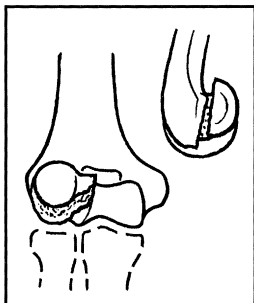
- (1) incomplete (Kocher-Lorenz)
- (2) complete (Hahn-Steinthal 1)
- (3) with trochlear component (Hahn-Steinthal 2)
- (4) fragmented

**2. Trochlea (13-B3.2)**

- (1) simple
- (2) fragmented

**3. Capitellum and trochlea (13-B3.3)**

**B3**

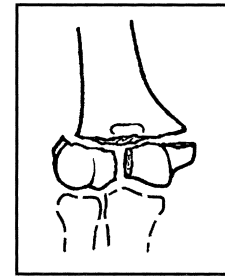
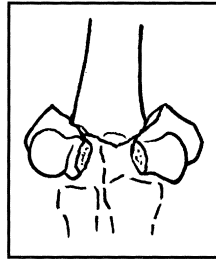
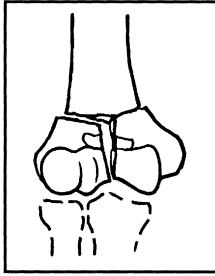


Humerus, distal complete, articular simple, metaphyseal simple (13-C1)

- |   |   |
|---|---|
| <p><b>1. With slight displacement (13-C1.1)</b><br/>                 (1) Y-shaped<br/>                 (2) T-shaped<br/>                 (3) V-shaped</p> | <p><b>2. With marked displacement (13-C1.2)</b><br/>                 (1) Y-shaped<br/>                 (2) T-shaped<br/>                 (3) V-shaped</p> |
|---|---|

**3. T-shaped epiphyseal (13-C1.3)**


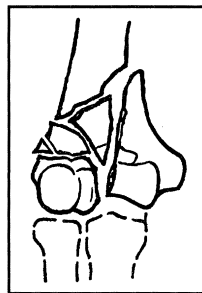
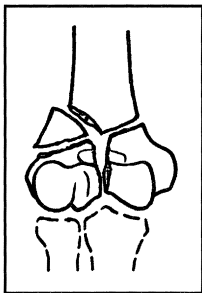
**C1**



Humerus, distal, complete articular simple metaphyseal multifragmentary (13-C2)

- |  |  |                                    |
|--|--|------------------------------------|
| <p><b>1. With intact wedge (13-C2.1)</b><br/>                 (1) metaphyseal lateral<br/>                 (2) metaphyseal medial<br/>                 (3) metaphysio-diaphyseal-lateral<br/>                 (4) metaphysio-diaphyseal-medial</p> | <p><b>2. With a fragmented wedge (13-C2.2)</b><br/>                 (1) metaphyseal lateral<br/>                 (2) metaphyseal medial<br/>                 (3) metaphysio-diaphyseal-lateral<br/>                 (4) metaphysio-diaphyseal-medial</p> | <p><b>3. Complex (13-C2.3)</b></p> |
|--|--|------------------------------------|

**C2**



Humerus, distal, complete multifragmentary (13-C3)

- |   |  |   |
|---|--|---|
| <p><b>1. Metaphyseal simple (13-C3.1)</b></p> | <p><b>2. Metaphyseal wedge (13-C3.2)</b><br/>                 (1) intact<br/>                 (2) fragmented</p> | <p><b>3. Metaphyseal complex (13-C3.3)</b><br/>                 (1) localized<br/>                 (2) extending into diaphysis</p> |
|---|--|---|

**C3**

