

## OTA Tip of the Month – April 2012

### Method for Optimizing Imaging During Repair of Proximal Humeral Fractures

Stephen A Kottmeier, MD, University Hospital Health Sciences Center, Stony Brook, NY

#### **Title: Use a Retrograde Guidewire to Direct an Antegrade Femoral IM Nail**

Placing an antegrade nail centrally in the distal femoral epiphysis is often a valuable way to avoid angular deformity (varus/valgus or flexion/extension) when reducing and fixing a femoral fracture located at or below the femoral isthmus. This can be done by holding the fracture correctly reduced in both planes, or by guiding the nail to the correct location with blocking (“poller”) screws.

Another alternative is to insert a retrograde guidewire, using the standard retrograde nail entry site, via the femoral intercondylar notch, in the midline on the AP radiograph, and at the anterior end of Blumensaat’s line on the lateral.(Fig.1A,B) The guidewire, with a diameter that will enter the tip of the nail, is advanced to the nail once it has past the fracture. Withdraw the antegrade guidewire, and insert the distal one into the nail tip, far enough to be secure. (Fig. 2A,B) Then drive the nail distally into its desired central position, over the retrograde wire. (Fig.3A,B) The nail should be placed well into the denser bone of the distal femur. Locking screws add stability, and at least one can be placed before the wire is completely withdrawn.

While this technique avoids placement of blocking screws for reduction, it permits their use if additional mechanical support is desired

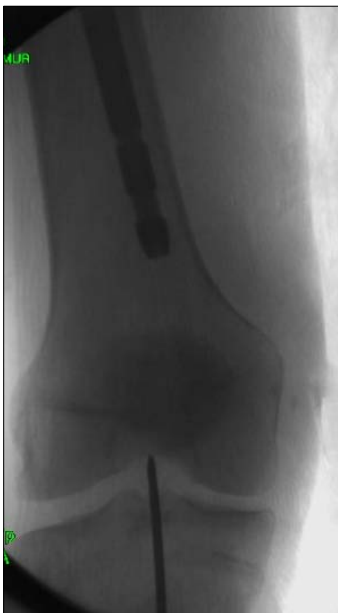

Fig. 1A

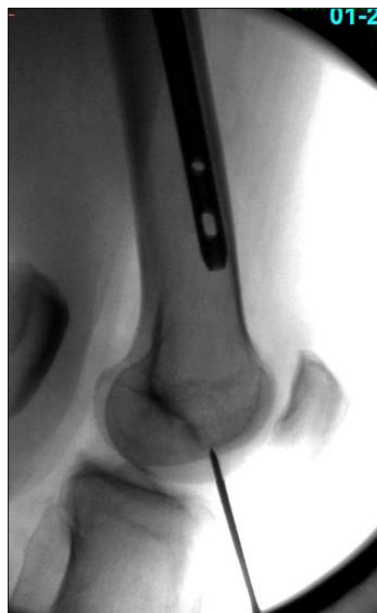

Fig. 1B

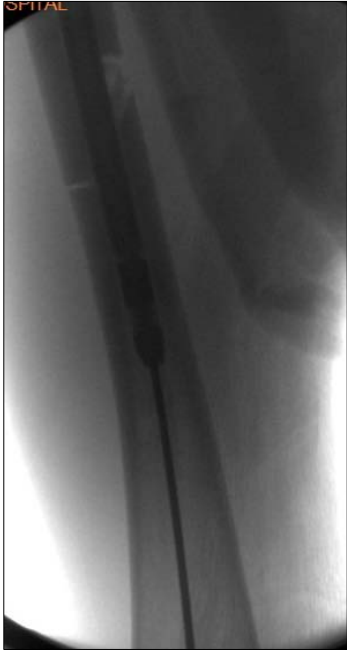

Fig. 2A

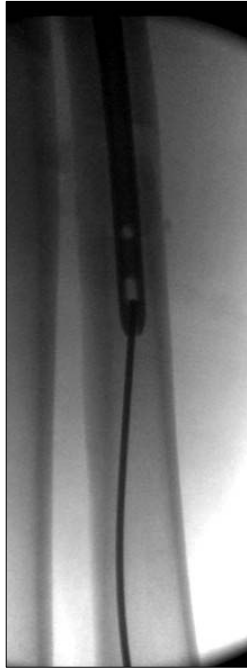


Fig. 2B

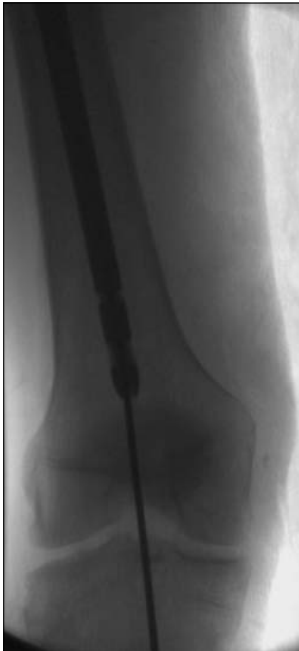

Fig. 3A

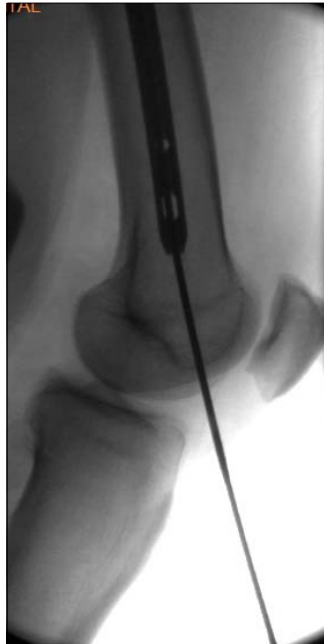

Fig. 3B