

TIBIAL PLATEAU FRACTURE FIXATION IN THE PRONE POSITION (APPLICATIONS)

adapted from Kottmeier S A et al SURGICAL EXPOSURE TRENDS AND CONTROVERSIES IN EXTREMITY FRACTURE CARE

© 2016 AAOS Instructional Course Lectures, Volume 65

STEPHEN A. KOTTMEIER M.D. – State University of NY @ Stony Brook NY

MEDIAL MONOCONDYLAR FRACTURES

Isolated posteromedial split fractures of the tibial plateau (Moore type I) represent a fracture dislocation with concerning osseous and soft tissue injury . These patterns can be mistakenly interpreted as a lateral tibial plateau fracture. Careful scrutiny of imaging studies ,particularly the CAT scan ,will identify an intact cortical column laterally . An obliquely or coronally oriented isolated fragment involving of the posteromedial condyle of significant dimension is demonstrated . These lesions are frequently associated with central articular depression potentially encroaching within the lateral condyle.The pursuit of a lateral approach with only of primarily lateral fixation will likely result in inadequate reduction and undesirable and insufficient fixation .

These fracture patterns are preferentially managed employing a posteromedial(Lobenhoffer) approach with the patient positioned prone . The involved extremity is elevated on bolsters to facilitate imaging .Both patient and the table are rotated to enhance accurate lateral imaging. The surgeon is positioned on the opposite side of the radiolucent table. Either a linear or curvilinear (within or just superior to the retro-popliteal crease) incision is established with well-developed skin flaps . Elevation of the medial margin of the medial gastrocnemius is begun within the midportion of the wound extending proximally to its origin. The pes tendons and their attachments may be maintained or divided as required. The popliteal vessels are neither formally encountered or mobilized. The popliteus is next mobilized with subperiosteal elevation along its medial margin extending laterally. Retractors are positioned on the lateral tibial osseous margin with gentle retraction to limit potential for venous thrombus and neurovascular injury. The posterior medial fracture is mobilized to allow extraction of interposed hematoma soft tissue and osteochondral debris. This is facilitated by placing the knee in a position of flexion. The inferior apex of the retro-condylar medial fracture serves as an indirect reduction aid and mean towards effective fixation employing anti-glide techniques . Positioning the knee in extension facilitates reduction. On occasion fracture patterns may extend laterally within the subchondral region of the lateral femoral condyle. This occurs in the absence of any lateral cortical compromise. Accurate reduction may require extraction or reduction of these lateral osteochondral components employing a more extensile version of this approach. In such circumstances the medial gastrocnemius tendon proximally is sectioned to enhance exposure , reduction and subsequent fixation . This should be performed inferior to its origin to limit compromise to its arterial supply. Fixation constructs may be extended laterally with this approach to allow for reduction and fixation of the lateral extensions of these primarily medial fractures . The gastrocnemius origin is subsequently repaired and tissues closed in layers. Some authors have encouraged immobilization in a position of flexion to limit wound healing concerns. This however has been associated with some sustained extension deficits.

BICONDYLAR FRACTURES

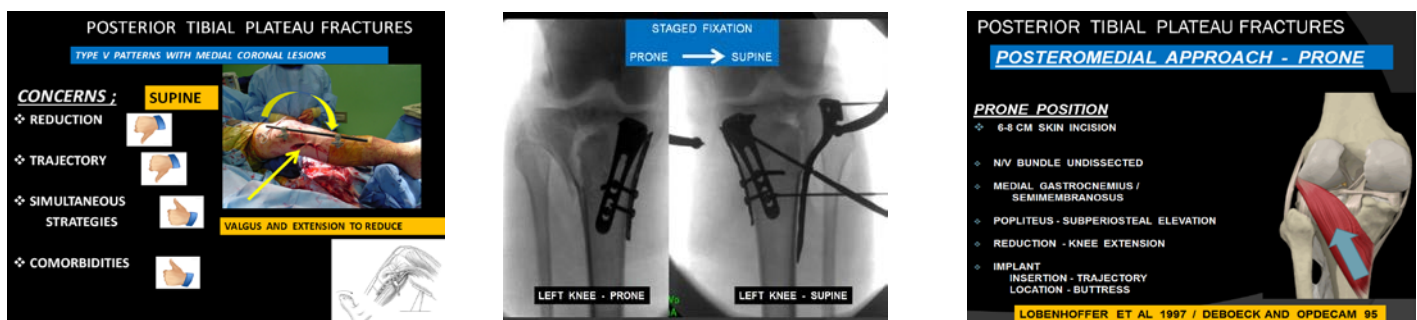
Increasingly appreciated is the frequent presence of a coronally oriented posterior medial fractures in bicondylar patterns These fragments have been described in 60-75% of OTA type C fractures They typically encompass as much as 25% of the entirety of the knee joint surface. If unrecognized or inadequately reduced and fixated articular incongruity and limb malalignment may result with compromised clinical outcomes Contemporarily designed laterally applied locking plates may not afford sufficient fixation or engage these posteromedial variants This is both implant and operator insertion dependent. Both plate design and location of application may influence posterior medial fragment capture. To effect an adequate and preserved reduction the surgeon may elect dual plate fixation employing

anterolateral and posteromedial approaches This is commonly performed with simultaneous surgical access strategies in the supine position. Weil and colleagues described the importance of proper patient and limb positioning. Adequate reduction and fixation of the posterior medial fragment in the supine position however may be complicated by required knee extension for reduction as well as the limited aperture of the wound and conflicts with screw and drill trajectory Typically , execution of medial condyle reduction is performed first as this is often less comminuted and serves as a subsequent foundation on which to build the lateral articular and lateral columnar components. While in the supine position the knee tends to drift into varus complicating both reduction and maintenance of reduction during the course of fixation. Valgus and extension is commonly required to afford an effective reduction in the supine position. Although overcome with some effort , with increasing fracture complexity this becomes increasingly problematic. Patient's with systemic comorbidities may require dual plate reduction in the supine position .

Alternatively, the surgeon may elect to perform a staged strategy employing fixation of the medial column in the prone position to initiate the reconstructive effort This is then followed by repositioning of the patient and re-preparation of the limb in the supine position (same setting) Prone positioning and the previously described posterior medial (Loebenhoffer)approach afford excellent and efficient reduction maneuvers and ease of implant insertion (drill and screw trajectory). Introduced implants must not compete with fixation of the lateral condyle performed subsequently in the supine position. In addition to the inconveniences of patient and limb re-preparation this strategy does not allow for simultaneous reduction of the medial and lateral condylar components. It further mandates accurate and anatomic reduction of the medial condyle prior to subsequent staged fixation of the lateral condyle. Luo et al described patient preparation and positioning permitting simultaneous anterior and posterior access in a "floating" position .This may invite both the attributes and liabilities of supine (simultaneous) and prone (followed by supine) staged strategies.

Watson and colleagues described a staged treatment for complex 3 column tibial plateau fracture dislocations .They described a displaced vertical shear fracture of the posterior column in conjunction with lateral and medial column fractures. These typically had significant posterior column compromise with resultant knee subluxation. The authors concluded such complex 3 column injuries to be rare and uniquely distinguished from more common posterior medial condylar components found in bicondylar injuries . They further cautioned that unfamiliarity with and accordingly absence of recognition of these patterns would likely yield an ineffective treatment strategy.

Prompt recognition and stabilization of the posterior column component (prone position) was encouraged to initially restore limb length, alignment, stability and resolve subluxation .This was performed in combination with a transarticular external fixator to allow the soft tissues to recover. Definitive fixation of the remaining components was performed in delayed fashion. During the interim a postoperative CAT scan was pursued to better strategize fixation and access to the lateral and medial columns.



Fakler JK, Ryzewicz M, Hartshorn C, Morgan SJ, Stahel PF, Smith WR. Optimizing the management of Moore type I postero-medial split fracture dislocations of the tibial head: description of the Lobenhoffer approach. J Orthop Trauma. 2007 May;21(5):330-6.

Lobenhoffer P, Gerich T, Bertram T, et al. Particular posteromedial and posterolateral approaches for the treatment of tibial head fractures (German). Unfallchirurgie. 1997;100:957-967.

