

**Anatomic Reduction of Acetabular Fracture: When Is the Best Time to Operate?**

Steven Dailey, MD<sup>1</sup>; Michael Archdeacon, MD<sup>1</sup>; Caleb Phillips, PhD<sup>2</sup>; Joseph Radley, MD<sup>3</sup>;

<sup>1</sup>UC Department of Orthopaedics Cincinnati, Ohio, USA;

<sup>2</sup>University of Colorado – Boulder, Boulder, Colorado, USA;

<sup>3</sup>St. Louis University, Department of Orthopaedics, St. Louis, Missouri, USA

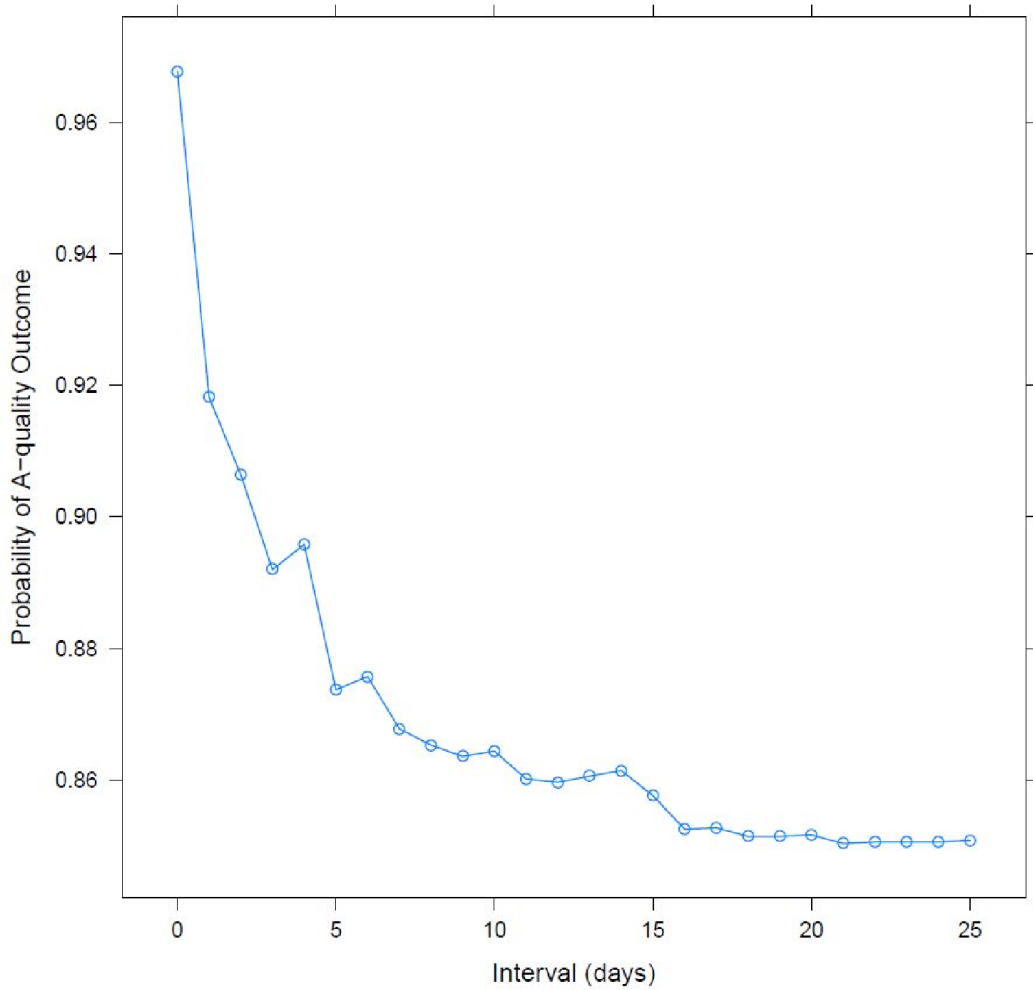
**Purpose:** Quality of reduction following surgical intervention for displaced acetabular fractures directly correlates with functional outcomes. Matta reported an increased rate of anatomic acetabular reduction when surgical fixation was performed within 2 weeks from injury ( $P = 0.06$ ). The purpose of this study was to further stratify the timing of surgical intervention as it relates to the quality of reduction for acetabular fractures. We hypothesize that earlier intervention improves the probability of achieving an anatomic reduction.

**Methods:** This is an IRB-approved evaluation of a prospectively collected acetabular fracture database from a single surgeon at a Level I trauma center. Reduction quality of all acetabular fractures treated via open reduction and internal fixation (ORIF) between September 2001 and February 2014 was assessed using three standard postoperative radiographs (AP and two 45° oblique Judets) as well as intraoperative fluoroscopy. Displacement of >1 mm was considered an anatomic reduction (A), 2-3 mm imperfect (I), and >3 mm poor (P). A total of 729 fractures were available for analysis. 79 of these fractures underwent percutaneous fixation in situ and were excluded, leaving a cohort of 650 fractures. The primary outcome measurement was quality of reduction as it relates to the interval from injury to ORIF (OR interval). Secondary outcome measurements included demographic and injury characteristics. The correlation between OR interval and quality of reduction was evaluated using a pairwise Wilcoxon rank-sum test and logistic regression analysis.

**Results:** There were no statistically significant differences between anatomic reductions (A) and nonanatomic reductions (I, P) in regards to gender, body mass index, mechanism of injury, use of skeletal traction, marginal impaction, wall comminution, or femoral head injury ( $P > 0.05$ ). Nonanatomic reduction was related to increased age, increased ISS, fracture pattern, surgical approach, the absence of a hip dislocation, and increased OR interval ( $P < 0.05$ ). A reductions were observed in 85% ( $n = 553$ ) of cases, I reductions in 11% ( $n = 74$ ) of cases, and P reductions in 4% ( $n = 23$ ) of cases. Patients with A reductions had significantly shorter OR intervals (median, 3 days) when compared to either I (median, 4.5 days;  $P = 0.02$ ) or P reductions (median, 7 days;  $P < 0.001$ ) reductions. The OR interval of I reductions was also significantly shorter than that of P reductions ( $P = 0.02$ ). Logistic regression analysis demonstrated that OR interval had an effect of -0.12, meaning that the log odds of anatomic reduction decreases by 0.12 with each day from injury to ORIF.

**Conclusion:** The interval from injury to operative fixation of acetabular fractures affects quality of reduction. Earlier intervention improves the probability of achieving an anatomic reduction. Acetabular fixation should be performed within 5 days of injury when possible.

## Probability of A-quality Outcome with Time



The FDA has stated that it is the responsibility of the physician to determine the FDA clearance status of each drug or medical device he or she wishes to use in clinical practice.

## The Effect of 3-Dimension Printing Modeling for Treating Complex Acetabular Fractures: A Randomized Prospective Study

Hu Wang, MD; Kun Zhang, MD; Yan Zhuang;  
Pelvis and Acetabular, CANADA

**Background/Purpose:** Treating complex acetabular fractures presents a risk of malreduction due to difficulty in conceptualizing the fracture orientation and recreating the normal anatomy. There is also a risk of inadvertent penetration of the joint by the screws used during instrumentation. Inadequate preoperative planning can increase the times and blood loss during the operation. Fracture modeling using 3-dimension printing can precisely replicate the 3-dimensional osseous structures. This is not only helpful in understanding the fracture configuration, but also preoperative templating and contouring of the plates and planning various screw trajectories. Using the 3-dimension printing modeling for preoperative planning and surgery simulation, our goal was to evaluate the effect of 3-dimension printing modeling for treating complex acetabular fractures through a randomized prospective study, especially focus on operating time, blood loss, reduction, and position of internal fixator.

**Methods:** This study tests the hypothesis that use of 3-dimension printing can significantly improve technical ability on complex acetabular fractures. Fifty cases with complex acetabular fractures were randomly and equal divided into two groups, with group 1 using conventional radiographs and 3-dimensional CT for preoperative planning, and group 2 using conventional radiographs, 3-dimensional CT, and 3-dimension printing modeling for preoperative planning and simulation surgery by the surgeon and the first assistant-recording operative time, blood loss, reduction, internal fixation position, and satisfaction of the surgeon by an investigator who did not attend the process from preoperative planning to the end of operating. The accuracy of reduction was evaluated with postoperative CT scans.

**Results:** All operations were completed by the same senior surgeon and assistant. Time of operation: Statistically significant difference was determined between group 1 and group 2, respectively:  $202 \pm 50$  minutes,  $179 \pm 62$  minutes. Blood loss: Statistically significant difference was determined between group 1 and group 2, respectively:  $600 \pm 200$  mL,  $450 \pm 150$  mL. According to the Matta classification radiographic grades were excellent in 12, good in 8, poor in 5 in group 1 and excellent in 16, good in 6, poor in 3 in group 2; in group 1 there was one case with screw into joint and two cases with one screw out of bone, five cases with screw that was short. In group 2, two cases with screw short. Satisfaction of the surgeon: Statistically significant difference was determined between group 1 and group 2, respectively: 19 (76%) cases, 23 (92%) cases.

**Conclusion:** 3-dimension printing technology promises to be extremely versatile and can be used in preoperative planning and surgery simulation. It is beneficial for reducing operating time and blood loss, and also helps to reduce the fracture and insert the screws as the surgeon desired.

## Does Injury Mechanism Influence Eventual Conversion to THA After Acetabular Fractures in Geriatric Patients?

Aaron Johnson, MD<sup>1</sup>; Robert O'Toole, MD<sup>2</sup>; Patrick Greenwell, BS<sup>2</sup>; Theodore Manson, MD<sup>3</sup>;

<sup>1</sup>Glen Burnie, Maryland, USA;

<sup>2</sup>University of Maryland Shock Trauma, Baltimore, Maryland, USA;

<sup>3</sup>R Adams Cowley Shock Trauma Center, Baltimore, Maryland, USA

**Background/Purpose:** Geriatric acetabular fractures are increasing in prevalence in the US. Controversy exists regarding the optimal treatment of these injuries. Although open reduction and internal fixation (ORIF) is the preferred treatment for young patients, some advocate treatment with total hip arthroplasty (THA). Many surgeons believe that acetabular fractures sustained through a low-energy mechanism are more likely to fail after ORIF. Our hypothesis was that geriatric acetabular fractures sustained after low-energy falls are more likely to progress to THA than those sustained after high-energy mechanisms.

**Methods:** Between 2000 and 2008 all records from a single trauma center were reviewed for patients who were greater than 60 years old and who underwent operative treatment for acetabular fractures. During this time period all fractures were treated with ORIF and no patients received acute arthroplasty. There were 115 fractures in 115 patients. 64 patients sustained their injury from a high-energy mechanism, and 51 patients had low-energy mechanisms. High-energy mechanisms were defined as motor vehicle collisions, falls from height (greater than three steps), and bicycle or motorcycle accidents. All patients had a minimum of 2 years follow-up. Mean follow-up was 61 months (range, 24-97 months). Our primary outcome measure was aseptic failure, defined as conversion to THA after initial ORIF. Mean age at time of injury was 70 years (range, 60-91) in the high-energy cohort, and 69 years (range, 60-94) in the low-energy cohort. Fisher exact test was used for the analysis.

**Results:** There was a statistically significant increased rate of conversion to THA in the high-energy cohort (20%, 16/51) versus the low-energy cohort (5%, 3/51,  $P = 0.03$ ). The mean time to THA was 32 months (range, 5-67 months). There was one surgical site infection in the high-energy cohort, and no infections in the low-energy cohort (1.6% vs 0.0%,  $P = 1.0$ ).

**Conclusion:** In contrast to our hypothesis, we found that geriatric patients who sustain acetabular fractures from high-energy mechanisms may be more likely to fail after ORIF and require THA than those who sustained injury from low-energy falls. This contradicts the existing dogma that patients who sustain acetabular fracture from low-energy mechanisms, and presumably are therefore more debilitated and perhaps have worse quality bone than those who sustain high-energy injuries, will have an unacceptable failure rate with attempts at ORIF. Clinicians should be aware that low-energy mechanism alone does not appear to be an obvious contraindication to ORIF of geriatric acetabular fracture.

## Long-Term Hip Joint Survival and Clinical Results in Conservatively Treated Acetabular Fractures

John Clarke-Jenssen, MD<sup>1</sup>; Anette Wikerøy, MD<sup>2</sup>; Ingrid Eitzen, PhD<sup>1</sup>;

Jan Erik Madsen, MD, PhD, Professor<sup>1</sup>;

<sup>1</sup>Department of Orthopaedics, Oslo University Hospital, NORWAY;

<sup>2</sup>Akershus University Hospital, NORWAY

**Background/Purpose:** Nonoperative treatment of acetabular fractures is indicated in patients with no or minor fracture displacement. There are few studies describing the long-term results for patients treated conservatively according to modern principles. The purpose of the present work was to investigate the long-term survival of the native hip joint and the clinical results following a conservatively treated acetabular fracture.

**Methods:** Since 1994 all acetabular fractures treated at our department have been prospectively registered. In this study we included all patients treated nonoperatively from 1994 to June 2004; 236 patients were identified. For the survival analysis, all patients who were not diseased or expatriated within the first year after injury were included. 186 patients with 187 fractures were available for analysis. The average follow-up was 9 years (range, 1-20). The average patient age was 49 years (range, 12-92), and men constituted 78% of the study population. Data were analyzed for survival of the native acetabulum with Kaplan-Meier and log-rank test to identify differences in survivorship between groups. 104 patients with surviving hip joints had an average clinical follow-up of 12 years (range, 9-20), with Harris hip score (HHS) and Merle D'Aubigné score.

**Results:** Twelve patients received a total hip arthroplasty during the follow-up period, on average 6.9 years (range, 1.4-15.9) after injury. Thus, the average 10-year hip joint survival was 94% (95% confidence interval [CI] 89%-97%) and 20-year survival was 85% (95% CI 66%-94%). The surviving hip joints had an average HHS of 93 (range, 28-100) and Merle D'Aubigné score of 16.6 (range, 8-18). The most significant negative predictor for survival and clinical outcome was an intra-articular step >2 mm, as measured in the obturator oblique radiographic projection. The presence or absence of fracture lines in the upper 10 mm of the weight-bearing dome on CT scans did not predict differences in survival or clinical scores. When the data was stratified in roof arc more or less than 45°, there was a significant decrease in survival for the posterior roof arc (P = 0.05) as measured on the obturator oblique radiographs. The Letournel fracture classification did not predict hip joint survival or clinical outcome. There was no difference in survival, HHS, or Merle D'Aubigné score between genders or in age over or under 60 years.

**Conclusion:** For acetabular fractures with minimal dislocation the long-term survival and clinical outcome is excellent. Intra-articular step and roof arc <45° as measured on plain radiographs and in the obturator oblique projection in particular is the most significant predictor of survival. Conventional radiographs with oblique projections (Judet views) are a valuable tool when deciding treatment strategy for acetabular fractures, especially when nonoperative treatment is considered.

### Δ **Surgery for Unilateral Sacral Fractures: Are the Indications Clear?**

**Paul Tornetta, MD<sup>1</sup>**; Julie Agel, ATC<sup>2</sup>; Sean Nork, MD<sup>2</sup>; Clifford Jones, MD, FACS<sup>3</sup>; Heather Vallier, MD<sup>4</sup>; Brian Mullis, MD<sup>5</sup>; Zachary Roberts, MD<sup>6</sup>; James Goulet, MD<sup>7</sup>; Anna Miller, MD, FACS<sup>8</sup>; Andrew Schmidt, MD<sup>9</sup>;

<sup>1</sup>Boston Medical Center, Boston, Massachusetts, USA;

<sup>2</sup>Harborview Medical Center, Seattle, Washington, USA;

<sup>3</sup>Orthopaedic Associates of Michigan, Grand Rapids, Michigan, USA;

<sup>4</sup>Metrohealth Medical Center, Cleveland, Ohio, USA;

<sup>5</sup>Eskenazi Health, Indianapolis, Indiana, USA;

<sup>6</sup>University of Oklahoma Medical Center, Oklahoma City, Oklahoma, USA;

<sup>7</sup>University of Michigan, Ann Arbor, Michigan, USA;

<sup>8</sup>Wake Forest Baptist Hospital, Winston-Salem, North Carolina, USA;

<sup>9</sup>Hennepin Medical Center, Minneapolis, Minnesota, USA

**Background/Purpose:** Sacral fractures comprise approximately 75% of pelvic fractures. The most common type is a unilateral sacral injury with anterior impaction of the sacrum. Some prospective data have identified that these injuries do not displace over time and can be managed nonoperatively. Other surgeons believe that displacement may occur without stabilization, and are more aggressive in their approach. Additionally, sacral fractures may be complete and present with displacement. We designed a multicenter prospective trial to evaluate unilateral sacral fractures that is funded by the OTA. The purpose of this report is to compare the demographic, fracture, and displacement characteristics of the first 250 patients in this trial to determine what differences exist between the groups treated operatively versus nonoperatively.

**Methods:** Over a 7-year period we offered enrollment to all patients with unilateral sacral fractures in 16 centers. Exclusion criteria were: APC (anterior-posterior compression) injuries as demonstrated by symphyseal dislocation, pregnant patients or prisoners, and those who would not be able to follow up. All fractures were evaluated for location by zone and displacement (in mm) on the standard three views of the pelvis and CT scan. Displacement was measured at the level of the sacrum on all radiographs and CT. Vertical displacement was measured on the AP radiograph and "posterior" displacement on the inlet view. Additionally, the status of the anterior and posterior cortices of the sacrum were graded as impacted/nondisplaced, or displaced. Angulation of the affected hemipelvis as compared with the unaffected side was measured on the CT and inlet views. Injuries were also classified as having unilateral or bilateral rami fractures.

**Results:** All data are reported as percentages for the cells available so that not all results represent all cases. We enrolled 250 patients with an average age of 39 years and an average ISS of 13.9 of which 61% were female. The average BMI (body mass index) was 25.8. The most common mechanisms of injury were motor vehicle accident (50%) followed by fall from a height (23%). 60% had zone-1 sacral fractures. 26% had bilateral and 74% had unilateral rami fractures. The majority (62% AP, 63% inlet, 66% CT) of the patients had no displacement (0 mm). The anterior and posterior cortices of the sacrum were impacted or nondisplaced in 91% and 77% of cases, respectively. 171 patients were treated nonopera-

Δ OTA Grant

The FDA has stated that it is the responsibility of the physician to determine the FDA clearance status of each drug or medical device he or she wishes to use in clinical practice.

tively and 79 operatively. There were no differences in age, gender, BMI, ISS, or mechanism of injury between the groups. The presence of bilateral versus unilateral rami, or having a displaced versus impacted anterior cortex did not correlate with surgery. Displacement on the inlet view and rotational displacements were also not different between the groups. Table #1 details the differences that were found between the operative and nonoperative groups. The major factors were having a zone 2 rather than a zone-1 injury, having posterior cortical displacement, and greater displacement on the AP radiograph and CT. However, the average displacement of those having surgery was only 2.5 mm and 2.9 mm as measured on the CT and AP radiograph. Finally, 45% of those treated surgically had zero displacement, and 72% had <5 mm of displacement.

**Conclusion:** We sought to evaluate the indications for operative management of unilateral sacral fractures by comparing the patient demographics and fracture location, pattern, and displacements (translational and rotational) of a prospective cohort of patients treated in 16 trauma centers. The only factors that correlated with the choice for surgery were zone 2 injury versus zone 1 and posterior cortical displacement on the CT. Most patients who were treated operatively had <5 mm of displacement of the sacrum. A large number of like patients are being treated operatively and nonoperatively by different surgeons that may lend itself to a randomized controlled trial.

### Surgery for Unilateral Sacral Fractures: Are the Indications Clear?

**Table #1:** Differences in patients treated operatively vs nonoperatively

	<b>Zone 1 vs 2</b>	<b>Posterior cortex Displaced No vs Yes</b>	<b>Displacement AP X-ray (mm)</b>	<b>Displacement CT (mm)</b>
<b>Operative</b>	<b>24 vs 37</b>	<b>46 vs. 19</b>	<b>2.9 ± 4.2</b>	<b>2.5 ± 4.0</b>
<b>Nonoperative</b>	<b>92 vs 36</b>	<b>114 vs. 8</b>	<b>0.8 ± 2.2</b>	<b>0.8 ± 2.7</b>
<b>P value</b>	<b>&lt; 0.0001</b>	<b>0.0001</b>	<b>&lt;0.0001</b>	<b>0.011</b>

## Posterior Fixation in APC-2 Pelvic Ring Injuries Decreases the Rates of Anterior Plate Failure and Malunion

*Frank Avilucea, MD; Paul Whiting, MD; Hassan Mir, MD, MBA;  
Vanderbilt University Medical Center, Nashville, Tennessee, USA*

**Purpose:** Biomechanical studies report that augmenting anterior pelvic ring fixation with posterior fixation significantly increases stability. While clinical studies assess radiographic outcomes following plate fixation of the anterior pelvis, no studies have purely compared the radiographic and clinical outcomes of a partially disrupted hemipelvis (intact posterior sacroiliac ligaments) treated with either anterior plate fixation alone versus anterior fixation with percutaneous posterior iliosacral screw fixation. Our aim was to determine whether anterior fixation alone is adequate to control sagittal and coronal plane rotation and prevent malunion in pelvic ring injuries with anterior sacroiliac widening.

**Methods:** A retrospective review of all skeletally mature patients with a traumatic pelvic disruption treated from 2004 to 2014 with anterior symphyseal plating with or without a posterior iliosacral screw was completed. Inclusion criteria included type-2 anteroposterior compression (APC-2) pelvic ring injury with CT evidence of symphyseal disruption and isolated anterior widening of one sacroiliac joint. Patients with fractures of the acetabulum, pubic rami, or sacrum were excluded, as were those with bilateral injuries. Patients were then divided into two groups: those that only underwent plating of the symphysis with a 3.5-mm 6-hole plate versus those that also had placement of a percutaneous partially threaded 7.0-mm or 7.3-mm iliosacral screw. Patients were followed for a minimum of 6 months or to failure of fixation. Examined data points included age, anterior symphyseal diastasis as measured on CT, duration of follow-up, time to fixation failure (failure defined as any change in anterior fixation visible on follow-up radiographs), type of fixation failure, and presence of malunion. Malunion was defined as >5 mm of either rotational or translational displacement of the hemipelvis and pubic symphysis in a nonanatomic position. Statistical analysis was completed using Pearson uncorrected chi-square test.  $P < 0.05$  was considered statistically significant.

**Results:** Complete documentation (chart and radiographic) was available on 140 patients. 96 patients underwent combined anterior and posterior fixation, and 44 patients had anterior plate fixation alone. Average age and length of follow-up was 38 years and 7.2 months, respectively. Anterior plate fixation failure occurred in 5 patients (7.3%) in the combined fixation group and in 17 patients (38.6%) in the anterior-only group ( $P < 0.0001$ ). Malunion was identified in one patient (1.0%) in the combined treatment group and in 15 patients (34.1%) in the anterior-only cohort ( $P < 0.0001$ ).

**Conclusion:** APC-2 pelvic ring injuries treated with anterior plating and supplemental posterior screw fixation have significantly less anterior hardware failure and malunion than those treated with anterior plating alone.



## **A Prospective Trial Comparing Magnetic Resonance Imaging-Detected Pelvic Ligament Injury to Displacement on Pelvic Stress Examination Under Anesthesia**

**Brendan O'Daly, MD FRCS(Tr&Orth)<sup>1</sup>; Lina Chen, MD<sup>2</sup>; Derik Davis, MD<sup>2</sup>;**

**Joshua Gary, MD<sup>3</sup>; Christopher Lebrun, MD<sup>1</sup>; Christina Boulton, MD<sup>1</sup>; Theodore Manson, MD<sup>1</sup>;**

**Jason Nascone, MD<sup>4</sup>; Marcus Sciadini, MD<sup>5</sup>; Michael Mulligan, MD<sup>2</sup>; Robert O'Toole, MD<sup>4</sup>;**

<sup>1</sup>RA Cowley Shock Trauma Center, University of Maryland School of Medicine, Baltimore, Maryland, USA;

<sup>2</sup>Department of Radiology, University of Maryland School of Medicine, Baltimore, Maryland, USA;

<sup>3</sup>University of Texas-Houston, Department of Orthopaedic Surgery, Houston, Texas, USA;

<sup>4</sup>Shock Trauma Orthopaedics, Baltimore, Maryland, USA;

<sup>5</sup>Department of Orthopaedics, RA Cowley Shock Trauma Center, University of Maryland School of Medicine, Baltimore, Maryland, USA

**Purpose:** Recently both pelvic stress examination under anesthesia (EUA) as well as pelvic magnetic resonance imaging (MRI) have been reported as means to potentially evaluate pelvic ring fracture stability. However, the relation of findings on these two tests to each other is unknown. We hypothesized that MRI-detected pelvic ligament injury pattern would correlate with findings on pelvic stress EUA.

**Methods:** Twenty patients with acute pelvic ring injury (OTA 6.1-A2, 6.1-A3, 6.1-B or 6.1-C) were enrolled in a prospective trial from 2013-2014. All patients underwent the study intervention of pelvic stress EUA and MRI within 14 days of injury, and were included in the analysis. IRB approval was obtained and informed consent obtained. EUA was performed according to the method of Sagi et al, with the use of a calibrated radio-opaque marking ball. Fifteen standardized fluoroscopic views were obtained and analyzed at each EUA. Maximum horizontal, vertical, and combined vector displacement was measured on each view. MRI scans were graded for ligament and pelvic floor musculature injury by three independent musculoskeletal radiology attending physicians. Ligament injury was scored as either complete tear, partial tear, or intact. Radiologists were blinded to the side of injury. For the cases when radiologists did not agree on MRI findings, an MSK (musculoskeletal) consensus committee reviewed the MRI, with the decision of the senior MSK radiologist final. Ligament injury on MRI was correlated with various measures of displacement on pelvic EUA using Pearson correlation coefficient (two-tailed,  $P < 0.05$ ). Interrater agreement was assessed using intraclass correlation coefficient (ICC). IBM SPSS Statistics v.20.0 was used for statistical analysis.

**Results:** We found no significant correlation between MRI-detected ligament injury and either horizontal, vertical, or combined vector displacement on the 15 pelvic stress EUA images. We did, however, find that contralateral ligament and pelvic floor injury was observed in 75% of cases while only 30% of patients were thought to have bilateral injury by CT and radiographic classification alone. We found substantial interrater agreement between radiologists. The highest agreement was observed for anterior sacroiliac ligament injury (ICC = 0.9, confidence interval: 0.83-0.95,  $P < 0.0001$ ). External, internal, and vertical displacement on pelvic stress EUA ranged from 9 to 71 mm, 0 to 31 mm, and 5 to 79 mm, respectively, indicating the wide range of injuries in the study.

**Conclusion:** In this study, MRI-detected pelvic ligament injury pattern did not correlate with stress EUA displacement. Our finding of a high rate of contralateral ligament and pelvic floor injury suggests that a higher percentage of pelvic ring fractures may be associated with bilateral ligament injuries than previously thought. Our hope was that EUA could be used to predict the findings on MRI; however, our results appear to indicate that EUA is not a good predictor of which ligaments are injured in this patient population. The clinical role of both pelvic EUA and MRI awaits further research, but our data indicate that MRI and EUA appear to measure unique aspects of pelvic ring injuries.