

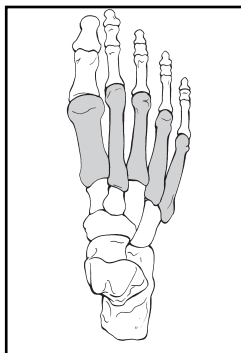
# METATARSALS

## BONE: METATARSALS (87)

Modifiers for metatarsals:

T, thumb toe (great) (1); I, index toe (2); L, long toe (3); R, ring toe (4); S, small toe (5).

## Location: Metatarsals (87)



### Types:

1. Metatarsal proximal and distal nonarticular and diaphysis non-comminuted (87-A)

2. Metatarsal proximal and distal partial articular diaphysis wedge comminution (87-B)

3. Metatarsal proximal and distal complete articular diaphysis comminuted (87-C)

### Groups:

1. Metatarsal, proximal extra-articular (87-A1)

2. Metatarsal, diaphysis noncomminuted (87-A2)

3. Metatarsal, distal extra-articular (87-A3)

1. Metatarsal, proximal partial articular (87-B1)

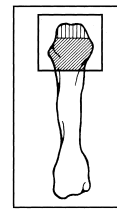
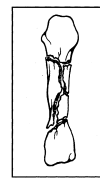
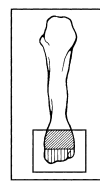
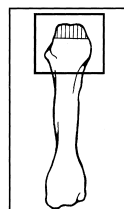
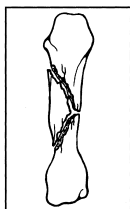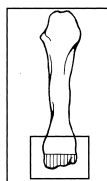
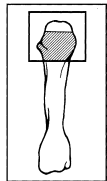
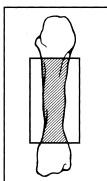
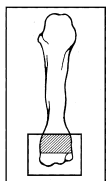
2. Metatarsal, diaphysis wedge (87-B2)

3. Metatarsal, distal partial articular (87-B3)

1. Metatarsal, proximal complete articular (87-C1)

2. Metatarsal, diaphysis comminuted (87-C2)

3. Metatarsal, distal complete articular (87-C3)



**Subgroups and Qualifications:**

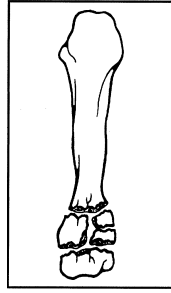
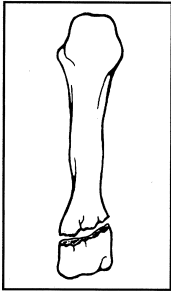
Metatarsal, proximal extra-articular (87-A1)

1. Noncomminuted (87-A1.1)

2. Comminuted (87-A1.2)

- (1) wedge
- (2) complex

**A1**



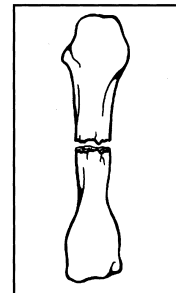
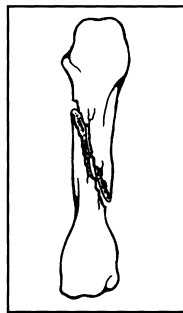
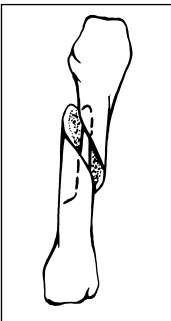
Metatarsal, diaphysis noncomminuted (87-A2)

1. Spiral (87-A2.1)

2. Oblique (87-A2.2)

3. Transverse (87-A2.3)

**A2**

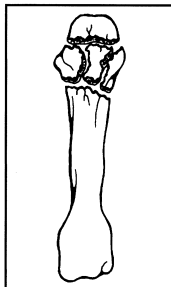
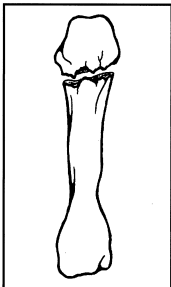


Metatarsal, distal extra-articular (87-A3)

1. Noncomminuted (87-A3.1)

2. Comminuted (87-A3.2)

**A3**

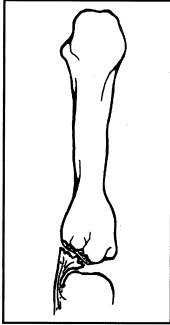

Metatarsal, proximal partial articular (87-B1)

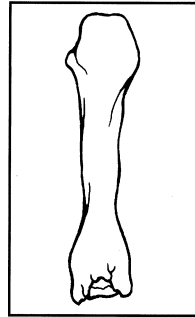
**1. Avulsion OR Split (87-B1.1)**

- (1) unicondyle medial
- (2) unicondyle lateral
- (3) coronal split volar fragment
- (4) coronal split dorsal fragment

**B1**

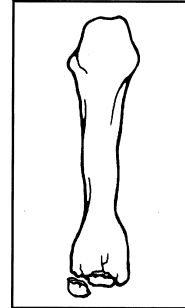


**2. Depression (87-B1.2)**



**3. Split/depression (87-B1.3)**

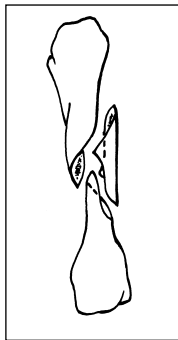
- (1) unicondyle medial
- (2) unicondyle lateral
- (3) coronal split volar fragment
- (4) coronal split dorsal fragment



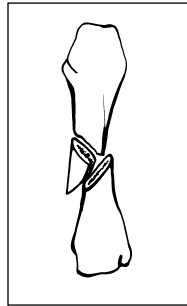
Metatarsal, diaphysis wedge (87-B2)

**1. Spiral (87-B2.1)**

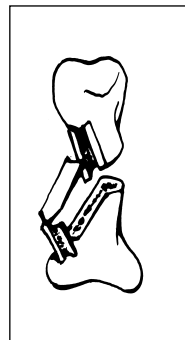
**B2**



**2. Bending (87-B2.2)**



**3. Comminuted wedge (87-B2.3)**

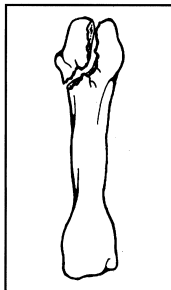


Metatarsal, distal partial articular (87-B3)

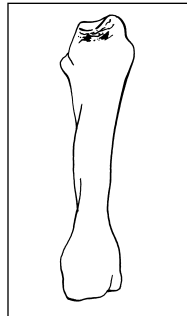
**1. Avulsion OR Split (87-B3.1)**

- (1) unicondyle medial
- (2) unicondyle lateral
- (3) coronal split volar fragment
- (4) coronal split dorsal fragment

**B3**

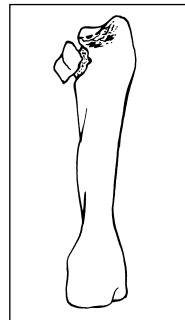


**2. Depression (87-B3.2)**



**3. Split/depression (87-B3.3)**

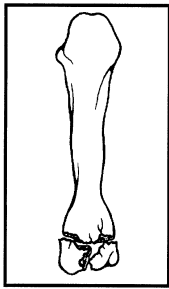
- (1) unicondyle medial
- (2) unicondyle lateral
- (3) coronal split volar fragment
- (4) coronal split dorsal fragment



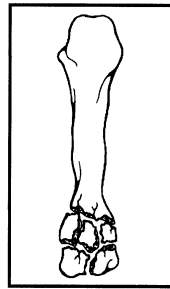
Metatarsal, proximal articular (87-C1)

1. Noncomminuted articular and metaphysis (87-C1.1)

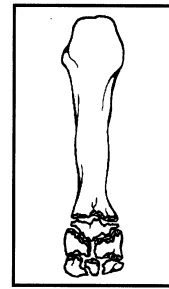**C1**



2. Noncomminuted articular, comminuted metaphysis (87-C1.2)



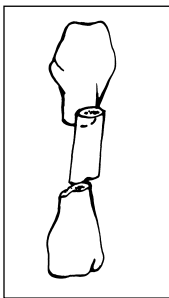
3. Comminuted articular (87-C1.3)



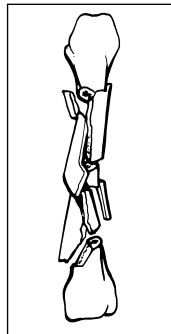
Metatarsal, diaphysis Comminuted (87-C2)

1. Segmental (87-C2.1)

**C2**



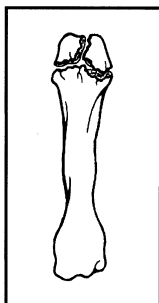
2. Complex comminuted (87-C2.2)



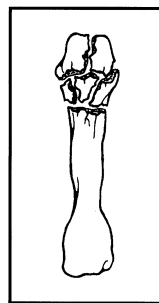
Metatarsal, distal articular (87-C3)

1. Simple articular/metaphysis (87-C3.1)

**C3**



2. Simple articular/comminuted metaphysis (87-C3.2)



3. Comminuted articular (87-C3.3)

