

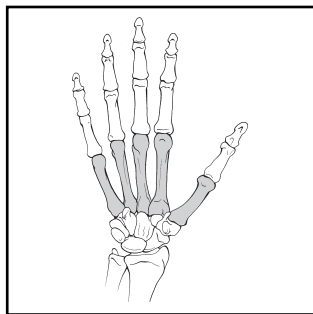
# METACARPALS

**BONE: METACARPALS (77)**

Modifiers for metacarpals:

T, thumb; I, index; M, middle; R, ring; L, little.

**Location: Metacarpals (77)**



**Types:**

**A. Metacarpal proximal and distal nonarticular and diaphysis non-comminuted (77-A)**

**B. Metacarpal proximal and distal partial articular diaphysis wedge comminution (77-B)**

**C. Metacarpal proximal and distal complete articular diaphysis comminuted (77-C)**

**Groups:**

1. Metacarpal, proximal extra-articular (77-A1)

2. Metacarpal, diaphysis non-comminuted (77-A2)

3. Metacarpal, distal extra-articular (77-A3)

1. Metacarpal, proximal partial articular (77-B1)

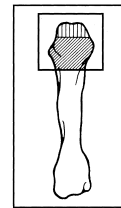
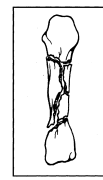
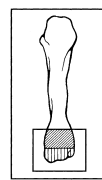
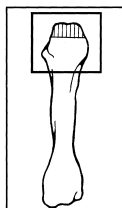
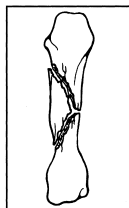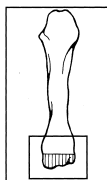
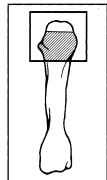
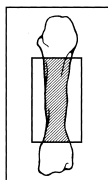
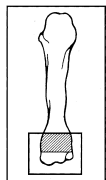
2. Metacarpal, diaphysis wedge (77-B2)

3. Metacarpal, distal partial articular (77-B3)

1. Metacarpal, proximal complete articular (77-C1)

2. Metacarpal, diaphysis comminuted (77-C2)

3. Metacarpal, distal complete articular (77-C3)



**Subgroups and Qualifications:**

Metacarpal, proximal extra-articular (77-A1)

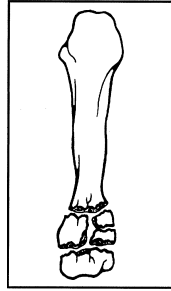
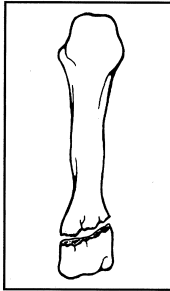
1. Noncomminuted (77-A1.1)

2. Comminuted (77-A1.2)

(1) wedge

(2) complex

**A1**



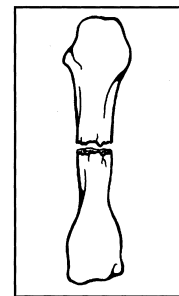
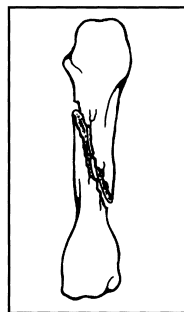
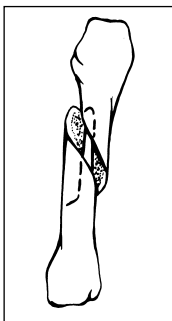
Metacarpal, diaphysis noncomminuted (77-A2)

1. Spiral (77-A2.1)

2. Oblique (77-A2.2)

3. Transverse (77-A2.3)

**A2**

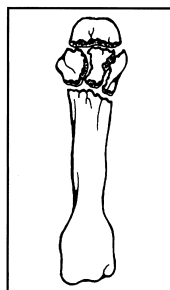
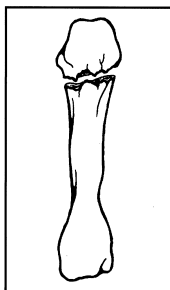


Metacarpal, distal extra-articular (77-A3)

1. Noncomminuted (77-A3.1)

2. Comminuted (77-A3.2)

**A3**

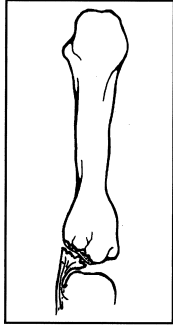


Metacarpal, proximal partial articular (77-B1)

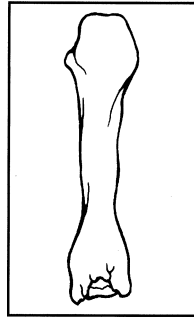
**1. Avulsion OR Split (77-B1.1)**

- (1) unicondyle medial
- (2) unicondyle lateral
- (3) coronal split volar fragment
- (4) coronal split dorsal fragment

**B1**

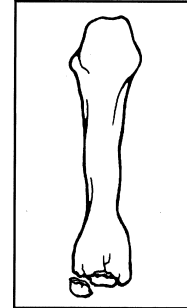


**2. Depression (77-B1.2)**



**3. Split/depression (77-B1.3)**

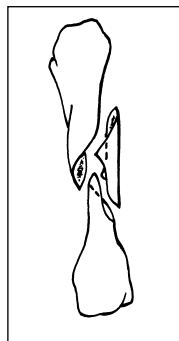
- (1) unicondyle medial
- (2) unicondyle lateral
- (3) coronal split volar fragment
- (4) coronal split dorsal fragment



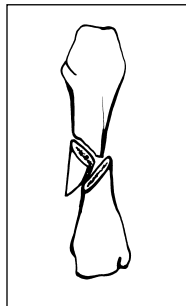
Metacarpal, diaphysis wedge (77-B2)

**1. Spiral (77-B2.1)**

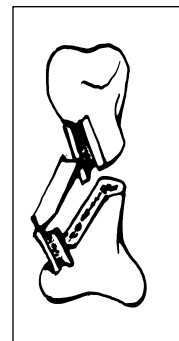
**B2**



**2. Bending (77-B2.2)**



**3. Comminuted (77-B2.3)**

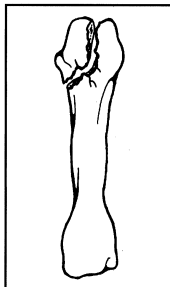


Metacarpal, distal partial articular (77-B3)

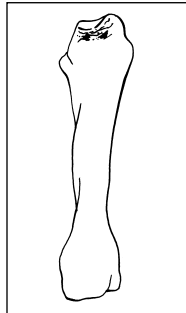
**1. Avulsion OR Split (77-B3.1)**

- (1) unicondyle medial
- (2) unicondyle lateral
- (3) coronal split volar fragment
- (4) coronal split dorsal fragment

**B3**

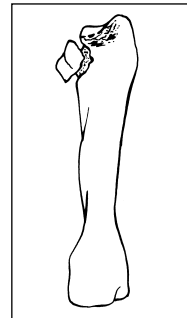


**2. Depression (77-B3.2)**



**3. Split/depression (77-B3.3)**

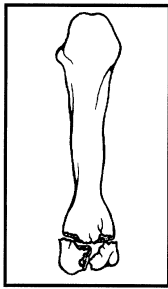
- (1) unicondyle medial
- (2) unicondyle lateral
- (3) coronal split volar fragment
- (4) coronal split dorsal fragment



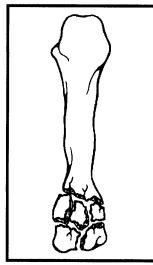
Metacarpal, proximal articular (77-C1)

1. Noncomminuted articular and metaphysis (77-C1.1)

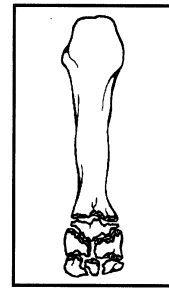
**C1**



2. Noncomminuted articular, comminuted metaphysis (77-C1.2)



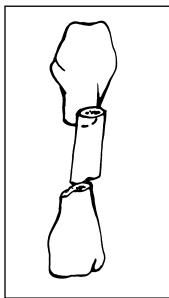
3. Comminuted articular (77-C1.3)



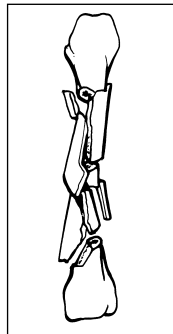
Metacarpal, diaphysis comminuted (77-C2)

1. Segmental (77-C2.1)

**C2**



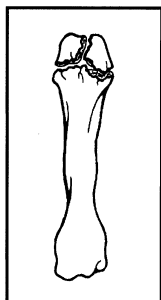
2. Complex comminuted (77-C2.2)



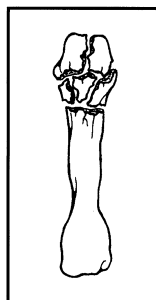
Metacarpal, distal articular (77-C3)

1. Simple articular/metaphysis (77-C3.1)

**C3**



2. Simple articular/comminuted metaphysis (77-C3.2)



3. Comminuted articular (77-C3.3)

