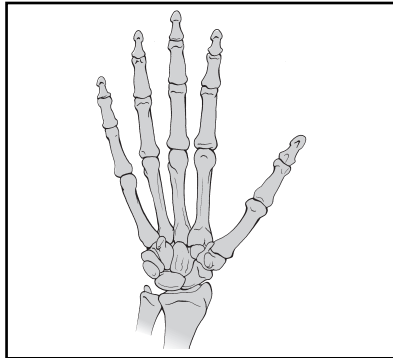
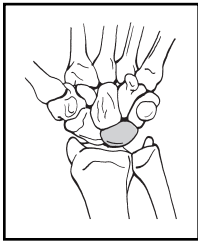


HAND AND CARPUS

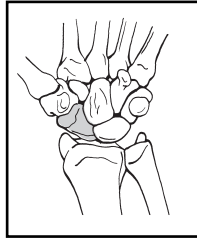
AREA: HAND AND CARPUS (71-79)



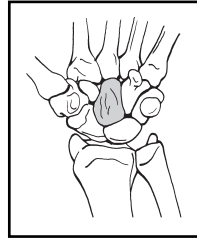
Bones:
Lunate (71)



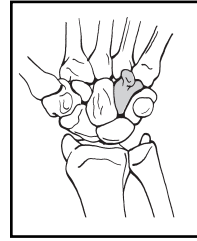
Scaphoid (72)



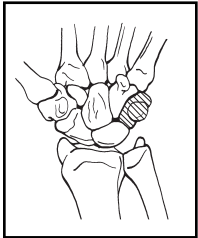
Capitate (73)



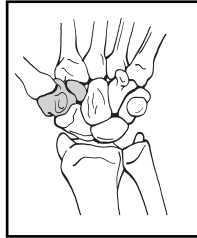
Hamate (74)



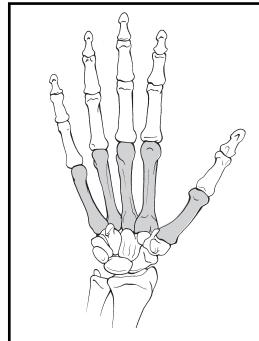
Ulnar carpal bones (75)



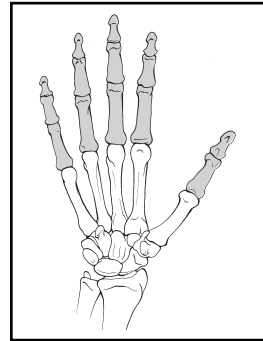
Radial carpal bones (76)



Metacarpals (77)



Phalanges (78)



Multiple hand and carpal fractures (79)

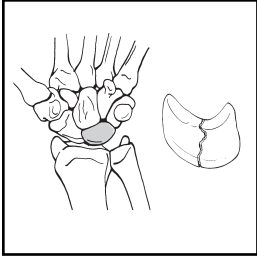
- A. Carpal (79-A)
- B. Metacarpal (79-B)
- C. Phalanges (79-C)

Location: Carpus (71-76)

Types:

- A. Noncomminuted
- B. Comminuted

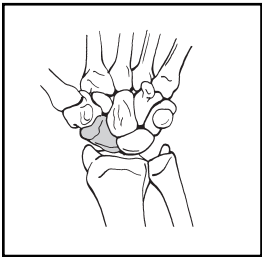
Lunate (71)



A. Noncomminuted (71-A)

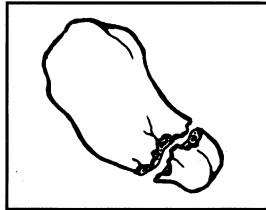
B. Comminuted (71-B)

Scaphoid (72)



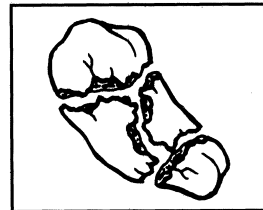
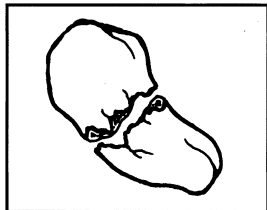
A. Noncomminuted (72-A)
1. Proximal Pole (72-A1)

B. Comminuted (72-B)
1. Proximal Pole (72-B1)



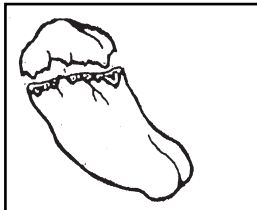2. Waist (72-A2)

2. Waist (72-B2)

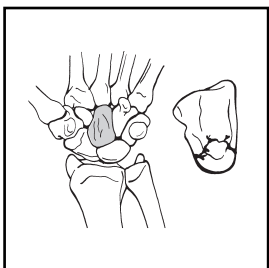


3. Distal pole (72-A3)

3. Distal Pole (72-B3)



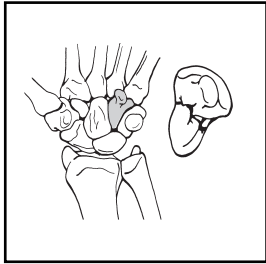
Capitate (73)



A. Noncomminuted (73-A)

B. Comminuted (73-B)

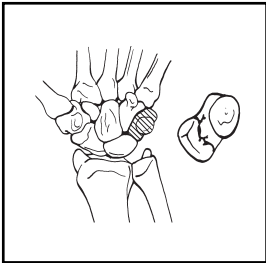
Hamate (74)



A. Noncomminuted (74-A)

B. Comminuted (74-B)

Ulnar carpal bones (75)



A. Noncomminuted (75-A)

B. Comminuted (75-B)

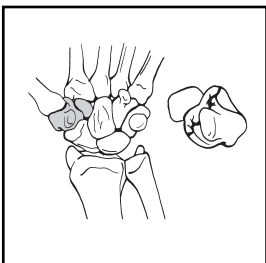
1. Pisiform (75-A1)

1. Pisiform (75-B1)

2. Triquetrum (75-A2)

2. Triquetrum (75-B2)

Radial carpal bones (76)



A. Noncomminuted (76-A)

B. Comminuted (76-B)

1. Trapezium (76-A1)

1. Trapezium (76-B1)

2. Trapezoid (76-A2)

2. Trapezoid (76-B2)