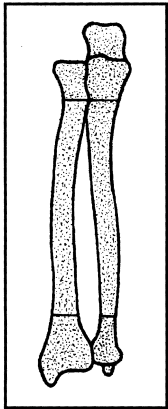
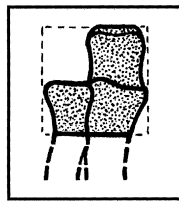


# RADIUS/ULNA

**BONE: RADIUS/ULNA (2)**

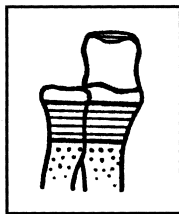


**Location: Proximal segment (21)**

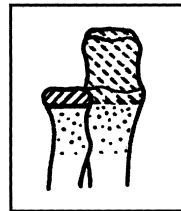


**Types:**

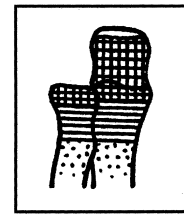
**A. Extra-articular (21-A)**



**B. Articular fracture involving articular surface of only 1 of the 2 bones (21-B)**



**C. Articular fracture involving articular surface of 2 bones (21-C)**



**Groups:**

Radius/ulna, proximal, extra-articular (21-A)

Radius/ulna, proximal, articular surface one bone (21-B)

Radius/ulna, proximal, articular both bones (21-C)

**1. Ulna only (21-A1)**

**2. Radius only (21-A2)**

**3. Radius and ulna (21-A3)**

**1. Ulna fractured, 2. Radius fractured, radius intact (21-B1)**

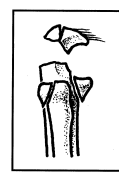
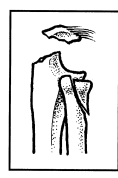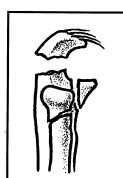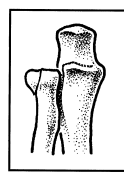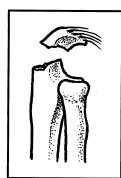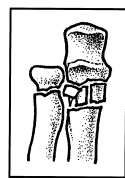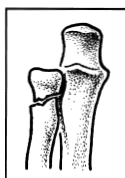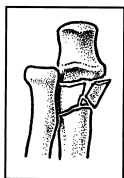
**2. Simple of 1 bone, extra-articular of other (21-B3)**

**3. Simple of 1, multifragmentary of other (21-C2)**

**1. Simple of both bones (21-C1)**

**2. Multifragmentary of both (21-C3)**

**3. Multifragmentary of both (21-C3)**

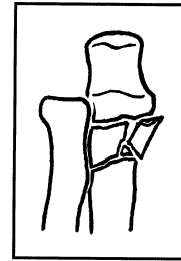
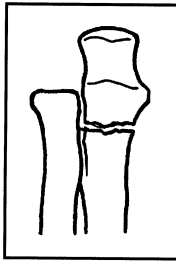
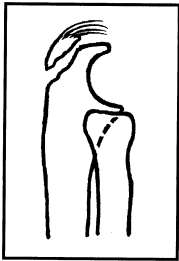


**Subgroups and Qualifications:**

Radius/ulna, proximal, extra-articular ulna fractured (21-A1)

- 1. Avulsion of triceps insertion from olecranon (21-A1.1)
- 2. Metaphyseal simple (21-A1.2)
- 3. Metaphyseal multifragmentary (21-A1.3)

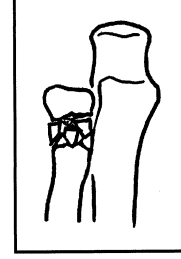
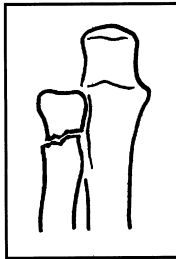
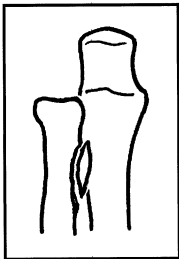
**A1**



Radius/ulna, proximal, extra-articular radius fractured (21-A2)

- 1. Avulsion of bicipital tuberosity of radius (21-A2.1)
- 2. Neck simple (21-A2.2)
- 3. Neck multifragmentary (21-A2.3)

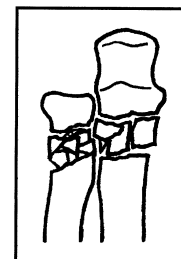
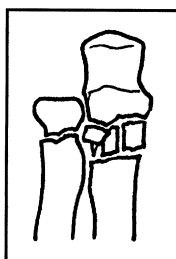
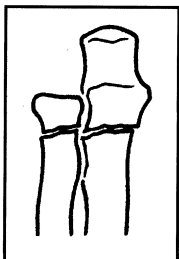
**A2**



Radius/ulna, proximal, extra-articular, fracture both bones (21-A3)

- 1. Simple of both bones (21-A3.1)
- 2. Multifragmentary of 1 bone and simple of other (21-A3.2)  
(1) multifragmentary ulna  
(2) multifragmentary radius
- 3. Multifragmentary of both bones (21-A3.3)

**A3**



Radius/ulna, proximal, articular fracture ulna (21-B1)

**1. Unifocal (21-B1.1)**

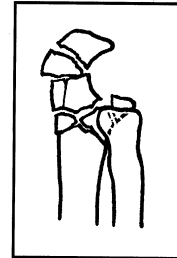
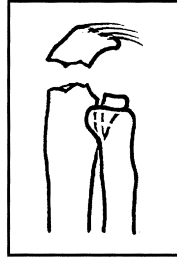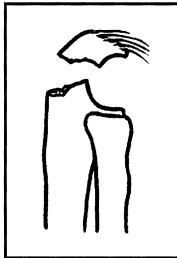
- (1) olecranon 1 line
- (2) olecranon 2 lines
- (3) olecranon multifragmentary
- (4) coronoid process alone

**2. Bifocal (21-B1.2)**

**3. Bifocal multifragmentary (21-B1.3)**

- (1) multifragmentary olecranon
- (2) multifragmentary coronoid process
- (3) multifragmentary of both

**B1**



Radius/ulna, proximal, articular, radial fracture (21-B2)

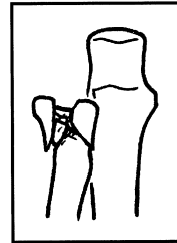
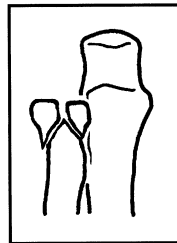
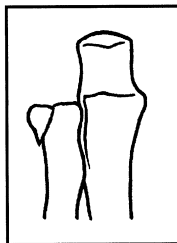
**1. Simple (21-B2.1)**

- (1) nondisplaced
- (2) displaced

**2. Multifragmentary without depression (21-B2.2)**

**3. Multifragmentary with depression (21-B2.3)**

**B2**



Radius/ulna, proximal, articular of 1, extra-articular of other (21-B3)

**1. Ulna articular simple (21-B3.1)**

- (1) radius extra-articular simple
- (2) radius extra-articular multifragmentary

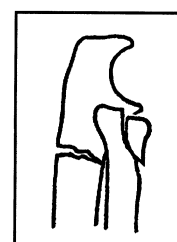
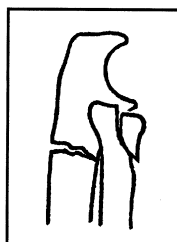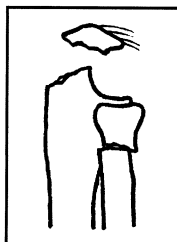
**2. Radius articular simple (21-B3.2)**

- (1) ulna extra-articular simple
- (2) ulna extra-articular multifragmentary

**3. Articular multifragmentary (21-B3.3)**

- (1) ulna, radius extra-articular simple
- (2) ulna, radius extra-articular multifragmentary
- (3) radius, ulna extra-articular simple
- (4) radius, ulna extra-articular multifragmentary

**B3**

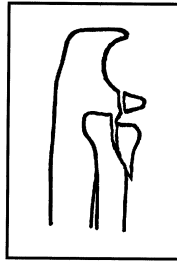


Radius/ulna, proximal, articular both simple (21-C1)

1. Olecranon and radial head (21-C1.1)

2. Coronoid process and radial head (21-C1.2)

**C1**



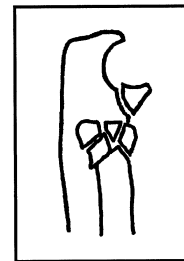
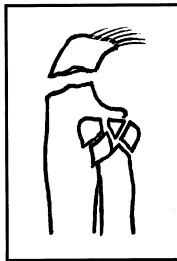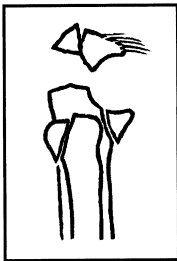
Radius/ulna, proximal, articular, both bones, 1 simple the other multifragmentary (21-C2)

1. Olecranon multifragmentary, radial head, simple (21-C2.1)

2. Olecranon simple, radial head multifragmentary (21-C2.2)

3. Coronoid process simple, radial head multifragmentary (21-C2.3)

**C2**



Radius/ulna, proximal, articular multifragmentary both bones (21-C3)

1. 3 fragments both bones (21-C3.1)

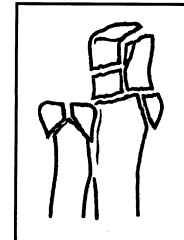
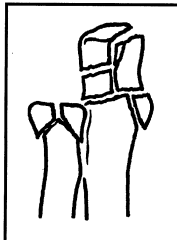
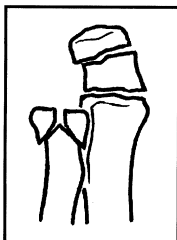
2. Ulna, more than 3 fragments (21-C3.2)

3. Radius, more than 3 fragments (21-C3.3)

(1) radius, 3 fragments  
(2) radius, more than 3 fragments

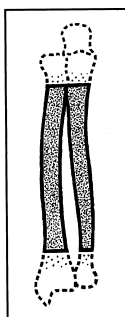
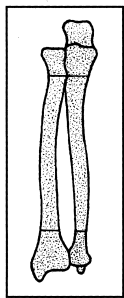
(1) ulna, 3 fragments  
(2) ulna, epiphysio-diaphyseal

**C3**

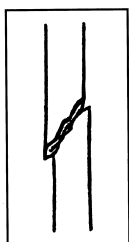


**BONE: RADIUS/ULNA (2)**

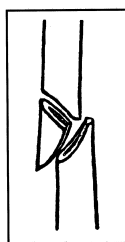**Location: Diaphyseal (22)**



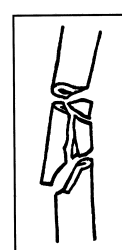**Types:**  
**A. Simple (22-A)**



**B. Wedge (22-B)**



**C. Complex (22-C)**



**Groups:**

Radius/ulna, diaphyseal, simple (22-A)

1. Ulna simple, radius intact (22-A1)

2. Radius simple, ulna intact (22-A2)

3. Simple fracture both bones (22-A3)

Radius/ulna, diaphyseal, wedge fracture (22-B)

1. Ulna fracture, radius intact (22-B1)

2. Radius fracture, ulna intact (22-B2)

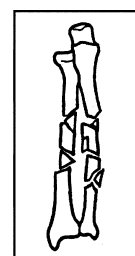
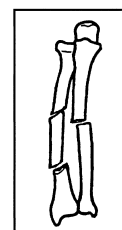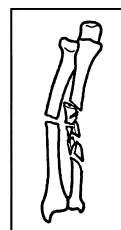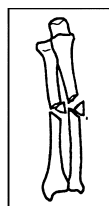
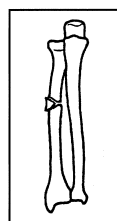
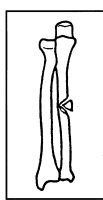
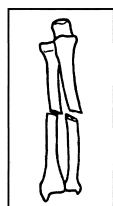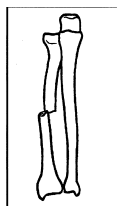
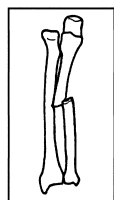
3. Wedge fracture, simple or wedge of other bone (22-B3)

Radius/ulna, diaphyseal, complex (22-C)

1. Complex of ulna (22-C1)

2. Complex of radius (22-C2)

3. Complex of both bones (22-C3)



**Subgroups and Qualifications:**

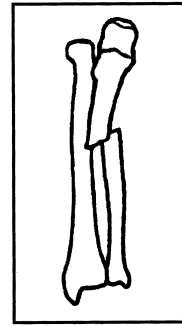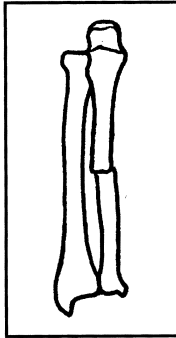

Radius/ulna, diaphyseal, simple fracture of ulna (22-A1)

1. Oblique (22-A1.1)

2. Transverse (22-A1.2)

3. With dislocation of radial head (Monteggia) (22-A1.3)

**A1**



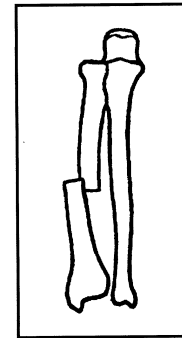
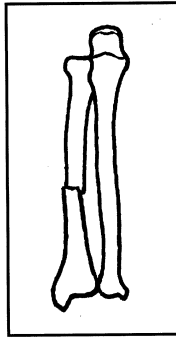
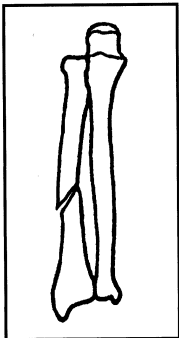
Radius/ulna, diaphyseal, simple fracture of radius (22-A2)

1. Oblique (22-A2.1)

2. Transverse (22-A2.2)

3. With dislocation of distal radio-ulnar joint (Galeazzi) (22-A2.3)

**A2**



Radius/ulna, diaphyseal, simple fracture of both bones (22-A3)

(1) without dislocation

(2) with dislocation of radial head (Monteggia)

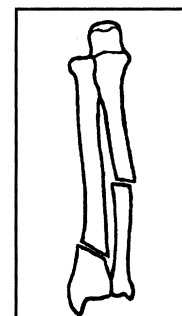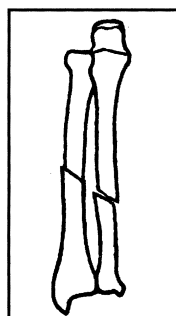
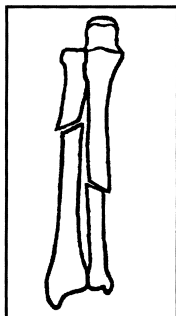
(3) with dislocation of distal radioulnar joint (Galeazzi)  
(based on level of radial fracture)

1. Radius, proximal zone (22-A3.1)

2. Radius, middle zone (22-A3.2)

3. Radius, distal zone (22-A3.3)

**A3**



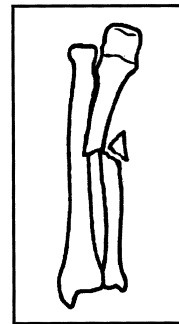
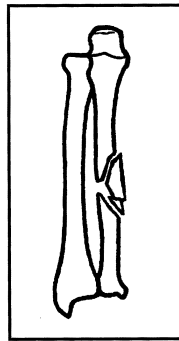
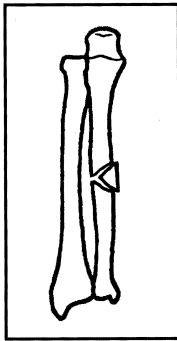
Radius/ulna, diaphyseal, wedge fracture of ulna (22-B1)

1. Intact wedge (22-B1.1)

2. Fragmented wedge (22-B1.2)

3. With dislocation of radial head (Monteggia) (22-B1.3)

**B1**



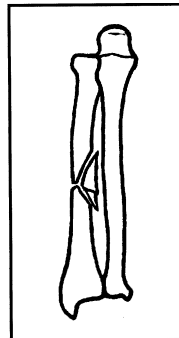
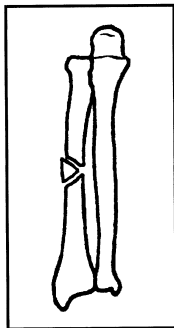
Radius/ulna, diaphyseal, wedge fracture of radius (22-B2)

1. Intact wedge (22-B2.1)

2. Fragmented wedge (22-B2.2)

3. With dislocation of distal radio-ulnar joint (Galeazzi) (22-B2.3)

**B2**



Radius/ulna, diaphyseal, wedge of 1, simple or wedge of other (22-B3)

(1) without dislocation

(2) with dislocation of radial head (Monteggia)

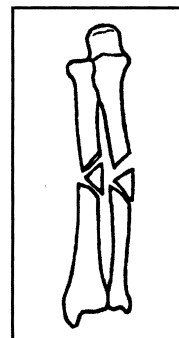
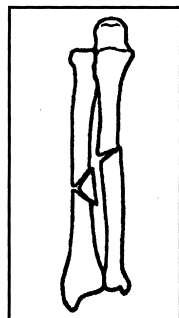
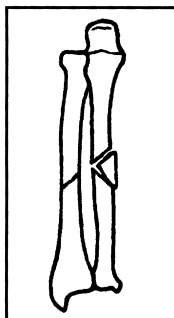
(3) with dislocation of distal radioulnar joint (Galeazzi)

1. Ulna wedge, simple fracture radius (22-B3.1)

2. Radial wedge, simple fracture of ulna (22-B3.2)

3. Radial and ulnar wedge (22-B3.3)

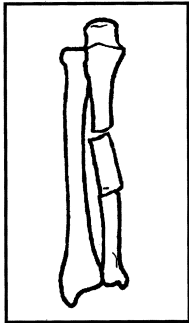
**B3**



Radius/ulna, diaphyseal, complex fracture of ulna (22-C1)

**1. Bifocal, radius intact (22-C1.1)**

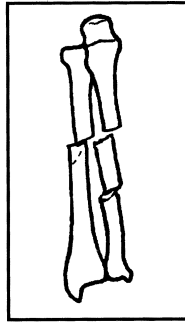
- (1) without dislocation
- (2) with radial head dislocated (Monteggia)



**C1**

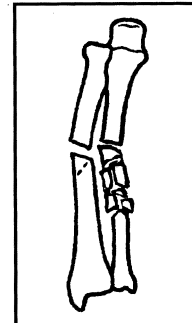
**2. Bifocal with radial fracture (22-C1.2)**

- (1) radius simple
- (2) radius wedge



**3. Irregular of ulna (22-C1.3)**

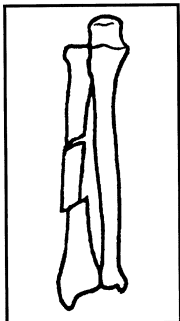
- (1) radius intact
- (2) radius simple
- (3) radius wedge



Radius/ulna, diaphyseal, complex fracture of radius (22-C2)

**1. Bifocal, ulna intact (22-C2.1)**

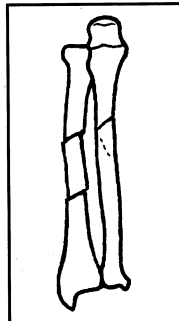
- (1) without dislocation
- (2) with dislocation of distal radioulnar joint (Galeazzi)



**C2**

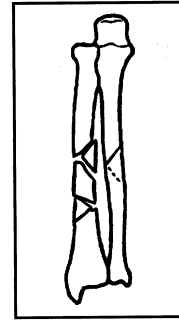
**2. Bifocal, ulna fracture (22-C2.2)**

- (1) simple ulna
- (2) wedge ulna



**3. Irregular (22-C2.3)**

- (1) ulna intact
- (2) ulna simple
- (3) ulna wedge



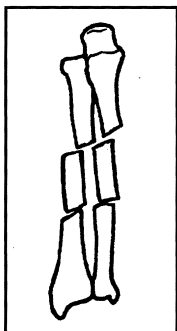
Radius/ulna, diaphyseal, complex of both bones (22-C3)

**1. Bifocal (22-C3.1)**

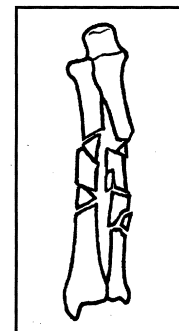
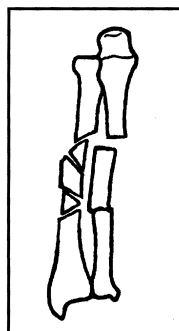
**2. Bifocal of 1, irregular of other (22-C3.2)**

- (1) bifocal radius, irregular ulna
- (2) bifocal ulna, irregular radius

**3. Irregular (22-C3.3)**



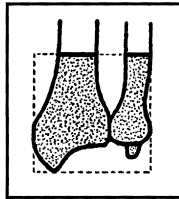
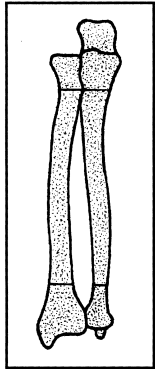
**C3**





**BONE: RADIUS/ULNA (2)**

**Location: Distal segment (23)**

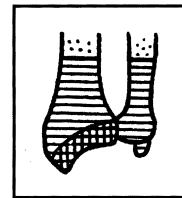
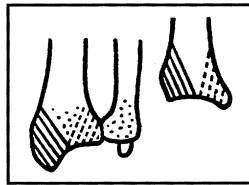
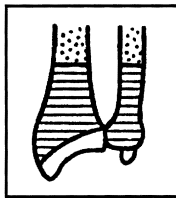


**Types:**

**A. Extra-articular (23-A)**

**B. Partial articular fracture of radius (23-B)**

**C. Complete articular fracture of radius (23-C)**



**Groups:**

Radius/ulna, distal, extra-articular (23-A)

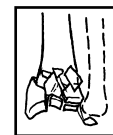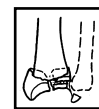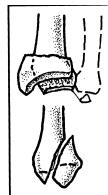
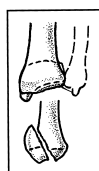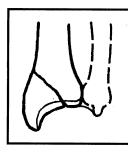
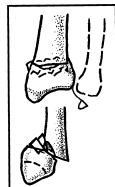
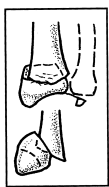
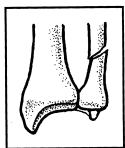
Radius/ulna, distal, partial articular radius (23-B)

Radius/ulna, distal, complete articular (23-C)

- 1. Extra-articular radius fracture, radius intact (23-A1)
- 2. Extra-articular simple radius fracture, ulna intact (23-A2)
- 3. Extra-articular, multifragmentary radius fracture (23-A3)

- 1. Partial articular radius, sagittal (23-B1)
- 2. Partial articular radius, dorsal rim (Barton) (23-B2)
- 3. Partial articular radius, volar rim (reverse Barton, Goyrand Smith II) (23-B3)

- 1. Complete articular radius, simple articular and metaphysis (23-C1)
- 2. Complete articular radius, simple articular, metaphyseal multifragmentary (23-C2)
- 3. Complete articular radius, multifragmentary (23-C3)



**Subgroups and Qualifications:**

Radius/ulna, distal, extra-articular fracture of ulna (23-A1)

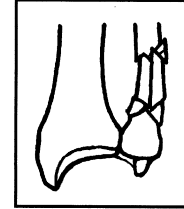
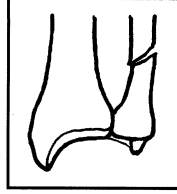
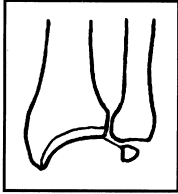
**1. Ulna styloid process (23-A1.1)**

**2. Metaphyseal simple (23-A1.2)**

**3. Metaphyseal multifragmentary (23-A1.3)**

- (1) wedge
- (2) complex

**A1**



Radius/ulna, distal, extra-articular fracture of radius, simple metaphyseal and impacted (23-A2)

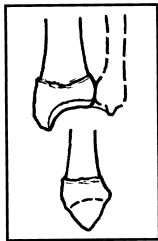
- (1) radioulnar dislocation (fracture of styloid process)
- (2) simple fracture of ulnar neck
- (3) multifragmentary fracture of ulnar neck
- (4) fracture of ulna head
- (5) fracture of ulna head and neck
- (6) fracture proximal to ulnar neck

**1. Transverse, no tilt, but may be axially shortened (23-A2.1)**

**2. With dorsal tilt, oblique fracture upward and back (Pouteau-Colles) (23-A2.2)**

**3. Volar tilt, oblique upwards and forward (Goyrand-Smith) (23-A2.3)**

**A2**



Radius/ulna, distal, extra-articular fracture of radius, multifragmentary (23-A3)

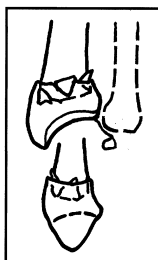- (1) radioulnar dislocation (fracture of styloid process)
- (2) simple fracture of ulnar neck
- (3) multifragmentary fracture of ulnar neck
- (4) fracture of ulna head
- (5) fracture of ulna head and neck
- (6) fracture proximal to ulnar neck

**1. Impacted with axial shortening (23-A3.1)**

**2. With a wedge (23-A3.2)**

**3. Complex (23-A3.3)**

**A3**

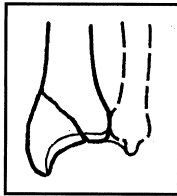


Radius/ulna, distal, partial articular fracture of radius, sagittal (23-B1)

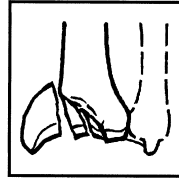
- (1) radioulnar dislocation (fracture of styloid process)
- (2) simple fracture of ulnar neck
- (3) multifragmentary fracture of ulnar neck
- (4) fracture of ulna head
- (5) fracture of ulna head and neck
- (6) fracture proximal to ulnar neck

1. Lateral simple (23-B1.1)

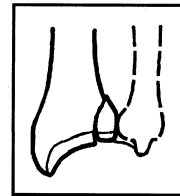
**B1**



2. Lateral multifragmentary (23-B1.2)



3. Medial (23-B1.3)



Radius/ulna, distal, partial articular fracture of radius, dorsal rim (Barton's) (23-B2)

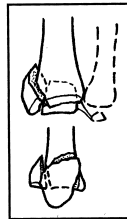
- (1) radioulnar dislocation (fracture of styloid process)
- (2) simple fracture of ulnar neck
- (3) multifragmentary fracture of ulnar neck
- (4) fracture of ulna head
- (5) fracture of ulna head and neck
- (6) fracture proximal to ulnar neck

1. Simple (23-B2.1)


**B2**



2. With lateral sagittal fracture (23-B2.2)



3. With dorsal dislocation of carpus (23-B2.3)



Radius/ulna, distal, partial articular fracture of radius, volar rim (reverse Barton's, Goyrand-Smith II) (23-B3)

- (1) radioulnar dislocation (fracture of styloid process)
- (2) simple fracture of ulnar neck
- (3) multifragmentary fracture of ulnar neck
- (4) fracture of ulna head
- (5) fracture of ulna head and neck
- (6) fracture proximal to ulnar neck

1. Simple with small fragment (23-B3.1)

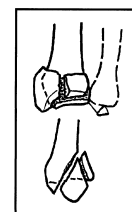**B3**



2. Simple with larger fragment (23-B3.2)



3. Multifragmentary (23-B3.3)

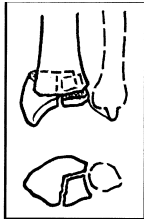


Radius/ulna, distal, complete articular fracture of radius, articular simple, metaphyseal simple (23-C1)

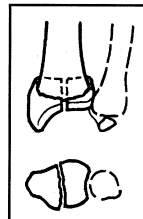
- (1) radioulnar dislocation (fracture of styloid process)
- (2) simple fracture of ulnar neck
- (3) multifragmentary fracture of ulnar neck
- (4) fracture of ulna head
- (5) fracture of ulna head and neck
- (6) fracture proximal to ulnar neck

1. **Posteromedial articular fragment**  
(23-C1.1)

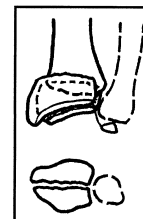
**C1**



2. **Sagittal articular fracture line**  
(23-C1.2)



3. **Frontal articular fracture line**  
(23-C1.3)

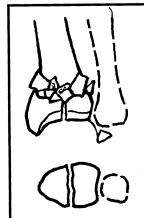

Radius/ulna, distal, complete articular fracture of radius, articular simple, metaphyseal multifragmentary (23-C2)

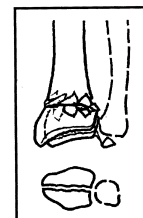- (1) radioulnar dislocation (fracture of styloid process)
- (2) simple fracture of ulnar neck
- (3) multifragmentary fracture of ulnar neck
- (4) fracture of ulna head
- (5) fracture of ulna head and neck
- (6) fracture proximal to ulnar neck

1. **Sagittal articular fracture line**  
(23-C2.1)

**C2**



2. **Frontal articular fracture line**  
(23-C2.2)



3. **Extending into diaphysis** (23-C2.3)

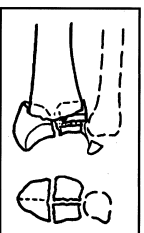


Radius/ulna, distal, complete articular fracture of radius, multifragmentary (23-C3)

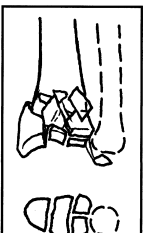- (1) radioulnar dislocation (fracture of styloid process)
- (2) simple fracture of ulnar neck
- (3) multifragmentary fracture of ulnar neck
- (4) fracture of ulna head
- (5) fracture of ulna head and neck
- (6) fracture proximal to ulnar neck

1. **Metaphyseal simple** (23-C3.1)

**C3**



2. **Metaphyseal multifragmentary**  
(23-C3.2)



3. **Extending into diaphysis** (23-C3.3)

